

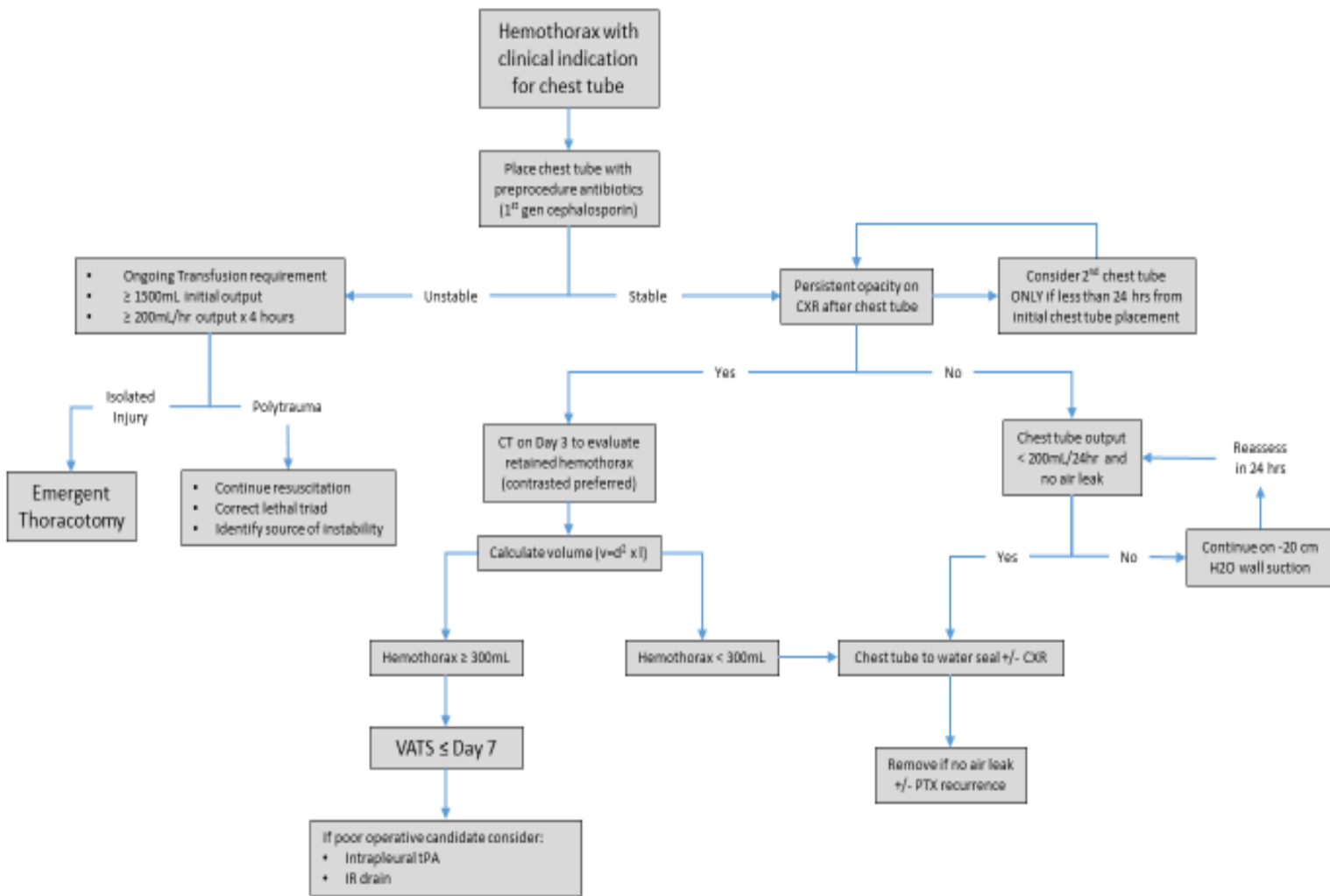
# Hemothorax guidelines

1. Place chest tube if HTX present per chest tube protocol (1)
  - a. Large bore chest tube (28-40F) (2)
  - b. One dose of antibiotics starting just prior to placement (3, 4)
    - i. 1<sup>st</sup> generation cephalosporin
2. Order post-procedure CXR
3. If radiographic evidence of retained HTX
  - a. **If within 24 hours**, consider placing 2<sup>nd</sup> chest tube
  - b. Order a **contrasted chest CT on day 3** if HTX is still present on CXR (5)
    - i. If  $\geq 300\text{mL}$  HTX (formula  $v=d^2 \times l$ )<sup>1</sup> present on CT (6, 7)
      1. VATS on or before day 7 (1, 5-11)
      2. Consider intrapleural tPA (9, 12-14) if poor operative candidate or other indications (tPA is contraindicated in any patient with intrathoracic arterial bleeding/injury including pulmonary laceration and/or intercostal bleeding). Administration of TPA is not intended to prevent VATS in operative candidates.<sup>2</sup>
        - a. 24mg tPA in 48mL NS (tPA concentration 0.5mg/mL) injected in chest tube daily x 3 days (15-18) using sterile technique
        - b. Clamp chest tube x 1 hour (16)
        - c. Roll patient to ensure distribution throughout chest
        - d. Unclamp tube and allow drainage
    - ii. If  $< 300\text{mL}$  HTX present, no additional intervention needed (1, 6)
4. If no radiographic evidence of retained HTX
  - a. Place tube to water seal if no evidence of PTX on morning CXR and no air leak in tube
  - b. Remove chest tube when output  $< 200\text{mL}/24\text{hr}$  (19)

---

<sup>1</sup> **d** = greatest depth of hemothorax on a single CT image, **l** = greatest length of the hemothorax.

<sup>2</sup> To find the Trauma Retained Hemothorax order set in Estar you must type "hemothorax" in the order section, order set will then populate for you. It will not come up if you type tPA or Alteplase.



## References

1. Mowery NT, Gunter OL, Collier BR, et al. Practice management guidelines for management of hemothorax and occult pneumothorax. *J Trauma* 2011;70:510-518.
2. Inaba K, Lustenberger T, Recinos G, et al. Does size matter? A prospective analysis of 28-32 versus 36-40 French chest tube size in trauma. *J Trauma* 2012;72:422-427.
3. Luchette FA, Barrie PS, Oswanski MF, et al. Practice Management Guidelines for Prophylactic Antibiotic Use in Tube Thoracostomy for Traumatic Hemopneumothorax: the EAST Practice Management Guidelines Work Group. Eastern Association for Trauma. *J Trauma* 2000;48:753-757.
4. Maxwell RA, Campbell DJ, Fabian TC, et al. Use of presumptive antibiotics following tube thoracostomy for traumatic hemopneumothorax in the prevention of empyema and pneumonia--a multi-center trial. *J Trauma* 2004;57:742-748; discussion 748-749.
5. Velmahos GC, Demetriades D, Chan L, et al. Predicting the need for thoracoscopic evacuation of residual traumatic hemothorax: chest radiograph is insufficient. *J Trauma* 1999;46:65-70.
6. Dubose J, Inaba K, Demetriades D, et al. Management of post-traumatic retained hemothorax: A prospective, observational, multicenter AAST study. *J Trauma* 2012;72:11-24.
7. Mergo PJ, Helmberger T, Didovic J, et al. New formula for quantification of pleural effusions from computed tomography. *J Thorac Imaging* 1999;14:122-125.
8. Oguzkaya F, Akcali Y, Bilgin M. Videothoracoscopy versus intrapleural streptokinase for management of post traumatic retained haemothorax: a retrospective study of 65 cases. *Injury* 2005;36:526-529.
9. Boersma WG, Stigt JA, Smit HJ. Treatment of haemothorax. *Respir Med* 2010;104:1583-1587.
10. Heniford BT, Carrillo EH, Spain DA, et al. The role of thoracoscopy in the management of retained thoracic collections after trauma. *Ann Thorac Surg* 1997;63:940-943.
11. Meyer DM, Jessen ME, Wait MA, et al. Early evacuation of traumatic retained hemothoraces using thoracoscopy: a prospective, randomized trial. *Ann Thorac Surg* 1997;64:1396-1400; discussion 1400-1391.
12. Agarwal R, Aggarwal AN, Gupta D. Intrapleural fibrinolysis in clotted haemothorax. *Singapore Med J* 2006;47:984-986.
13. Inci I, Ozcelik C, Ulku R, et al. Intrapleural fibrinolytic treatment of traumatic clotted hemothorax. *Chest* 1998;114:160-165.
14. Tissue Plasminogen Activator in Traumatic Hemothorax. Available at: [http://www.surgicalcriticalcare.net/Guidelines/tissue\\_plasminogen\\_activator.pdf](http://www.surgicalcriticalcare.net/Guidelines/tissue_plasminogen_activator.pdf).
15. Skeete DA, Rutherford EJ, Schlidt SA, et al. Intrapleural tissue plasminogen activator for complicated pleural effusions. *J Trauma* 2004;57:1178-1183.
16. Thommi G, Nair CK, Aronow WS, et al. Efficacy and safety of intrapleural instillation of alteplase in the management of complicated pleural effusion or empyema. *Am J Ther* 2007;14:341-345.
17. Hamblin SE, Furmanek DL. Intrapleural tissue plasminogen activator for the treatment of parapneumonic effusion. *Pharmacotherapy* 2010;30:855-862.
18. Ben-Or S, Feins RH, Veeramachaneni NK, et al. Effectiveness and risks associated with intrapleural alteplase by means of tube thoracostomy. *Ann Thorac Surg* 2011;91:860-863; discussion 863-864.
19. Younes RN, Gross JL, Aguiar S, et al. When to remove a chest tube? A randomized study with subsequent prospective consecutive validation. *J Am Coll Surg* 2002;195:658-662.
20. Sharon Ben-Or, MD, Richard H. Feins, MD, Nirmal K. Veeramachaneni, et al. Effectiveness and risks associated with intrapleural alteplase by means of tube thoracostomy. *The Society of Thoracic Surgeons*. 2011;91:860-864.
21. Stiles, P.J. MD, Drake, Rachel M.Ed., Helmer, Stephen D. PhD. Evaluation of chest tube administration of tissue plasminogen activator to treat retained hemothorax. *The American Journal Of Surgery* 2014; 207: 960-963

July, 2018

Bradley M. Dennis, MD, Susan Hamblin PharmD, Bethany Evans, ACNP-BC