

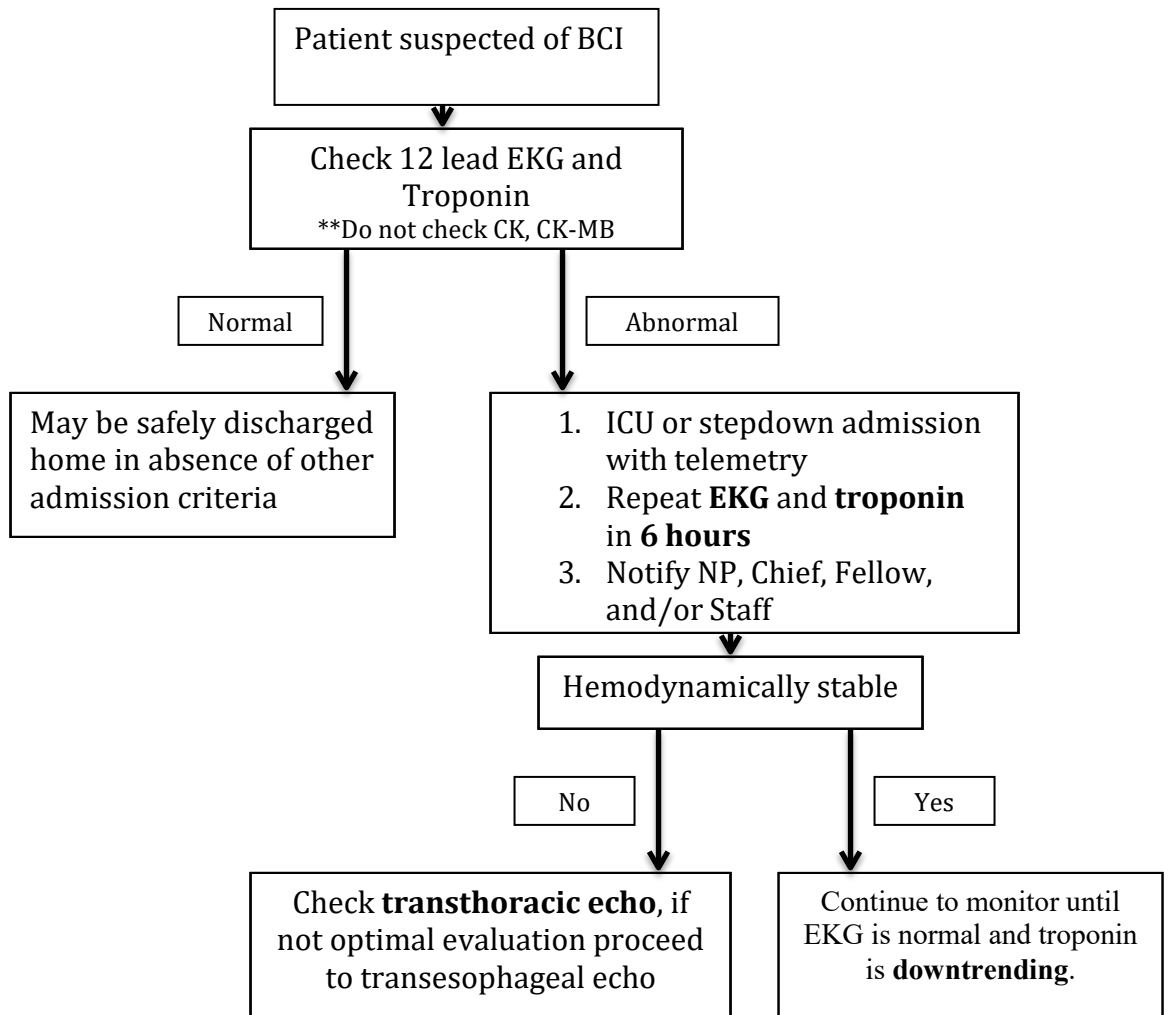
**Blunt Cardiac Injury (BCI) Practice Management Guideline**

Patients at high risk for BCI:

1. Blunt chest trauma AND at least one of the following:
  - a. Complaints of chest pain
  - b. Hemodynamically unstable patients unresponsive to resuscitation
  - c. Arrhythmia other than sinustachycardia

Patients not requiring screening:

1. Sternal fractures without the above



## \*\*Special Consideration in BCI

### Underlying cardiac disease

1. In patients with known underlying coronary artery disease and BCI, use of CT or MRI coronary angiography may be able to distinguish between structural injury and acute myocardial infarction

### Use of Swan Ganz Catheters

1. In setting of unclear etiology of post-traumatic hypotension, use of pulmonary artery catheters may provide useful information, and is considered safe in BCI.

### Operative Intervention

1. Elderly patients with BCI are safe to proceed with surgery with appropriate monitoring
2. Patients with new arrhythmia are safe to proceed to the operative theater

Sources:

---

1. Biffi WL, Moore FA, Moore EE, et al. Cardiac enzymes are irrelevant in the patient with suspected myocardial contusion. *Am J Surg.* 1993;168(6):523–7. discussion 527-8
2. Swaanenburg J, Klaase J, DeJongste M, et al. Troponin I, troponin T, CKMB-activity and CKMB- mass as markers for detection of myocardial contusion in patients who experienced blunt trauma. *Clin Chim Acta.* 1998;272:171–81.
3. Bertinchant JP, Polge A, Mohty D, et al. Evaluation of incidence, clinical significance, and prognostic value of circulating cardiac troponin I and T elevation in hemodynamically stable patients with suspected myocardial contusions after blunt chest trauma. *J Trauma.* 2000;48(5):924–31.
4. Sheikh M, Ben-Nakhi A, Shukkur AM, et al. Accuracy of 64-multidetector- row computed tomography in the diagnosis of coronary artery disease. *Med Princ Pract.* 2009;18:323Y328.
5. Rajan G, Zellweger R. Cardiac troponin I as a predictor of arrhythmia and ventricular dysfunction in trauma patients with myocardial contusion. *J Trauma.* 2004;57:801Y808
6. Odell DD, Peleg K, Givon A, Radomislensky I, Makey I, Decamp MM, Whyte R, Gangadharan SP, Berger RL; Israeli Trauma Group.. Sternal fracture: isolated lesion versus polytrauma from associated extrasternal injuries--analysis of 1,867 cases.*J Trauma Acute Care Surg.* 2013 Sep;75(3):448-52. doi: 10.1097/TA.0b013e31829e227e. PubMed PMID: 24089115
7. Velmahos GC, Karaiskakis M, Salim A, Toutouzas KG, Murray J, Asensio J, Demetriades D. Normal electrocardiography and serum troponin I levels preclude the presence of clinically significant blunt cardiac injury.*J Trauma.* 2003 Jan;54(1):45-50; discussion 50-1. PubMed PMID: 12544898.
8. García-Fernández MA, López-Pérez JM, Pérez-Castellano N, Quero LF, Virgós-Lamela A, Otero-Ferreiro A, Lasara AM, Vega M, Moreno M, Pastor-Benavent JA, Bermejo J, García-Pardo J, Gil de la Peña M, Navia J, Delcán JL. Role of transesophageal echocardiography in the assessment of patients with blunt chest trauma: correlation of echocardiographic findings with the electrocardiogram and creatine kinase monoclonal antibody measurements. *Am Heart J.* 1998 Mar;135(3):476-81. PubMed PMID: 9580094
9. Clancy K, Velopulos C, Bilaniuk JW, Collier B, Crowley W, Kurek S, Lui F, Nayduch D, Sangosanya A, Tucker B, Haut ER; Eastern Association for the Surgery of Trauma.. Screening for blunt cardiac injury: an Eastern Association for the Surgery of Trauma practice management guideline. *J Trauma Acute Care Surg.* 2012 Nov;73(5 Suppl 4):S301-6. doi: 10.1097/TA.0b013e318270193a. PubMed PMID: 23114485
10. Bellister S, Dennis B, Guillaumondegui O; Blunt and penetrating cardiac injury. *Surgical Clinics of North America, The,* 2017-10-01, Volume 97, Issue 5, Pages 1065-1076. PubMed PMID: 28958358