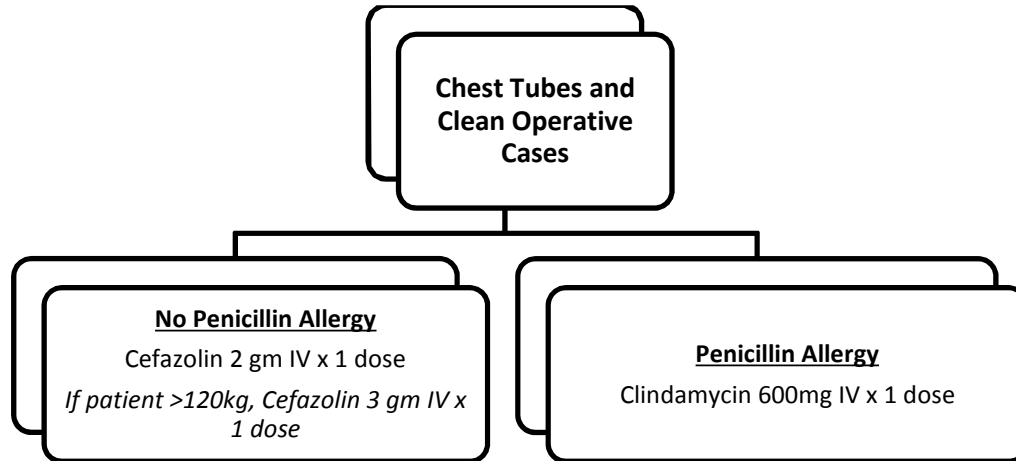
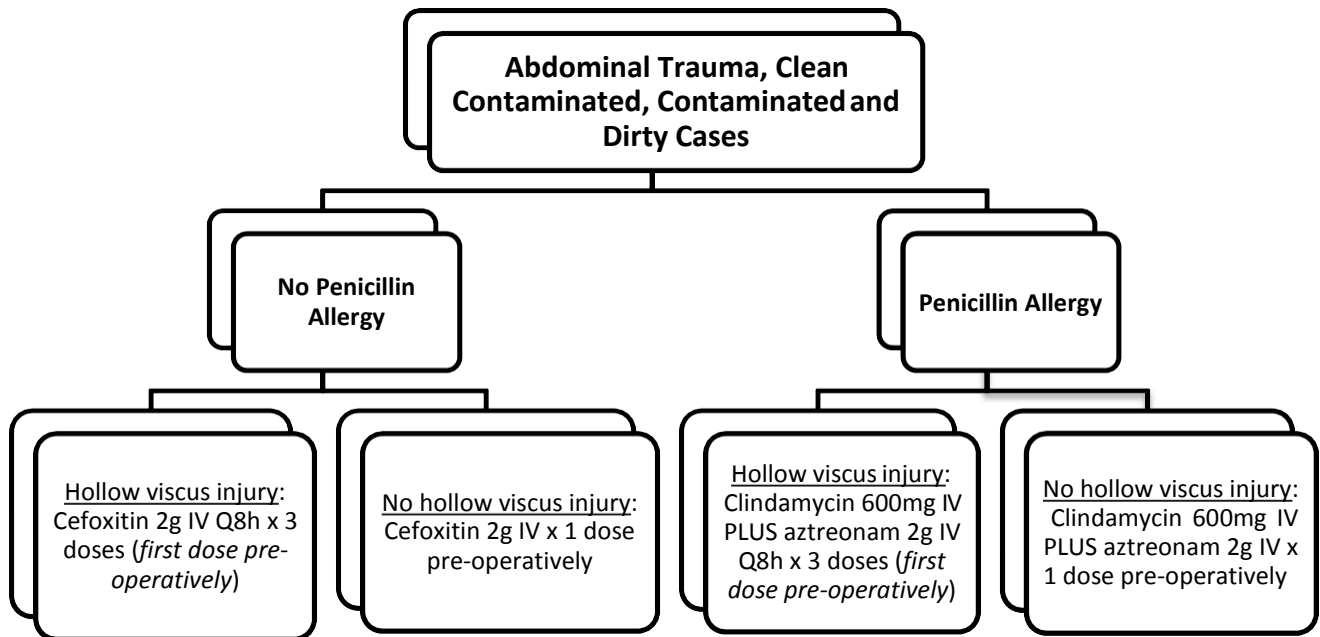


Perioperative Antibiotic Prophylaxis in Trauma



* For emergent chest tube placement or operative cases, the order should be entered as “stat”. However, for non-emergent chest tube placement or operative cases, the antibiotic should be ordered to be given 30 minutes prior to incision.



* Extended therapy is not needed with gross contamination or in cases of penetrating injuries to the thoracolumbar spine with associated intraperitoneal injuries.¹

* Patients receiving blood transfusions of 10 units or greater may require repeat antimicrobial dosing. Doses may be repeated approximately every 10 units of blood during massive transfusion.

RATIONALE

It is important to first determine whether to pursue prophylactic antibiotic coverage or treatment of active infection. If true infection is suspected, patients should be managed in accordance to the antimicrobial stewardship protocol and quarterly antibiotic rotation. If prophylactic coverage is desired, the above protocol should be followed.

There is some controversy surrounding the use of prophylactic antibiotics in patients receiving chest tubes, however, adequate data exist to support their use. A single dose of narrow, gram positive coverage is warranted.³⁻⁵

In patients without hollow viscus injury, a single, preoperative, prophylactic dose of antibiotic is adequate; in patients with hollow viscus injury, antibiotic administration should be initiated as soon as possible. Antibiotic therapy should be continued for **no longer than 24 hours**, as prophylaxis beyond 24 hours is not associated with a risk of surgical infections, but rather an increase in nosocomial infectious complications and resistant infections.^{2, 6-7}

The post-operative infection rate following surgery for abdominal trauma with hollow viscus injury is between 10 and 15%.⁸ Demonstrated risk factors for infection include hollow viscus injury, presence and degree of intestinal contamination, patient age, transfusion requirement, and shock. The microbiology and bacterial load differ throughout the gastrointestinal tract; the concentration of bacteria increases in proximal to distal direction.

Broad spectrum, prophylactic antibiotic coverage should be directed against gram positive, enteric gram-negative and anaerobic bacteria.⁹ Common pathogens include:

- Streptococcus
- Enterococcus
- Enterobacteriaceae
- Bacteroides
- Peptostreptococcus
- Clostridium

Many regimens have been proven to be efficacious in this setting. Second-generation cephalosporins and extended spectrum penicillins are as effective as regimens which include aminoglycosides and in addition, offer the convenience of single agent therapy. Aminoglycosides are no longer recommended due to suboptimal activity in this patient population. Agents whose spectra include coverage of enterococcus species may be more efficacious than those that do not.¹⁰

REFERENCES

1. Pasupuleti LV, Sifri ZC, Mohr AM. Is Extended Antibiotic Prophylaxis Necessary after Penetrating Trauma to the Thoracolumbar Spine with Concomitant Intraperitoneal Injuries? *Surg Infect (Larchmt)*. 2014;15(1):8-13.
2. Goldberg SR, Anand RJ, Como JJ et al. Prophylactic antibiotic use in penetrating abdominal trauma: An Eastern Association for the Surgery of Trauma practice management guideline. *J Trauma Acute Care Surg*. 2012; 75(5):321-325.
3. Moore FO, Duane TM, Hu CK et al. Presumptive antibiotic use in tube thoracostomy for traumatic hemothorax: An Eastern Association for the Surgery of Trauma practice management guideline. *J Trauma Acute Care Surg*. 2012;73(5):S341-S344.
4. Bosman A, de Jong MB, Debeij J et al. Systematic review and meta-analysis of antibiotic prophylaxis to prevent infections from chest drains in blunt and penetrating thoracic injuries. *Br J Surg* 2012;99:506-513.
5. Heydari MB et al. Use of prophylactic antibiotics following tube thoracostomy for blunt chest trauma in the prevention of empyema and pneumonia. *J Inj Violence Res* 2014;6(2):91-92.
6. Fabian TC, Croce MA, Payne LW et al. Duration of antibiotic therapy for penetrating abdominal trauma: a prospective trial. *Surgery* 1992; 112:788-794.
7. Velmahos GC, Toutouzas KG, Sarkisyan G et al. Severe trauma is not an excuse for prolonged antibiotic prophylaxis. *Arch Surg* 2002; 137:537-541.
8. Fabian TC. Infection in penetrating abdominal trauma: Risk factors and preventive antibiotics. *Am Surg*. 2002;68(1):29-35.
9. Fabian TC. Prevention of infections following penetrating abdominal trauma. *Am J Surg* 1993; 165:145-195.
10. Weigelt JA, Easley SM, Thal ER et al. Abdominal surgical wound infection is lowered with improved perioperative enterococcus and bacteroides therapy. *J Trauma* 1993; 34:579-584.