

EMERGENCY GENERAL SURGERY

Practice Management Guidelines: Necrotizing Soft Tissue Infection

I. **Background:** Necrotizing Soft Tissue Infection remains one of the common reasons for Emergency General Surgery consultation. It is a severe, rapidly progressing infection with increased morbidity and mortality. Early recognition, appropriate antibiotics, and surgical debridement is critical.

II. **Guideline:**

A. **Initial Evaluation**

a. **Labs**

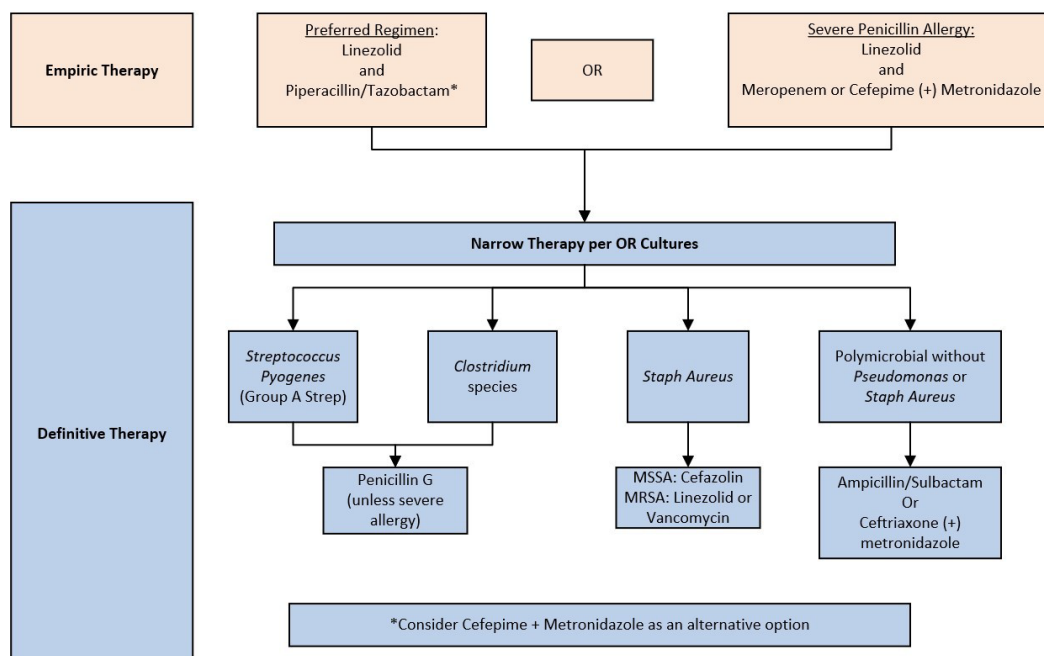
- i. CBC
- ii. BMP
- iii. Lactate
- iv. CRP
- v. Blood Cultures

b. **Imaging**

- i. Diagnosis is based on high clinical suspicion and confirmation in the operating room. CT with IV contrast can be performed in equivocal cases; soft tissue gas is specific for NSTI. However, the absence of soft tissue gas does not exclude the diagnosis of NSTI. Do not delay operative management for imaging if clinical suspicion is high.

c. **Initial Antibiotic Therapy**

- i. First Line: Linezolid, Piperacillin/Tazobactam
- ii. Severe PCN Allergy: Linezolid, Cefepime, Metronidazole



d. Consultations

- i. Trunk NSTI should prompt STAT consultation to the Emergency General Surgery Service
- ii. Additional Surgical Consultation as necessary
 - a. Urology for perineal/scrotal NSTI
 - b. Gynecology for vulvar NSTI
 - c. Orthopedics and/or Hand for extremity NSTI
 - d. Plastic Surgery once infection controlled and need for complex reconstruction
- iii. Surgical ICU consultation/admission postoperatively should be strongly considered

e. Surgical Management and Considerations

- i. Early aggressive debridement is critical (within 6 hours) **Level 2 to Operating Room**
- ii. Intraoperative specimen should be sent for gram stain and culture
- iii. Use skin-sparing approaches as much as possible with consideration of later reconstruction. Elevate full thickness and subcutaneous flaps to get access to necrotic tissue. Debride overlying skin **only** if necrotic (see Appendix).
- iv. Avoid incisions over bony prominences, vessels, and nerves.
- v. Plan to return to operating room within 24 hours for a second look. Return to the operating room more rapidly if there is clinical deterioration.
- vi. For cases involving the perineum and perianal area, consider diverting colostomy to reduce the risk of secondary wound contamination (once hemodynamically improved)
- vii. In large wounds, strongly consider the application of negative pressure wound therapy (wound VAC). In between wound VAC changes, cleanse wound thoroughly with dilute Dakin's solution (sodium hypochlorite 0.025%)
- viii. Once additional debridement is no longer necessary, and the patient is physiologically stable, wound coverage and closure should be considered. If possible, skin closure over the defects with interrupted sutures, split thickness skin grafts or flap coverage by Plastic Surgery should be performed.

f. Ongoing Management Considerations

- i. **Antibiotic Duration.** Systemic antibiotics in soft tissue infections should be continued until the following criteria are met:
 - a. Source control has been obtained (no further debridement planned)
 - b. Patient is hemodynamically normal
 - c. Fever has been absent for 48 hours
 - d. WBC cell count has improved
- ii. **Infectious Disease Consultation** The infectious disease service should be consulted for any of the following criteria:
 - a. Multidrug-resistant pathogens
 - b. Osteoarticular involvement (bone or exposed bone)
 - c. If consult required per VUMC policy (e.g. Staph aureus, enterococcus bacteremia)
- iii. **Early Physical and Occupational Therapy Consultations**

III. References

Stevens DL, Bryant AE. Necrotizing Soft-Tissue Infections. *N Engl J Med*. 2017 Dec 7;377(23):2253-2265. doi: 10.1056/NEJMra1600673. PMID: 29211672.

Stevens DL, Bisno AL, Chambers HF, Dellinger EP, Goldstein EJ, Gorbach SL, Hirschmann JV, Kaplan SL, Montoya JG, Wade JC. Practice guidelines for the diagnosis and management of skin and soft tissue infections: 2014 update by the infectious diseases society of America. *Clin Infect Dis*. 2014 Jul 15;59(2):147-59. doi: 10.1093/cid/ciu296. Epub 2014 Jun 18. PMID: 24947530.

Hua C, Urbina T, Bosc R, Parks T, Sriskandan S, de Prost N, Chosidow O. Necrotising soft-tissue infections. *Lancet Infect Dis*. 2023 Mar;23(3):e81-e94. doi: 10.1016/S1473-3099(22)00583-7. Epub 2022 Oct 14. PMID: 36252579.

Hadeed GJ, Smith J, O'Keeffe T, Kulvatunyou N, Wynne JL, Joseph B, Friese RS, Wachtel TL, Rhee PM, El-Menyar A, Latifi R. Early surgical intervention and its impact on patients presenting with necrotizing soft tissue infections: A single academic center experience. *J Emerg Trauma Shock*. 2016 Jan-Mar;9(1):22-7. doi: 10.4103/0974-2700.173868. PMID: 26957822; PMCID: PMC4766759.

Zacharias N, Velmahos GC, Salama A, Alam HB, de Moya M, King DR, Novelline RA. Diagnosis of necrotizing soft tissue infections by computed tomography. *Arch Surg*. 2010 May;145(5):452-5. doi: 10.1001/archsurg.2010.50. PMID: 20479343

Duane TM, Huston JM, Collom M, Beyer A, Parli S, Buckman S, Shapiro M, McDonald A, Diaz J, Tessier JM, Sanders J. Surgical Infection Society 2020 Updated Guidelines on the Management of Complicated Skin and Soft Tissue Infections. *Surg Infect (Larchmt)*. 2021 May;22(4):383-399. doi: 10.1089/sur.2020.436. Epub 2021 Feb 26. PMID: 33646051

Dorazio J, Chiappelli AL, Shields RK, Tsai YV, Skinker P, Nabozny MJ, Bauza G, Forsythe R, Rosengart MR, Gunn SR, Marini R, Clarke L, Falcione B, Ludwig J, McCreary EK. Clindamycin Plus Vancomycin Versus Linezolid for Treatment of Necrotizing Soft Tissue Infection. *Open Forum Infect Dis*. 2023 May 11;10(6):ofad258. doi: 10.1093/ofid/ofad258. PMID: 37351452; PMCID: PMC10284335.

Tom LK, Wright TJ, Horn DL, Bulger EM, Pham TN, Keys KA. A Skin-Sparing Approach to the Treatment of Necrotizing Soft-Tissue Infections: Thinking Reconstruction at Initial Debridement. *J Am Coll Surg*. 2016 May;222(5):e47-60. doi: 10.1016/j.jamcollsurg.2016.01.008. Epub 2016 Jan 23. PMID: 26968320.

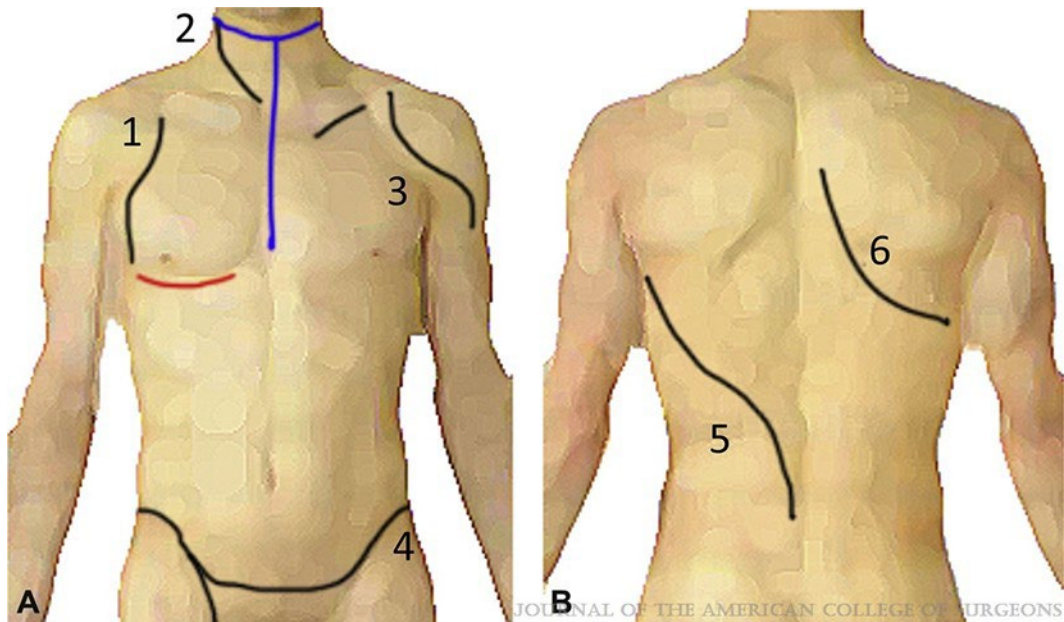
IV. Authors

Stephen Gadomski, MD
Michael J. Derickson, MD
Kelli Rumbaugh, PharmD, BCPS, BCCCP
Jade Flynn, PharmD, BCPS

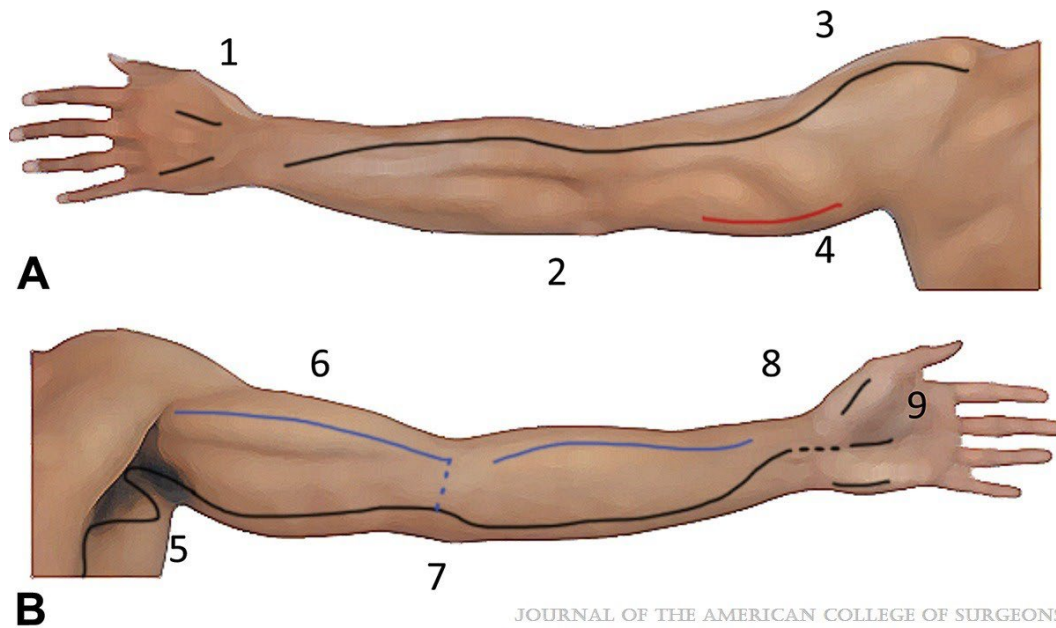
Revisions:

April 2024, April 2026

V. Appendix

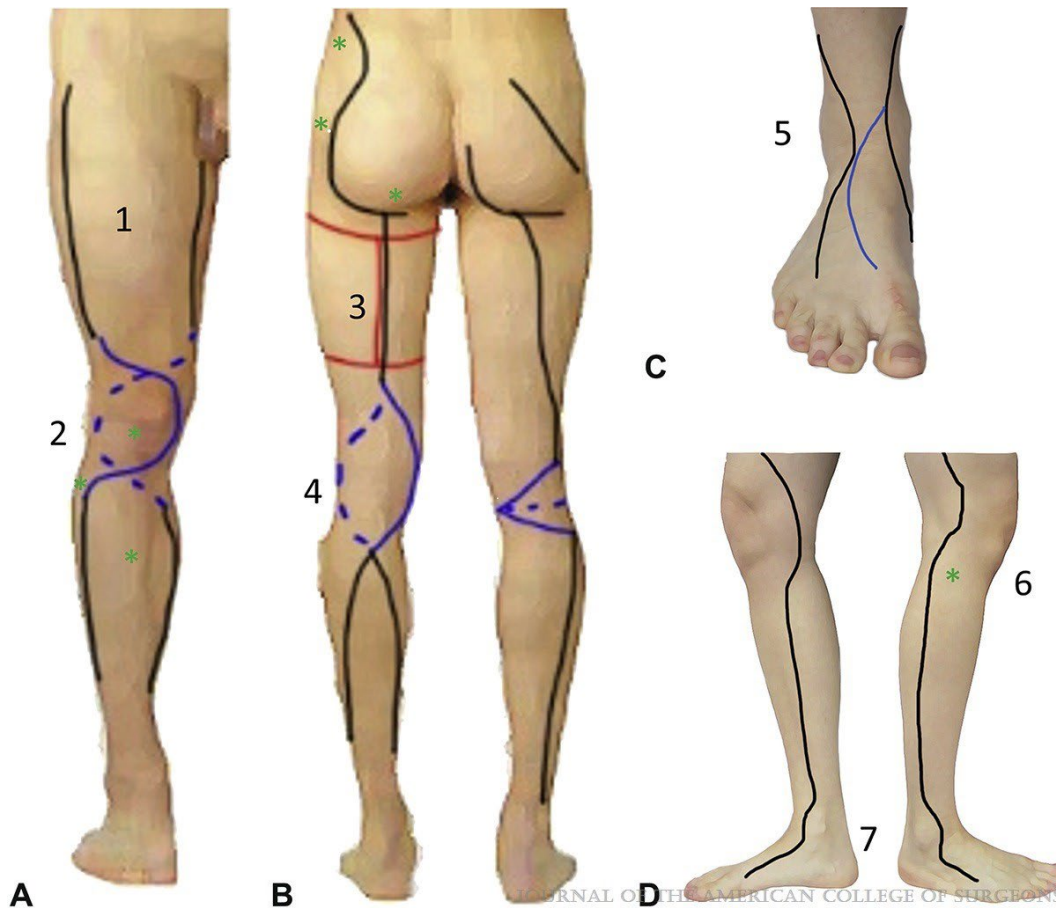


Skin-sparing incision diagrams: torso. (A) Anterior. (1) The lateral chest incision runs along the deltopectoral groove. If needed, an inframammary incision can be used to access tissue deep to the breast (red line). (2) The neck is approached via a Z or lazy S, similar to that used for a neck dissection. If the infection does not have laterality or there is concern for concurrent mediastinitis, a “hangman” approach can be used (blue line). (3) A supraclavicular or infraclavicular incision can be useful for a counter incision for a lower chest infection. The shoulder should be approached through the soft tissue around the deltoid, with attempts to preserve soft tissue over the acromion. (4) An abdominoplasty incision allows for extensive exposure to abdominal wall. This can be extended inferiorly into the groin for additional debridement, especially in infections within a large pannus or Fournier gangrene. The incisions should be mindful of the anterior iliac spine as well as the femoral vessels. (B) Posterior. (5) A lazy-S incision is used to access the underlying latissimus dorsi muscle and provides extensive exposure to the lower back. (6) A curvilinear incision allows for access to the upper back, and preserved coverage over the scapula. (From: Waschke J, Böckers TM, Paulsen F. *Anatomie Das Lehrbuch*. 1st ed. Munich, Germany: Elsevier GmbH, Urban & Fischer; 2015, reprinted with permission.) *Journal of the American College of Surgeons* 222(5):e47-e60, May 2016.

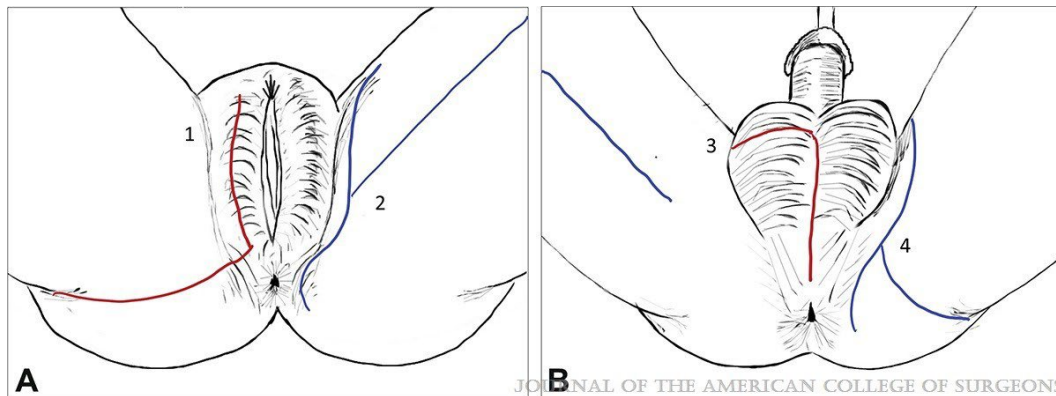


JOURNAL OF THE AMERICAN COLLEGE OF SURGEONS

Skin-sparing incision diagrams: upper extremity. (A) Dorsal. (1) and (9) Fasciotomy techniques should be used in the hand and forearm. (2) The direct incision over the medial condyle of the elbow is avoided to preserve soft tissue over the ulnar nerve. Similarly, direct incision over the olecranon can preserve soft-tissue coverage. (3) The shoulder is approached with preservation of tissue over the acromion. (4) A counter incision can be used to identify additional disease distal to the primary incision (red line). (B) Volar. (5) Z incisions are used within the axilla and joint flexion surfaces to prevent joint contracture. (6) Arm incisions should run either radial (blue line) or ulnar to the bicipital groove to protect underlying brachial artery, median, and ulnar nerve. (7) Direct incisions over the medial epicondyle are avoided to protect the ulnar nerve. The flexion surface should be approached with a z-shaped or a transverse incision (blue line). (8) A bridge of tissue can be preserved overlying the carpal tunnel to maintain coverage of the median nerve. (From: Paulsen F, Waschke J. Sobotta Atlas of Human Anatomy. Vol 2. 15th ed. Munich, Germany: Elsevier GmbH, Urban & Fischer; 2013, reprinted with permission). Journal of the American College of Surgeons 222(5):e47-e60, May 2016.



Skin-sparing incision diagrams: lower extremity. Avoiding direct incisions over the bony prominences, including the trochanter, ischium, patella, fibular head, anterior tibia, and malleoli, guided the design of the incisions, emphasized with green asterisks. (A) Anterior. (1) The thigh can be approached from any angle. These incisions allow for optimal extension from the groin toward the knee. (2) Soft tissue can be elevated completely off the patella using a generous soft-tissue flap (blue line) based either medially or laterally. (B) Posterior. (3) Trap-door flaps can be designed by making perpendicular extensions along the longitudinal incision to allow for elevation both medially and laterally and much larger exposure to underlying tissue (red line). (4) The knee flexure surface is approached with either a curvilinear approach or with a z-shaped incision (blue line). This protects the popliteal fossa and minimizes the risk of future joint contracture. (C) Foot. (5) The distal incisions run anterior to the malleoli, both medial and lateral. (D) Lateral and medial. (6) Incision over the fibular head and common peroneal nerve is avoided. (7) Distal incisions are running anteriorly to both the malleoli. (From: Waschke J, Böckers TM, Paulsen F. Anatomie Das Lehrbuch. 1st ed. Munich, Germany: Elsevier GmbH, Urban & Fischer; 2015, modified with permission.) Journal of the American College of Surgeons 222(5):e47-e60, May 2016.



Skin-sparing incision diagrams: perineum (A) female. (1) Infections of the perineum necessitate exposure and extension around the labia (red line). This can be extended posteriorly along the gluteal cleft. (2) Groin, medial thigh, and anal infections are approached a few centimeters away from the thin surrounding skin. The incisions can be extended distally along the medial thigh (blue line). (B) Male. (3) Scrotal infections are approached through a midline incision that can be extended laterally at the scroto-penile junction (red line). This can be joined with a groin incision to explore distally. (4) Similar to the female demonstration, the groin incision can be extended posteriorly next to the anus or along the gluteal fold (blue line). Journal of the American College of Surgeons 222(5):e47-e60, May 2016.