


CLINICAL RESEARCH



Cutaneous-hemolytic loxoscelism following brown recluse spider envenomation: new understandings

Justin K. Loden^a , Donna L. Seger^{a,b}, Henry A. Spiller^{c,d} , Li Wang^e and Daniel W. Byrne^e

^aTennessee Poison Center, Nashville, TN, USA; ^bDepartment of Medicine, Vanderbilt University School of Medicine, Nashville, TN, USA; ^cCentral Ohio Poison Center, Columbus, OH, USA; ^dNationwide Children's Hospital, Columbus, OH, USA; ^eDepartment of Biostatistics, Vanderbilt University Medical Center, Nashville, TN, USA

ABSTRACT

Background: Brown recluse spider (BRS) (*Loxosceles reclusa*) envenomation can cause local dermonecrotic lesions, constitutional symptoms, and potentially fatal hemolysis (i.e., cutaneous-hemolytic loxoscelism). As the incidence of hemolysis is low and the spider habitat is limited, little is known regarding the clinical course of cutaneous-hemolytic loxoscelism.

Methods: We performed a retrospective observational study of patients following BRS envenomation over an eight-year period. Demographics, clinical course, laboratories, and interventions were assessed. Wilcoxon rank-sum tests and Pearson chi-square tests were used in the univariate analyses. Logistic regression assessed the independent contribution of symptoms in a multivariate analysis.

Results: Of the 97 patients, 40.2% ($n = 39$) developed hemolysis; the majority (66.7%) were 18 years old or younger. Univariate analysis revealed that constitutional symptoms were associated with hemolysis, but multivariate analysis showed only myalgia (aOR: 7.1; 95% CI: 2.2–22.7; $p < .001$) and malaise (aOR: 12.76; 95% CI: 1.4–119.9; $p = .026$) were independently associated with hemolysis. The median time to hemolysis onset was 1.0 days (IQR: 1.0–2.5) and all occurred within a week of envenomation. Hemolysis durations were longer in patients DAT positive for IGG antibodies (7.5 vs. 4.0 days; $p = .042$). Most (76.9%) of hemolyzing patients received blood. In patients with cutaneous-hemolytic loxoscelism, hematuria occurred in 32.4%, rhabdomyolysis occurred in 60.9%, and elevated transaminases with normal hepatic synthetic function occurred in 29.4% but all of these patients developed rhabdomyolysis. Hemolysis was both intravascular and extravascular. Complications (hyperkalemia, $\text{INR} \geq 2.0$, metabolic acidosis requiring bicarbonate, hypotension requiring vasopressors, and hypoxia requiring intubation) occurred only in patients with profound hemolytic anemia (hemoglobin < 4 g/dL); one patient died.

Conclusions: Constitutional symptoms occur in both cutaneous and cutaneous-hemolytic loxoscelism, although they occur more frequently in patients who develop hemolysis. Children may be at a higher risk of hemolysis after envenomation. Renal involvement (as evidenced by hematuria) and rhabdomyolysis may occur more frequently than has been previously reported. Hemolysis was both intravascular and extravascular.

ARTICLE HISTORY

Received 26 September 2019
Revised 30 January 2020
Accepted 25 February 2020

KEYWORDS

Loxoscelism; envenomation; brown recluse spider; hemolysis

Introduction

Potentially fatal hemolysis can occur due to envenomation by the North American brown recluse spider (BRS, *Loxosceles reclusa*). The spider is endemic to the south-central portion of the United States, with the majority of reported cases from Tennessee, Arkansas, Missouri, and Kansas [1,2]. The spider is not aggressive and must often be provoked, such as trapping it against the victim's body while sleeping or dressing [3]. In cutaneous loxoscelism, increasing pain with a violaceous and pale lesion surrounded by erythema (the classic red, white, and blue sign) develops in the first 24 h [4,5]. The lesion indurates and develops into a dry, necrotic eschar approximately 7–10 days after envenomation. The eschar eventually sloughs off leaving an ulcer that typically heals well without surgical intervention [5–7].

Cutaneous-hemolytic loxoscelism is defined as hemolysis in the presence of the skin lesion [8]. This condition is also known as "systemic loxoscelism", but this is not an accurate term as patients with cutaneous loxoscelism can have non-specific constitutional symptoms [3,7–9]. The hemolysis can be acute or insidious but usually develops within 96 h of envenomation. Thrombocytopenia, disseminated intravascular coagulopathy, and acute kidney injury may also occur [10–21]. Death from cutaneous-hemolytic loxoscelism has been reported more in children than adults [22–30]. One of the challenges in treating cutaneous loxoscelism is determining who will develop life-threatening hemolysis and therefore require hospitalization.

The aim of our study was to describe the clinical characteristics and outcomes of patients who developed hemolysis after BRS envenomation.

Materials and methods

Study design and population

This was a retrospective observational study of patients with BRS envenomation that were either seen in the emergency department or admitted with consultation from the medical toxicology service at Vanderbilt University Medical Center (VUMC), a tertiary-care academic medical center. Patients from 1 January 2008 through 31 December 2015 were identified using the toxicology service records. Only BRS envenomations confirmed by a medical toxicologist were included. This study was approved by the Institutional Review Board of VUMC (IRB# 170014).

Data collection

The following information was obtained for all patients from their electronic medical record where available: demographics (age, gender, race), details of the envenomation (timing, location, symptom onset), clinical observations (symptoms, vital signs, physical examination), laboratory results, interventions, and length of hospital stay (LOS). For each parameter, the most extreme measurement appropriate (minimum or maximum) was recorded from the observations.

Definitions

The following definitions were used: tachycardia (HR >100 beats per minute [bpm] in adults or >normal in age group [31]), hypertension (systolic BP >150 mmHg in adults or >normal in age group [31]), hypotension (systolic BP <90 mmHg in adults or <normal in age group [31]), hyperkalemia ($K > 5.5$ mEq/L), hypokalemia ($K < 3.5$ mEq/L), elevated creatinine (increase >50% baseline), acidosis ($\text{CO}_2 < 22$ mEq/L or $\text{pH} < 7.35$), hyperlactatemia (lactate >2.2 mmol/L), rhabdomyolysis (creatinine kinase >300 U/L or positive myoglobinuria), alkaline urine ($\text{pH} > 6.9$), elevated transaminases (AST or ALT >100 U/L), hematuria (≥ 5 red blood cells [RBCs] on microanalysis). The presence of hemolysis was determined by the medical toxicologist(s) taking care of the patient at the time of evaluation and based on

laboratory data, most specifically declining hemoglobin/hematocrit. Hemolysis onset time was defined as the time in days from envenomation to hemolysis (with 0.0 days being 0–24 h, 1.0 days being 24–48 h, etc.). If the onset time was not determined, then it was reported as unavailable. Hemolysis duration was defined as the time in days from hemolysis onset until the hemoglobin/hematocrit stabilized and the urine dipstick was negative for blood. Time to emergency department (ED) presentation was defined as the time in days from envenomation to ED presentation (with 0.0 days being 0–24 h, etc.).

Statistical analysis

Descriptive statistics were used to report continuous variables as median and interquartile range (IQR) or mean with standard deviation, as appropriate. Categorical variables were given in terms of numbers and percentages. Comparison between groups were performed using Wilcoxon rank-sum tests for continuous variables and Pearson chi-square tests for categorical variables. Logistic regression was used to assess the independent contribution of symptoms in a multivariate analysis. Statistical significance was assessed using a significance level of p Value of less than .05. Two-tailed statistical tests were reported. All statistical analyses were performed using R version 3.0.0.

Results

There were 97 patients with BRS envenomation identified during the 8-year study period. The majority of envenomations (77.3%) occurred in the warm weather months between May and September. The median age was 15 years (IQR: 9.5–30.5, mean: 21.9, SD: 16.6) and approximately half were female (54.6%). Thirty-nine (40.2%) patients developed hemolysis. Table 1 summarizes the patient characteristics of those with and without hemolysis. There were no statistically significant differences in age, gender, race, time to presentation, or onset time of constitutional symptoms. More patients with hemolysis (30.8%) were discharged and returned for hospitalization than those without hemolysis (13.8%;

Table 1. Demographics and characteristics of brown recluse spider envenomations.

Brown recluse spider envenomations ($n = 97$)			
Median (IQR)	Hemolysis (39)	Non-hemolysis (58)	p -Value
Age years	14.0 (7.5–23.5)	20.0 (12.2–32.0)	.075*
18 years or younger (n (%))	26 (66.7%)	28 (48.3%)	.074**
Gender, female (n (%))	24 (61.5%)	29 (50.0%)	.26**
Race			.12**
Caucasian (n (%))	23 (59.0%)	44 (75.9%)	
African American (n (%))	13 (33.3%)	9 (15.5%)	
Other (n (%))	3 (7.7%)	5 (8.6%)	
Time to presentation days	2.0 (1.0–3.0)	1.0 (1.0–3.0)	.28*
Discharged and returned	12 (30.8%)	8 (13.8%)	.043**
LOS days	5.0 (3.0–8.8); $N = 26$	1.0 (0.0–2.0); $N = 50$	<.001*
Constitutional symptom onset			.6*
Same day	9 (23.1%)	14 (28.0%); $N = 50$	
Next day	30 (76.9%)	36 (72.0%); $N = 50$	

IQR, interquartile range; LOS, length of stay.

*Wilcoxon rank-sum test.

**Pearson chi-square test.

$p = .043$). Some patients had scheduled clinic follow-up, but these were not included in the return for hospitalization analysis. The median length of stay for patients with hemolysis was 5.0 days (IQR: 3.0–8.8, mean: 5.8, SD: 3.5) and 1.0 days (IQR: 0.0–2.0, mean: 1.3, SD: 1.3) for those without hemolysis ($p < .001$).

Hemolysis

The median time to hemolysis onset was 1.0 days (IQR: 1.0–2.5, mean: 1.9, SD: 1.6). Hemolysis was not apparent until more than 96 h after envenomation in 25.7% patients ($n = 9/35$; information unavailable for four patients). All patients developed hemolysis within a week of envenomation. The median duration of hemolysis was 6.0 days (IQR: 3.0–8.8, mean: 5.7, SD: 2.4). Twenty-nine (74.4%) patients had direct antiglobulin test (DAT) results available: 62.1% were positive for IGG antibodies, 44.8% were positive for complement, and 31.0% were negative for both. Patients with DAT positive for IGG antibodies had a median hemolysis duration of 7.5 days (IQR: 6.0–8.0), and patients with DAT negative for IGG antibodies had a median hemolysis duration of 4.0 days (IQR: 2.5–7.5, $p = .042$).

Clinical/laboratory findings and interventions

Clinical effects and laboratory findings of all patients are summarized in Table 2. All comparisons were statistically significant. All hemolysis patients had spherocytes on peripheral blood smear. Patients with rhabdomyolysis had a median

CPK of 1214 (IQR: 478–2325, mean: 2147, SD: 2441); three patients were positive for myoglobinuria but had no CPK evaluated. Seven patients with elevated creatinine had concomitant rhabdomyolysis. All patients with elevated transaminases had concomitant rhabdomyolysis. Hyperkalemia ($n = 4$), INR ≥ 2.0 ($n = 3$), acidosis that required bicarbonate administration ($n = 3$), and hypotension that required vasopressor support ($n = 3$) occurred only in patients with profound hemolytic anemia (hemoglobin < 4 g/dL). These four patients developed severe anemic hypoxia requiring intubation, one suffered cardiogenic pulmonary edema (global hypokinesia; ejection fraction 40%; peak troponin 4.35 ng/mL). A fifth patient refused blood transfusion for religious reasons and subsequently developed profound anemia, but more information was unavailable as she transferred to another hospital. A sixth patient died of fulminant hemolysis the day of envenomation; her case is discussed elsewhere [27]. Interventions performed on hemolysis patients are provided in Table 3. The most common was blood transfusion (76.9%). The median dose of packed RBCs was 4.5 units (IQR: 4.0–7.0, mean: 4.0, SD: 2.4).

Constitutional symptoms

Exanthem (78.4%), fever/chills (72.2%), malaise (68%), and myalgia (51.5%) were the most prevalent constitutional symptoms. All patients who developed constitutional symptoms did so within 48 h of envenomation. In patients with a defined hemolysis onset time ($n = 35$; information unavailable in four patients), constitutional symptoms developed on the day of envenomation in 25.7% ($n = 9$) patients and the

Table 2. Selected clinical effects associated with brown recluse spider envenomations.

Median (IQR) or N (%)	Hemolysis (39)	Non-hemolysis (58)	p Value
Hematologic effects			
Hemoglobin (initial)	12.2 (11.1–13.7); N = 39	13.5 (12.8–14.4); N = 57	.001*
Hematocrit (initial)	36.5 (32.0–39.0); N = 38	39.0 (37.0–42.0); N = 57	<.001*
Hemoglobin (nadir)	6.8 (5.2–9.1); N = 35	12.2 (11.6–13.0); N = 38	<.001*
Hematocrit (nadir)	20.0 (16.0–26.0); N = 37	35.0 (33.2–37.8); N = 38	<.001*
Leukocytes (initial)	14.4 (10.7–21.3); N = 38	8.3 (6.8–10.4); N = 57	<.001*
Leukocytes (peak)	22.6 (14.8–30.3); N = 39	8.3 (6.8–10.4); N = 57	<.001*
Thrombocytes (initial)	184 (123–226); N = 39	236 (196–274); N = 57	<.001*
Thrombocytes (nadir)	140 (96–188); N = 38	202 (175–242); N = 38	<.001*
INR (peak)	1.25 (1.10–1.50); N = 38	1.10 (1.00–1.20); N = 36	<.001*
Prothrombin time (peak)	15.3 (14.3–18.0); N = 38	14.1 (13.4–14.6); N = 36	<.001*
Partial thromboplastin time (peak)	33.2 (30.0–36.8); N = 37	29.9 (28.2–31.6); N = 36	<.001*
Fibrinogen (peak)	581 (432–613); N = 25	343 (335–420); N = 17	<.001*
D-Dimer (peak)	2.26 (1.44–3.83); N = 21	0.54 (0.36–1.59); N = 12	.014*
LDH (peak)	1015 (540–1336); N = 27	213 (166–249); N = 13	<.001*
Total bilirubin (peak)	5.85 (3.12–8.75); N = 34	0.70 (0.50–1.00); N = 42	<.001*
Other effects			
Hypertension	8 (21.1%); N = 38	0 (0%); N = 58	<.001**
Hypotension	9 (23.7%); N = 38	0 (0%); N = 58	<.001**
Acidosis	21 (55.3%); N = 38	8 (13.8%); N = 58	<.001**
Alkaline urine	28 (73.7%); N = 38	10 (17.2%); N = 58	<.001**
Elevated creatinine	10 (27.0%); N = 37	0 (0%); N = 58	<.001**
Elevated transaminases	10 (29.4%); N = 34	2 (3.77%); N = 53	<.001**
Hyperlactatemia	13 (61.9%); N = 21	0 (0%); N = 14	<.001**
Hyperkalemia	4 (10.8%); N = 37	0 (0%); N = 58	.011**
Hypokalemia	18 (48.6%); N = 37	8 (13.8%); N = 58	<.001**
Hematuria	12 (32.4%); N = 37	0 (0%); N = 58	<.001**
UA dip blood positive	28 (75.7%); N = 37	0 (0%); N = 58	<.001**
Rhabdomyolysis	14 (60.9%); N = 23	1 (6.67%); N = 15	<.001**

INR, international normalized ratio; IQR, interquartile range; LDH, lactate dehydrogenase; UA, urine analysis.

*Wilcoxon rank-sum test.

**Pearson chi-square test.

day-after envenomation in 74.3% ($n=26$) of patients. The median time to hemolysis was 1.0 days (IQR: 0.0–1.0, mean: 0.56, SD: 0.53) in patients who developed constitutional symptoms the day of envenomation and 2.0 days (IQR: 1.0–3.8, mean: 2.38, SD: 1.6) in patients who developed constitutional symptoms the day-after envenomation ($p < .001$).

Univariate and multivariate logistical regression analysis of constitutional symptoms is shown in Table 4. All constitutional symptoms were associated with hemolysis ($p \leq .001$). However, multivariate analysis showed that only myalgia (aOR: 7.1, 95% CI: 2.2–22.7, $p < .001$) and malaise (aOR: 12.76, 95% CI: 1.4–119.9, $p = .026$) were independently associated with the development of hemolysis (see Figure 1).

Discussion

Molecular mechanisms of hemolysis

BRS venom is a complex mixture of toxins, the most clinically significant being those of the sphingomyelinase-D/phospholipase-D (PLD) family. Active isoforms of PLD have the ability to produce an intense inflammatory response, dermonecrotic lesions, hemolysis, thrombocytopenia, nephrotoxicity, and provoke a cytokine response resembling endotoxic/septic shock [32]. Most of the research on the interactions between *Loxosceles* PLD and human erythrocytes comes from the venom of *Loxosceles intermedia*, a brown spider found in South America. Because *reclusa* PLD is 85% identical to *intermedia* PLD [33], and both envenomations produce similar clinical reactions [3,8], it is likely their venoms are comparable. *In vitro* research of *Loxosceles* PLD demonstrates two possible mechanisms of hemolysis.

The first mechanism involves PLD catalytic activity on phospholipids. The erythrocyte plasma membrane contains five major phospholipids unequally distributed between the inner and outer leaflets. Sphingomyelin is present on the outer leaflet and phosphatidylserine on the inner leaflet. *Loxosceles* PLD directly cleaves sphingomyelin which results in the translocation of phosphatidylserine to the outer

leaflet. These erythrocytes lose their biconcave shape, become spherocytes and stomatocytes, and subsequently cause extravascular hemolysis by splenic removal [34]. Additionally, C1q directly binds to the erythrocyte membrane, most likely to the newly exposed phosphatidylserine, and initiates the classical complement pathway resulting in hemolysis [35,36].

The second mechanism involves PLD activity on metalloproteinases. The erythrocyte plasma membrane contains heavily glycosylated proteins, the most prevalent being glycophorin-A, which ensure erythrocyte survival by preventing spontaneous complement deposition. Erythrocyte exposure to *Loxosceles* PLD results in the activation of an unspecified endogenous metalloproteinase that cleaves extracellular portions of glycophorin-A. This enhances C3b deposition to the erythrocyte membrane and initiates the alternative complement pathway resulting in hemolysis [36–38]. Glycophorin-A cleavage and complement-mediated hemolysis activity is transferred from toxin-exposed erythrocytes to toxin-naïve erythrocytes, which explains the extent of hemolysis observed after envenomation [38]. *In vitro* incubation of *L. reclusa* venom with erythrocytes revealed statistically significant reduction in glycophorin-A expression and could be used as a biomarker of venom exposure [39].

Cutaneous-hemolytic loxoscelism

Because we are a tertiary referral center in an area where BRS envenomation is ubiquitous, the toxicology service evaluates a significant number of patients admitted to many different medical specialties. The toxicology service's treatment recommendations are based on clinical experience and include: no ointments on the lesion (anecdotally we saw a number of reactions to triple antibiotic ointment), ice applied to the lesion for pain, no antibiotics, no corticosteroids, no dapsone, and no surgical excision or incision/drainage. However, there were a number of physicians caring for these patients, so treatment was not consistent (i.e., especially the disparity in administering antibiotics and corticosteroids). The recommendation to transfuse patients to a hematocrit of 30% was based on a consensus of physicians treating these patients. As toxin-induced hemolysis can occur quickly, the decision was made to keep the hematocrit at a reasonable number to allow time for blood transfusion in a rapidly hemolyzing patient. Attached is the consensus-based protocol that our institution followed during the study period (see Figure 2).

There have been three studies conducted at our institution on BRS envenomation with varying results. The first was a 30-month (1993–1995) study that identified 111 patients

Table 3. Interventions to hemolysis patients.

	N (%)
Blood transfusion	30 (76.9%)
Antibiotics	24 (61.5%)
Corticosteroids	11 (28.2%)
Intubation	4 (10.3%)
Bicarbonate	3 (7.7%)
Vasopressors	3 (7.7%)
Diuretics	3 (7.7%)
Fresh frozen plasma	3 (7.7%)
Platelets	2 (5.1%)
Vasodilators	1 (2.6%)

Table 4. Comparison of constitutional symptoms between hemolysis and non-hemolysis patients.

Symptom N (%)	Hemolysis (39)	Non-hemolysis (58)	OR (95% CI)	p Value	aOR (95% CI)	p Value
Malaise	38 (97.4%)	28 (48.3%)	40.7 (5.2–316.7)	<.001	12.76 (1.4–119.9)	.026
Myalgia	32 (82.1%)	18 (31.0%)	10.2 (3.8–27.3)	<.001	7.1 (2.2–22.7)	<.001
Fever/chills	36 (92.3%)	34 (58.6%)	8.5 (2.3–30.7)	<.001	1.73 (0.26–11.43)	.571
Nausea	28 (71.8%)	20 (34.5%)	4.8 (2.0–11.7)	<.001	2.16 (0.68–6.88)	.193
Tachycardia	26 (66.7%)	18 (31.0%)	4.4 (1.9–10.6)	.001	1.41 (0.44–4.47)	.563
Exanthema	37 (94.9%)	39 (67.2%)	9.0 (2.0–41.4)	.001	3.53 (0.53–23.34)	.191

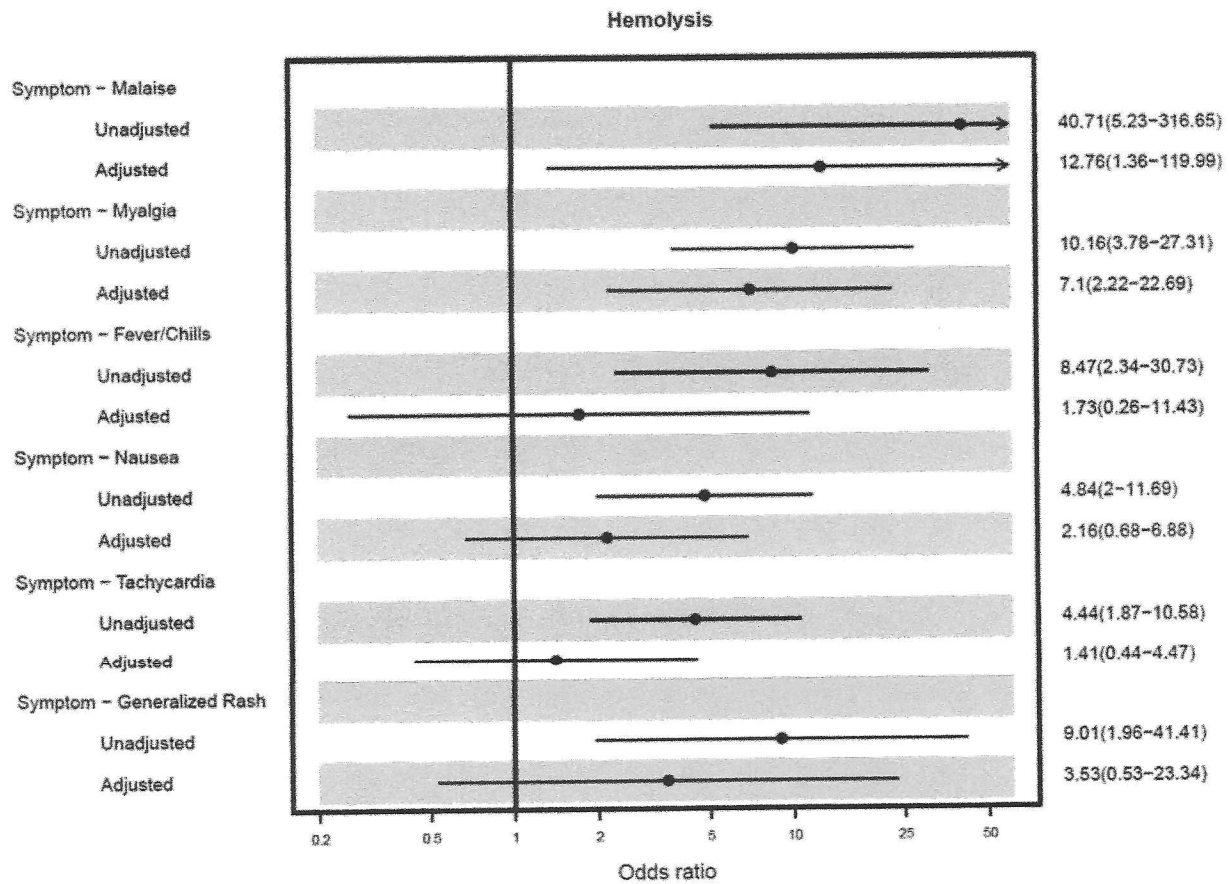


Figure 1. Comparison of constitutional symptoms between hemolysis and non-hemolysis patients.

Guideline for Brown Recluse Spider Envenomation

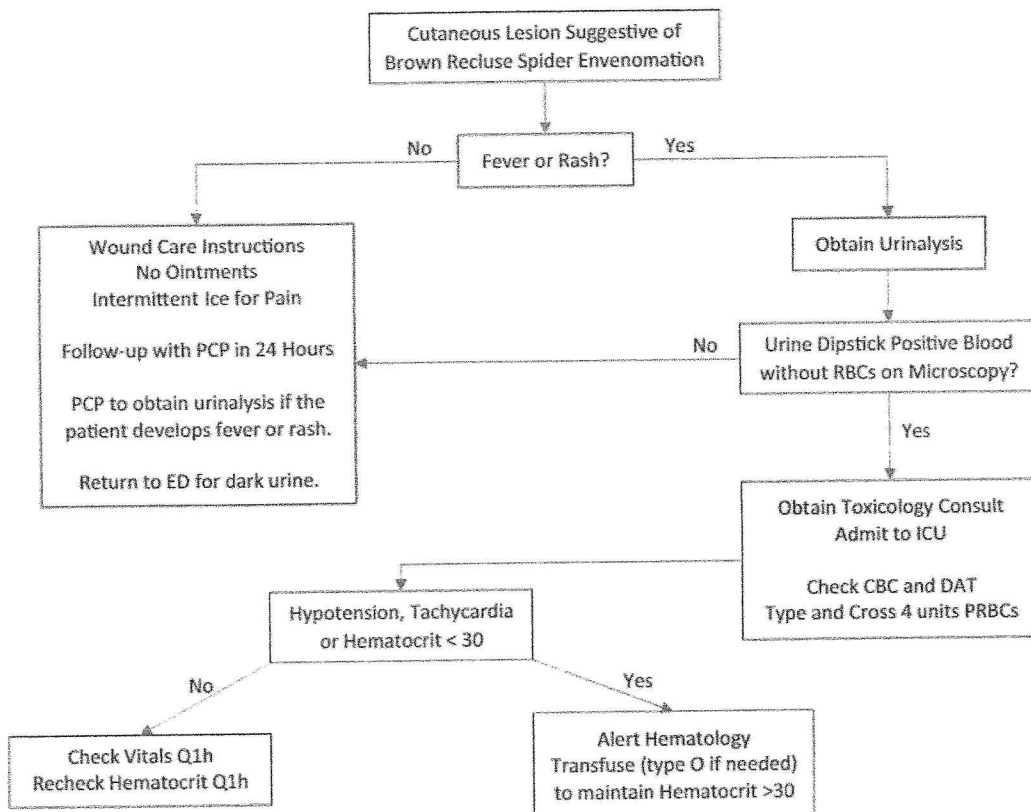


Figure 2. Guideline for brown recluse spider envenomation.

Draft Guideline for Brown Recluse Spider Envenomation

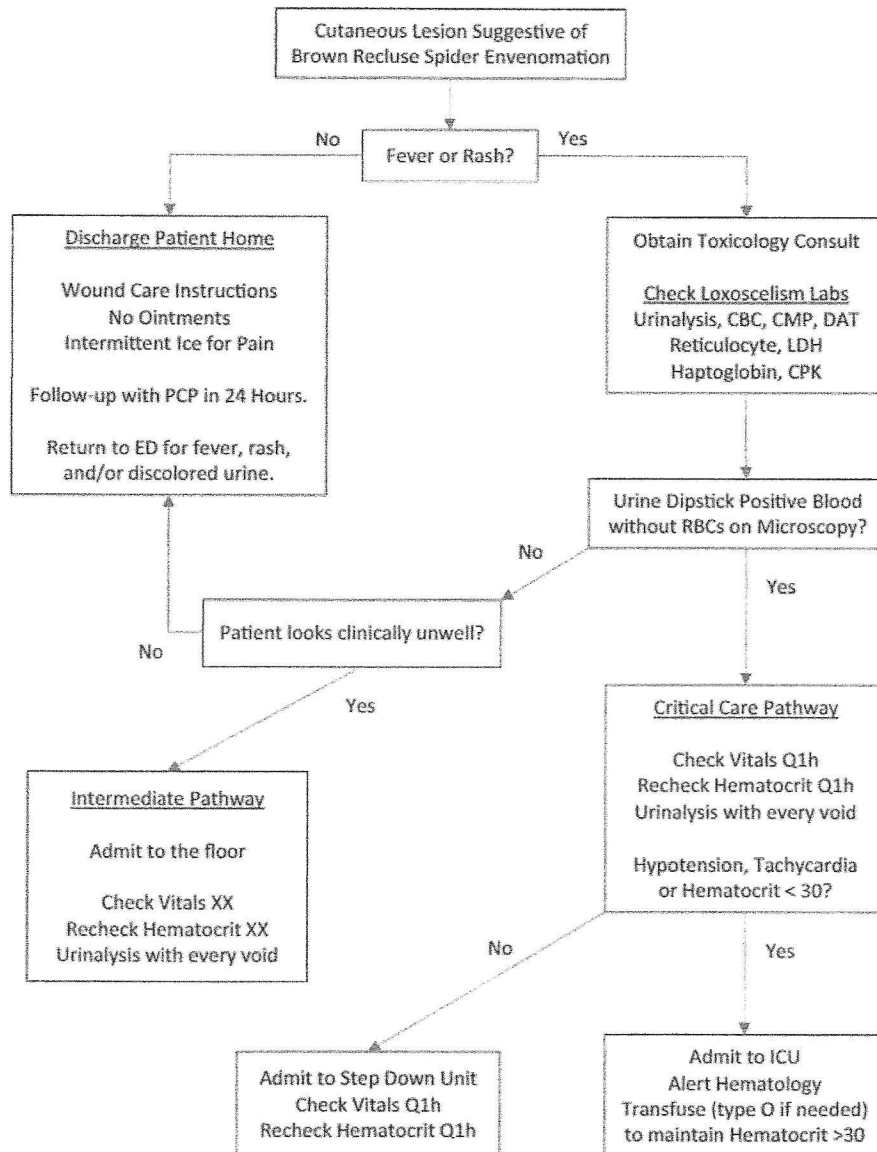


Figure 3. Draft guideline for brown recluse spider envenomation.

who presented to the VUMC ED or toxicology clinic with a suspected BRS envenomation. Such patients were identified through a search of ICD-9 discharge diagnosis codes. Only two (1.8%) patients developed hemolysis while 16 (14.4%) had systemic symptoms and 24 (21.6%) had rash [7].

The second was a 20-year (1995–2015) study that used the VUMC Synthetic Derivative, a de-identified database that contains access to over 2.4 million patient electronic health records, to locate 205 patients with suspected BRS envenomation. This study identified 57 (27.8%) patients with moderate to severe loxoscelism (defined as the presence of a documented diagnosis of hemolysis or disseminated intravascular coagulation, need for blood transfusion, or hemodynamic instability), 58 (28.3%) patients with mild loxoscelism, and 90 (43.9%) patients with cutaneous-only symptoms [40].

Our study is the third, an eight-year (2008–2015) observation that identified 97 patients with BRS envenomation confirmed by a medical toxicologist. We report a high frequency

of hemolysis (40.2%, $n = 39$) and constitutional symptoms (78.4%, $n = 76$) in our cohort. One of the reasons for the disparity from the previous studies may be the difference in data collection. Our study may have identified patients who were more ill, as all were referred to the medical toxicology service, but it may not include patients admitted to other medical services. No single data collection method identified all the patients as demonstrated by the variability in results from three studies conducted at the same institution.

Yet, the number of patients with hemolysis has markedly increased over time. Only two patients with hemolysis were reported from 1993 to 1995, 57 patients from 1995 to 2015, and 39 patients from 2008 to 2015. The number of patients captured in our study may be underestimated as there may have been patients admitted to the hospital without medical toxicology consultation. Whether this increase in frequency of cutaneous-hemolytic loxoscelism is actual or spurious is unknown.

In our series, the majority (66.7%) of patients with hemolysis were 18 years old or younger, which is consistent with previous reports [15,16,18], and supports the hypothesis that children are highly susceptible to hemolysis after envenomation.

Although hemolysis is thought to occur within 96 h of envenomation [5], reports demonstrate hemolysis developing much later [41]. Eight (61.5%) patients in a previous series [16] and nine (25.7%) in our study developed hemolysis greater than 96 h post-envenomation. Additionally, 12 (30.8%) patients with hemolysis in our cohort were discharged and returned for further hospitalization.

DAT was not consistently positive for either complement or IGG antibodies in hemolysis patients; 18 (62.1%, $n=29$) patients were positive for IGG antibodies, 13 (44.8%, $n=29$) were positive for complement, and nine (31.0%, $n=29$) were negative for both. This contrasts to *in vitro* research which demonstrated exposure of human erythrocytes to *L. reclusa* venom with a source of complement (e.g., fresh frozen plasma) led to both IGG and complement deposition on the erythrocyte membrane [39]. The incidence of DAT positivity in cutaneous-hemolytic loxoscelism is unknown, although one case series reported 50% of patients were DAT positive for IGG antibodies [18]. In our cohort, hemolysis lasted longer in IGG positive patients (7.5 days) compared to those who were IGG negative (4.0 days).

Extravascular versus intravascular hemolysis

Most of the literature regarding cutaneous-hemolytic loxoscelism does not address whether the site of hemolysis is intravascular or extravascular. Our study demonstrated that both were evident in patients with hemolysis. The initial screening test for intravascular hemolysis is a urine dipstick positive for blood with no or very few microscopically visible erythrocytes [42], which was the case in 28 (75.7%, $n=37$) patients with hemolysis. However, negative urine dipsticks occurred in nine (24.3%, $n=37$) patients with hemolysis, indicating that these patients must be only undergoing extravascular hemolysis, especially in the setting of toxin-induced spherocytosis and stomatocytosis. Our study demonstrates that both intravascular and extravascular hemolysis may occur in loxoscelism which has not previously been reported. Why only extravascular hemolysis would occur in a subset of patients is unknown. As a result of this series, a clinical practice committee is developing a new protocol with the intent of safeguarding patients who would not be identified with urinalysis but may be undergoing extravascular hemolysis (see Figure 3).

Hematuria and nephrotoxicity

Although hematuria has been reported following envenomation in South American studies, it has been reported in very few cases of *reclusa* envenomation. Hematuria occurred in 12 (32.4%, $n=37$) patients who developed hemolysis, indicating renal involvement which is supported by animal experiments. Mice exposed to *L. intermedia* venom developed

histopathologic findings of nephrotoxicity including diffuse glomerular edema, focal collapse of the glomerular basement membrane, erythrocytes in Bowman's space, and diffuse hyalinization in the proximal and distal tubules. Biochemical abnormalities in the treated mice included alkaline urine, elevated BUN, and hematuria in the absence of hemolysis. The renal injury is not associated with polymorphonuclear infiltration but is more likely mediated by cytokines [43]. If *reclusa* and *intermedia* toxin are similar, one could postulate that envenomation causes nephrotoxicity manifested by hematuria in some patients. Whether this occurs prior to hemolysis, concurrent with hemolysis, or is unrelated to hemolysis is unknown. In a previous study, six (10.5%) patients with moderate to severe loxoscelism developed an elevated creatinine (increase >100% baseline) while three required hemodialysis, although it is unclear who had underlying renal dysfunction and why hemodialysis was performed [40]. In our study, 10 (27%, $n=37$) patients with hemolysis developed an elevated creatinine (increase >50% baseline) but none required hemodialysis. The potential nephrotoxicity caused by envenomation may be underestimated.

Hypokalemia

The hemolysis group had a much higher incidence of hypokalemia than hyperkalemia (48.6% vs. 10.8%), with two patients initially developing hypokalemia then hyperkalemia later in the clinical course. Hyperkalemia, not hypokalemia, is expected in patients with hemolysis and rhabdomyolysis due to the release of intracellular potassium but was only found in patients with profound hemolytic anemia (hemoglobin <4 g/dL). Hypokalemia could not be explained with concomitant therapies. The hypokalemia may be due to renal tubular acidosis induced by the venom [43] and is supported by the presence of alkaline urine (73.7%).

Leukocytosis

The leukocyte count was significantly higher on presentation in patients with hemolysis compared to those without hemolysis (14.4 vs. 8.3, $p<.001$). Leukocytes continued to trend upward in those with hemolysis but remained normal in patients without hemolysis. The etiology of leukocytosis is likely multifactorial. Incubation of human cells with *L. reclusa* venom *in vitro* induced a 6.4-fold increase in granulocyte-macrophage colony-stimulating factor (GM-CSF) release by four hours [44] which would cause brisk leukocytosis. A stress reaction from myalgia that occurs in the first 24 h after envenomation would also cause early leukocytosis [4,45]. Patients with acute hemolytic anemia may experience leukocytosis both as a stress reaction and as an increase in leukocyte production with the concomitant increase in erythrocyte production [45]. Also, corticosteroids frequently cause acute and persistent leukocytosis [46] (which 28.2% of hemolysis patients received).

Rhabdomyolysis and transaminases

Although elevated transaminases occurred in 10 (29.4%, $n = 34$) patients, there was no indication of hepatic synthetic dysfunction; all patients with elevated transaminases had concomitant rhabdomyolysis. Rhabdomyolysis occurred in 14 (60.9%, $n = 23$) patients, whereas creatinine doubled in 10 (27%, $n = 37$) patients. Seven patients with elevated creatinine had concomitant rhabdomyolysis.

Limitations

There are several limitations to our study. First, the retrospective design of our study incurs possible inaccuracies in history and missing data. Second, BRS envenomation is a clinical diagnosis as there is no commercially available test to detect the venom. However, the patients in our study were diagnosed by a team of medical toxicologists with significant experience in dealing with these envenomations. Third, hemolysis onset times were limited to whole days after bite and would be more accurate if calculated in hours and there may have been patient recall bias. Fourth, the potential false-negative urine dips for blood in hemolysis patients could affect the overall estimation of hemolysis onset and duration times. Fifth, selection bias may have occurred as only those patients referred to a medical toxicologist were included in the study.

Conclusions

Constitutional symptoms have been reported in both forms of loxoscelism, although they occurred more frequently in patients with cutaneous-hemolytic loxoscelism. Exanthem and fever/chills were the most common constitutional symptoms among both the groups. Children appear to be at a higher risk of developing hemolysis. Hemolysis may develop beyond 96 h of envenomation but typically occurs within a week. Hemolysis durations were longer in patients with DAT positive for IGG antibodies. For the first time, we have demonstrated that hemolysis is both intravascular and extravascular. Renal involvement, as evidenced by hematuria, elevated transaminases without alteration in hepatic synthetic function, and rhabdomyolysis occurred in a significant number of patients. The extent of organ involvement in cutaneous-hemolytic loxoscelism may be underestimated.



Disclosure statement

No potential conflict of interest was reported by the author(s).

Funding

Research reported in this publication was supported by the National Center for Advancing Translational Sciences of the National Institute of Health (NIH) under award number UL1TR002243. The content is solely the responsibility of the authors and does not necessarily represent the official views of the NIH.

ORCID

Justin K. Loden  <http://orcid.org/0000-0002-3301-2644>
Henry A. Spiller  <http://orcid.org/0000-0002-0121-7055>

References

- [1] Vetter RS. The distribution of brown recluse spiders in the southeastern quadrant of the United States in relation to loxoscelism diagnoses. *South Med J*. 2009;102(5):518–522.
- [2] Vetter RS. Arachnids submitted as suspected brown recluse spiders (*Araneae: Sicariidae*): *Loxosceles* spiders are virtually restricted to their known distributions but are perceived to exist throughout the United States. *J Med Entomol*. 2005;42(4):512–521.
- [3] Malaque CM, Castro-Valencia JE, Cardoso JL, et al. Clinical and epidemiological features of definitive and presumed loxoscelism in Sao Paulo, Brazil. *Rev Inst Med Trop Sao Paulo*. 2002;44(3):139–143.
- [4] Payne KS, Schilli K, Meier K, et al. Extreme pain from brown recluse spider bites: model for cytokine-driven pain. *JAMA Dermatol*. 2014;150(11):1205–1208.
- [5] Vetter RS. Spider envenomation in North America. *Crit Care Nurs Clin North Am*. 2013;25(2):205–232.
- [6] Sams HH, Hearth SB, Long LL, et al. Nineteen documented cases of *Loxosceles reclusa* envenomation. *J Am Acad Dermatol*. 2001;44(4):603–608.
- [7] Wright SW, Wrenn KD, Murray L, et al. Clinical presentation and outcome of brown recluse spider bite. *Ann Emerg Med*. 1997;30(1):28–32.
- [8] Malaque CM, Santoro ML, Cardoso JL, et al. Clinical picture and laboratorial evaluation of human loxoscelism. *Toxicon*. 2011;58(8):664–671.
- [9] Rees R, Campbell D, Rieger E, et al. The diagnosis and treatment of brown recluse spider bites. *Ann Emerg Med*. 1987;16(9):945–949.
- [10] Abraham M, Tilzer L, Hoehn KS, et al. Therapeutic plasma exchange for refractory hemolysis after brown recluse spider (*Loxosceles reclusa*) envenomation. *J Med Toxicol*. 2015;11(3):364–367.
- [11] Anwar S, Torosyan R, Ginsberg C, et al. Clinicopathological course of acute kidney injury following brown recluse (*Loxosceles reclusa*) envenomation. *Clin Kidney J*. 2013;6(6):609–612.
- [12] Blackall DP. Transfusion medicine illustrated: intravascular hemolysis with brown recluse spider envenomation. *Transfusion*. 2004;44(11):1543–1543.
- [13] Dandoy C, Grimley M. Secondary hemophagocytic lymphohistiocytosis (HLH) from a presumed brown recluse spider bite. *J Clin Immunol*. 2014;34(5):544–547.
- [14] de Souza AL, Malaque CM, Sztajn bok J, et al. *Loxosceles* venom-induced cytokine activation, hemolysis, and acute kidney injury. *Toxicon*. 2008;51(1):151–156.
- [15] Elbahlawan LM, Stidham GL, Bugnitz MC, et al. Severe systemic reaction to *Loxosceles reclusa* spider bites in a pediatric population. *Pediatr Emerg Care*. 2005;21(3):177–180.
- [16] Hubbard JJ, James LP. Complications and outcomes of brown recluse spider bites in children. *Clin Pediatr*. 2011;50(3):252–258.
- [17] Lane L, McCoppin HH, Dyer J. Acute generalized exanthematous pustulosis and Coombs-positive hemolytic anemia in a child following *Loxosceles reclusa* envenomation. *Pediatr Dermatol*. 2011;28(6):685–688.
- [18] McDade J, Aygun B, Ware RE. Brown recluse spider (*Loxosceles reclusa*) envenomation leading to acute hemolytic anemia in six adolescents. *J Pediatr*. 2010;156(1):155–157.
- [19] Raza S, Shortridge JR, Kodali MK, et al. Severe haemolytic anemia with erythrophagocytosis following the bite of a brown recluse spider. *Br J Haematol*. 2014;167(1):1.
- [20] Said A, Hmiel P, Goldsmith M, et al. Successful use of plasma exchange for profound hemolysis in a child with loxoscelism. *Pediatrics*. 2014;134(5):e1464–e1467.

- [21] Williams ST, Khare VK, Johnston GA, et al. Severe intravascular hemolysis associated with brown recluse spider envenomation. A report of two cases and review of the literature. *Am J Clin Pathol*. 1995;104(4):463–467.
- [22] Ginsburg CM, Weinberg AG. Hemolytic anemia and multiorgan failure associated with localized cutaneous lesion. *J Pediatr*. 1988; 112(3):496–499.
- [23] Lessenden CM, Zimmer LK. Brown spider bites: a survey of the current problem. *J Kans Med Soc*. 1960;61:379–385.
- [24] Nicholson JF, Nicholson BH. Hemolytic anemia from brown spider bite, necrotic arachnidism. *J Okla State Med Assoc*. 1962;55: 234–236.
- [25] Riley HD, McLean WR, Start AH, et al. Brown spider bite with severe hemolytic phenomena. *J Okla State Med Assoc*. 1964;57: 218–223.
- [26] Rose NJ. Report of fatality: spider bite (*Loxosceles*). *IMJ Ill Med J*. 1970;137(4):339.
- [27] Rosen JL, Dumitru JK, Langley EW, et al. Emergency department death from systemic loxoscelism. *Ann Emerg Med*. 2012;60(4): 439–441.
- [28] Sood SB, Banner W, Barton RP. Extracorporeal cardiopulmonary resuscitation after brown recluse envenomation. *Clin Toxicol*. 2017;55(5):368–369.
- [29] Taylor EH, Denny WF. Hemolysis, renal failure and death, presumed secondary to bite of brown recluse spider. *South Med J*. 1966;59(10):1209–1211.
- [30] Vorse H, Seccareccio P, Woodruff K, et al. Disseminated intravascular coagulopathy following fatal brown spider bite (necrotic arachnidism). *J Pediatr*. 1972;80(6):1035–1037.
- [31] American Heart Association. Pediatric Advanced Life Support (PALS) Provider Manual. Dallas, TX: American Heart Association; 2006.
- [32] Gremski LH, Trevisan-Silva D, Ferrer VP, et al. Recent advances in the understanding of brown spider venoms: from the biology of spiders to the molecular mechanisms of toxins. *Toxicon*. 2014;83: 91–120.
- [33] Lee S, Lynch KR. Brown recluse spider (*Loxosceles reclusa*) venom phospholipase D (PLD) generates lysophosphatidic acid (LPA). *Biochem J*. 2005;391(Pt 2):317–323.
- [34] Chaves-Moreira D, Chaim OM, Sade YB, et al. Identification of a direct hemolytic effect dependent on the catalytic activity induced by phospholipase-D (dermonecrotic toxin) from brown spider venom. *J Cell Biochem*. 2009;107(4):655–666.
- [35] Tambourgi DV, Pedrosa MF, de Andrade RM, et al. Sphingomyelinases D induce direct association of C1q to the erythrocyte membrane causing complement mediated autologous hemolysis. *Mol Immunol*. 2007;44(4):576–582.
- [36] Tambourgi DV, de Sousa da Silva M, Billington SJ, et al. Mechanism of induction of complement susceptibility of erythrocytes by spider and bacterial sphingomyelinases. *Immunology*. 2002;107(1):93–101.
- [37] Tambourgi DV, Paixao-Cavalcante D, de Andrade RM, et al. *Loxosceles* sphingomyelinase induces complement-dependent dermonecrosis, neutrophil infiltration, and endogenous gelatinase expression. *J Invest Dermatol*. 2005;124(4):725–731.
- [38] Tambourgi DV, Morgan BP, de Andrade RM, et al. *Loxosceles intermedia* spider envenomation induces activation of an endogenous metalloproteinase, resulting in cleavage of glycophorins from the erythrocyte surface and facilitating complement-mediated lysis. *Blood*. 2000;95(2):683–691.
- [39] Gehrie EA, Nian H, Young PP. Brown recluse spider bite mediated hemolysis: clinical features, a possible role for complement inhibitor therapy, and reduced RBC surface glycophorin A as a potential biomarker of venom exposure. *PLoS One*. 2013;8(9):e76558.
- [40] Robinson JR, Kennedy VE, Doss Y, et al. Defining the complex phenotype of severe systemic loxoscelism using a large electronic health record cohort. *PLoS One*. 2017;12(4):e0174941.
- [41] Murray LM, Seger DL. Hemolytic anemia following a presumptive brown recluse spider bite. *J Toxicol Clin Toxicol*. 1994;32(4): 451–456.
- [42] Winter WE. The kidney. In: Laposata M, editor. *Laboratory medicine: the diagnosis of disease in the clinical laboratory*. 2nd ed. New York, NY: McGraw-Hill; 2014:385–396.
- [43] Chaim OM, Sade YB, da Silveira RB, et al. Brown spider dermonecrotic toxin directly induces nephrotoxicity. *Toxicol Appl Pharmacol*. 2006;211(1):64–77.
- [44] Patel KD, Modur V, Zimmerman GA, et al. The necrotic venom of the brown recluse spider induces dysregulated endothelial cell-dependent neutrophil activation. Differential induction of GM-CSF, IL-8, and E-selectin expression. *J Clin Invest*. 1994;94(2): 631–642.
- [45] Cerny J, Rosmarin AG. Why does my patient have leukocytosis? *Hematol Oncol Clin North Am*. 2012;26(2):303–319. viii.
- [46] Shoenfeld Y, Gurewich Y, Gallant LA, et al. Prednisone-induced leukocytosis. Influence of dosage, method and duration of administration on the degree of leukocytosis. *Am J Med*. 1981; 71(5):773–778.