



# Patellar Dislocations: Review of Current Literature and Return to Play Potential

Chan Gao<sup>1</sup> · Aaron Yang<sup>1</sup>

Published online: 22 March 2018  
© Springer Science+Business Media, LLC, part of Springer Nature 2018

## Abstract

Acute patellar dislocation is a common cause of traumatic hemarthrosis and is associated with multiple anatomical abnormalities including patella alta, trochlea dysplasia, and malalignment of lower limbs. The medial patellofemoral ligament (MPFL) stabilizes the patella in the early flexion or terminal extension and ruptures in most of first-time patellar dislocations. Thorough radiological evaluations of the MPFL and predisposing anatomical properties are required for the planning of management of recurrent instability. Conservative treatment is the mainstay management of first-time patellar dislocation and achieves good to excellent outcome in most of the patients. Surgery is indicated for recurrent patellar dislocations and first-time patellar dislocations complicated by osteochondral injuries or major MPFL injuries with high functional demand. Return to sports requires painless full range of motion and symmetrical muscle strength in addition to focusing on sport-specific training. Home exercise and behavior modifications in ADLs are important to decrease the reoccurrence of patellar dislocation/subluxation.

**Keywords** Patellar dislocation · Patellar instability · Knee pain · MPFL

## Introduction

Acute patellar dislocation is a common knee injury typically seen in active young individuals. It can cause anterior knee pain, continued feeling of instability, and significant limitations of physical activities even in the absence of further dislocation [1]. In the long term, patellar dislocation is associated with cartilage deterioration and a risk factor for the development of patellofemoral osteoarthritis with an adjusted odds ratio of 3.2 [2, 3]. The patella dislocates laterally in a vast majority of cases. “Recurrent patellar dislocation” refers to episodic dislocation triggered by traumatic event. In contrast, habitual dislocation is a condition where the patella dislocates at flexion and relocates spontaneously at extension. Habitual dislocation presents in childhood after patients start to walk and is not within the scope of this review article [4].

---

This article is part of the Topical Collection on *Sports Medicine Rehabilitation*

---

✉ Chan Gao  
chan.gao@vanderbilt.edu

<sup>1</sup> Department of Physical Medicine and Rehabilitation, Vanderbilt University Medical Center, Nashville, TN 37232, USA

## Epidemiology

Acute traumatic patellar dislocation is the second most common cause of traumatic hemarthrosis of the knee, secondary to anterior cruciate ligament tear [5, 6]. It accounts for approximately 3% of all knee injuries with the annual incidence of first patellar dislocation being reported between 6 and 43 in 100,000 [7, 8]. Risk is highest among females 10 to 17 years old [7]. The incidence is 104 in 100,000 in females and 29 in 100,000 persons aged between 10 and 17 years old [9, 10]. It is reported that 69% of the patients with first-time patellar dislocation are between the ages of 10 and 19 years [7].

The reported rate of recurrent patellofemoral dislocation varies widely ranging from 15 to 80% [11]. The risk of further patellofemoral injury increases greater than 50% if a second dislocation occurs [7]. Other predisposing factors for recurrent dislocation include younger age, skeletal immaturity, sports related injury, general hypermobility, a positive family history, and history of contralateral patellar dislocation [1, 7, 8, 12, 13].

## Etiology

More than 70% of first patellar dislocation occur while playing sports and occurs less frequently when performing

activities of daily living or sustaining direct trauma [1]. The patella is prone to dislocate when the knee is subjected to valgus stress in terminal extension such as when the femur rotates internally relative to the tibia with the foot planted on the ground [10, 14]. Additionally, various anatomical structures involved in patellar stability, including femoral trochlea, patella, ligaments, muscles, and lower limb alignment, have been investigated and will be discussed in further detail below.

The patella articulates with the anterior surface of the trochlear groove and femoral condyles which improves the mechanical efficiency of the knee extensors. The stability of the patellofemoral joint is a product of interaction among three categories of components that prevent the patella from lateral dislocation [6, 15]. Static bony constraints derived from patellofemoral joint congruity [2], passive restraint from noncontractile structures, and [3] active stabilizer by muscle contraction.

### Trochlea Dysplasia

The lateral aspect of the femoral trochlea extends more anteriorly than its medial aspect and this geometrical property impedes the patella from lateral translation [16]. The bony stabilization of the patella provided by the bony contact takes place at knee flexion between 30° and 100°, when the patella enters the boundaries of the trochlea [17]. Abnormal trochlear morphological property can reduce the lateral stability by 70% when the knee is flexed at 30° as reported in a cadaver study [16]. Trochlear dysplasia is characterized by decreased depth, a flat or even convex trochlear surface. It increases the risk of recurrent instability by three times in patients of any age. In addition, the risk of recurrent instability is 4.2 times of normal individuals in the presence of concurrent patella alta and trochlear dysplasia [8]. In children, it has the strongest association with lateral patellar dislocation among all the anatomical risk factors [18].

### Patellar Position

The vertical position of the patella relative to the trochlear groove is another determinant of patellar stability. A “high-riding” patella, also known as “patella alta,” delays the engagement of the patella into the trochlear groove and increases the risk of dislocation at early knee flexion [19]. Patella alta was reportedly present in 50 to 60% of primary patellar dislocations [20].

### Retinacular and Ligamentous Structures

In early knee flexion from 0 to 20° of terminal extension, the patella is out of the confines of the femoral trochlea. As a result, there is lack of bony stabilization and the medial and lateral soft tissue structures are relied upon for this role [21,

22]. The essential medial structures include the superficial medial retinaculum and three ligaments, namely medial patellofemoral ligament (MPFL), patellomeniscal ligament, and patellotibial ligament. MPFL originates from Schottle point, which is defined as the point between the femoral adductor tubercle and the medial epicondyle, and inserts into two thirds of the medial margin of patella with connections with joint capsule, medial retinaculum, medial collateral ligament, and quadriceps [23, 24, 25, 26]. MPFL accounts for 50–80% of the counteracting forces against lateral dislocation. It sustains the greatest strain with the knee fully extended and becomes lax as the patella enters the trochlear groove [27]. MPFL injury is complicated in over 90% of first-time patellar dislocations and exerts a more prominent role in recurrent instability than other predisposing anatomical morphological properties; as a result, there is ongoing debate on what the optimal treatment is after first-time patellar dislocation [13, 28, 29, 30].

The superficial and deep lateral retinaculum forms on the lateral side of the knee. The superficial layer is composed of fibrous expansion of the vastus lateralis (VL) anteriorly and superficial oblique retinaculum posteriorly [31, 32]. The deep layer consists of the epicondylopatellar ligament and patellotibial band. Most of the lateral retinaculum, including superficial oblique retinaculum and epicondylopatellar ligament, is contributed by the iliotibial (IT) band [33]. Lateral stabilization by the lateral retinaculum is mostly influenced by the tightness of the IT band which is greatest at 20° of flexion [16]. It was estimated that the restraint resulting from the IT band account for 22% of the soft tissue restraint [22].

### Vastus Medialis Obliquus

The vastus medialis obliquus (VMO) stabilizes the patella by active contraction, passive muscle resistance, and its close connection with the MPFL [15]. Owing to the orientation of muscle fibers, the VMO contributes little to knee extension; however, it enhances the mechanical efficiency of the knee extensor by controlling the patella within the trochlear groove [34]. As the orientation of VMO fibers varies with the degree of knee flexion, the VMO achieves the most efficient pull of the patella medially at deep knee flexion [35]. Delayed activation of VMO in comparison to VL in patellofemoral syndrome was found in previous EMG study [36].

### Lower Limb Alignment

Malalignment associated with patellar instability include femoral anteversion, external tibial rotation, genu recurvatum, genu valgum, and subtalar pronation [30, 37]. Flat foot is found to be associated with increased Q angle and the risk of patellar instability [38].

## Diagnosis and Prognosis

More than 90% of patellar dislocation occurs after sustaining flexion and valgus strain at the knee without direct contact. However, direct tangential forces can dislocate the patella under rare circumstances [9]. At the time of dislocation, patients may feel a sensation of “slippage” of the patella, severe knee pain, and joint swelling secondary to hemarthrosis. Acute patellar dislocation can be complicated by MPFL injury and osteochondral fracture which can cause mechanical locking or catching in addition to anterior knee pain [9]. Chronically, patients may report recurrent unease sensation, persistent knee pain, impaired functional status, and loss of confidence in resuming previous physical activities. Activities involving cutting or pivoting of the knee tend to be limited. Careful history taking should include injury mechanism, number of previous subluxations/dislocations of the bilateral knees, presence of general ligamentous laxity, and family history of patellofemoral instability [1].

Acute patellar dislocation often causes bloody joint effusion with crepitus. The presence of medial retinacular tenderness is an indicator of MPFL injuries [15]. Physical examination should include evaluation of general joint hypermobility and overall rotational and angular alignment of the lower limbs. Femoral anteversion can be estimated by examining hip rotation. Dynamic evaluation of alignment can be performed by asking the patient to perform a single-leg squat. The Q angle, formed by the vectors of quadriceps and patellar tendon, is an indicator of the orientation of pull on the patella exerted by quadriceps [39]. Increased Q angle, denoting lateral displacement force, can be caused by excessive femoral anteversion and increased tibial external rotation. The flexed Q angle renders greater reliability than extension Q angle regarding the relationship between trochlear groove and tibia because the latter can be falsely low given the laxity of the medial retinacular structure [40]. Increased Q angle is often accompanied by an inward-facing patella and/or tibia vara [16]. Abnormal patellar tracking is indicated by a positive J sign which is a lateral deviation of patella in the terminal extension [41]. The high position of the patella in patella alta can be visualized when the knee flexed to more than 70°. Asymmetry may also be noted in this case [15]. The apprehension test, in which the examiner induces lateral displacement of patella and monitors the patient’s expression of uneasiness, is commonly used to test instability with possible MPFL injuries [42].

## Imaging

Radiological studies help to identify concurrent knee injuries, osteoarthritis, and the anatomical risk factors of patellar instability stated above [43].

## Osteochondral Lesions

MRI can reveal essential information on osteochondral lesions which might be important in decision-making. The skeletal pathologies include bone contusion/edema and osteochondral fracture affecting the medial patellar facet and/or anterolateral aspect of lateral femoral condyle [6]. Intraarticular loose bodies occur in 15% of lateral patellar dislocations [44]. A concave deformity of the inferomedial patella articular surface secondary to impaction is characteristic of lateral patellar dislocation [6].

## MPFL Injury

The location of MPFL injury is categorized into femoral, midsubstance, and patella with incidence of each varying substantially among different studies [45]. MPFL injuries in the first-time patellar dislocation more commonly occur at femoral origin among adults and patellar insertion in children [28, 46]. Up to 48% of MPFL injuries occur at multiple sites [44]. Due to the > 90% pretest probability of MPFL tear in patients with prior lateral patellar dislocation, the value of MRI assessment of MPFL remains questionable [1]. It was reported that the MPFL tear at the femoral attachment tends to lead to more patellar instability and less possibility of regaining pre-injury activity level than injuries at other locations following nonsurgical treatment [45]. Similarly, the MPFL tear at VMO-MPFL overlapping region showed lower rate of instability and better subjective knee function in response to nonsurgical treatment [28]. Therefore, imaging evaluation of MPFL injury could be involved in treatment planning. MRI achieves accuracy of about 92% for both complete and partial MPFL tears; in comparison, high-frequency ultrasound yields approximately 94% of accuracy for both conditions. Interobserver agreement was ranked good for MRI and very good for high-frequency ultrasound [47].

## Patellar Height

Patella alta is an identified risk factor for patellar instability. Information on patellar height can be obtained from lateral radiographs and sagittal views of CT or MRI. On these images, numerous measurements to define the height of patella were reported including Insall-Salvati ratio, Grelsamer-Meadows ratio, Caton-Deschamps ratio, Blackburne-Peel ratio, and Biedert-Albrecht’s indexes (Table 1) [43, 48, 49]. Insall-Salvati ratio, Caton-Deschamps ratio, and Blackburne-Peel ratio all have excellent interobserver reliability [32, 50]. Caton-Deschamps ratio is becoming the preferred standard and that it renders reliable measurements at various degrees of knee flexion and in immature skeleton although the identification of patellar and tibial articular

margin can be difficult [43, 51]. Nevertheless, Caton-Deschamps index is correlated with age because the patellar ossification begins at the proximal part of the patella; also, its measurement is limited by the ambiguous identification of the patellar and tibial articular margin [51].

### Trochlear Dysplasia

Trochlear dysplasia can be classified into four types (Fig. 1) [43, 37]. The abnormal trochlear structures cause several radiographic signs on perfect lateral view of knee film that include crossing sign, supratrochlear spur, and double contour. These radiological signs associated with the Dejour classification (Table 2). Of note, it is crucial to obtain a true lateral radiograph to guarantee high diagnostic accuracy of trochlear dysplasia and superimposition of the posterior femoral condyles was a good quality criterion for the true lateral radiograph [52].

### Tuberosity to Trochlear Groove Distance

Tuberosity to trochlear groove distance (TTTG distance) quantifies the lateralization of the tibial tuberosity in relation to the trochlear groove and is measured by superimposing two cross-sectional CT or MRI images, one from the center of patellar tendon at its insertion at tibial tuberosity and one from the floor of the trochlear groove [6]. Increased TTTG is another risk factor underlying patellar instability with cutoff value greater than 20 mm being strongly associated with patellar instability [37]. The TTTG distance varies with the degree of flexion and increases with extension. TTTG distance measurements on CT or MRI showed excellent interobserver, intraobserver, and inter-method reliability [53, 54].

In younger children, the tibial tuberosity is more medialized compared to adults and the TTTG distance increases with age as a natural logarithm and plateaus at 16 years [55]. In addition, pediatric population has shallower trochlea, greater sulcus angle, and smaller patellar height ratio than adults [56].

### Patellar Tilt

Patellar tilt angle is formed by the long axis of the patella and the posterior bicondylar plane which is measured by superimposing two transverse CT images, one slicing the long axis of patella and the other going along tangential line to the posterior femoral condyles. Patellar tilt is a product of multiple anatomical properties, including extensor insufficiency, trochlear dysplasia, patella alta, insufficient MPFL, and increased TTTG distance [43].

Patellar instability is associated with a greater patellar tilt angle and a more prominent net increase of the lateral tilt by quadriceps contraction. A cutoff value of 20° for lateral patellar tilt at knee extension is suggested by previous authors [43].

Patellar tilt can also be assessed by axial radiograph taken when the knee flexed between 20° and 30°. In this method, lateral patellar tilt angle is formed by a line tangential to anterior femoral condyles and a line connecting the margins of the lateral facet of the patella [57]. Patellar instability is characterized by an angle open medially or parallel lines [57].

### Rotational Deformity

CT and MRI are reliable imaging modalities to investigate torsional limb alignment and patients with patellar dislocation are characterized by higher mean values of femoral anteversion, knee rotation, and genu valgum with no significant difference in tibial torsion in comparison to normal controls [58, 59].

## Management

### Nonsurgical Treatment

Nonoperative treatment entails initial immobilization, acute pain management, rehabilitation, and application of modalities (Appendix). The precise protocol of conservative treatment has yet to be studied extensively [6]. Immediately following first-time patellar dislocation, patients should have the affected knee immobilized at knee flexion of up to 20° for 3–6 weeks with restricted weight-bearing with or without crutches so that the ruptured ends of MPFL are approximated facilitating the healing of the MPFL. There are very few studies comparing the means of immobilization (cylinder cast, posterior splint, and removable knee brace) and immobilization duration [60]. Some evidence supports the application of posterior splint as means of immobilization because it causes lower incidence of re-dislocation than knee brace while less loss of ROM than a cylindrical cast [61]. There are several modern patellofemoral braces with varying success in stabilization. However, no high-quality clinical trial has been conducted to evaluate their effectiveness [16]. Shorter duration of immobilization could possibly increase the risk of recurrent dislocation; conversely, longer duration of immobilization tends to lead to quadriceps muscle wasting, loss of range of motion, and cartilage degeneration [60, 61]. Progressive weight-bearing and early mobilization should be initiated as tolerated.

**Table 1** Cutoff values of radiographic measurements for abnormal patella height [48, 49, 50]

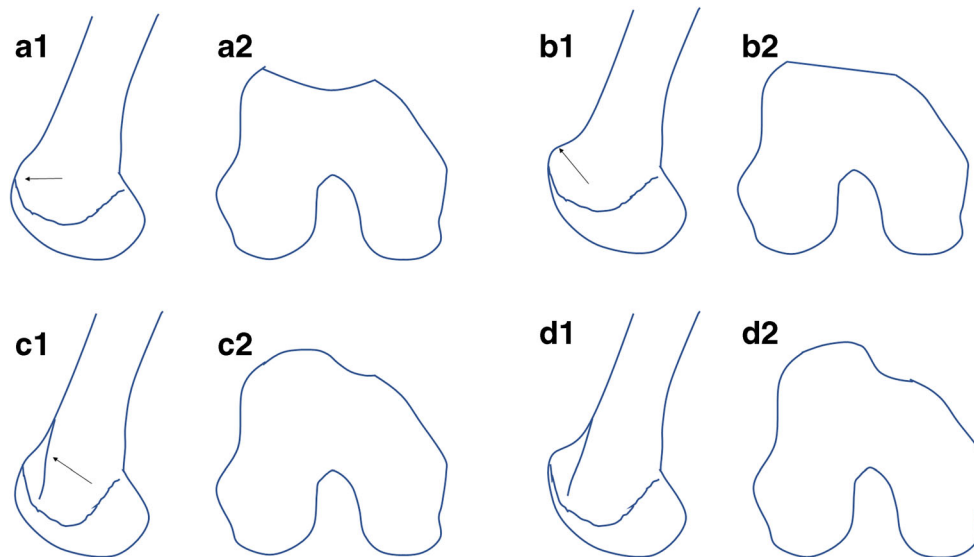
	Description	Patella alta	Patella baja
Insall-Salvati *	Length of the patellar tendon/longest diagonal distance between the lower and the upper end of the patella	> 1.20	< 0.80
Grelsamer-Meadows	Distance between the patellar tendon insertion and the lower end of the articular surface of the patella/length of articular surface of patella	> 2.00	NA
Caton-Deschamps	Distance between the peak of the anterosuperior angle of the tibial plateau and lower end of the articular surface of the patella/length of the articular surface of the patella	> 1.30	< 0.60
Blackburne-Peel ^	Vertical distance between the horizontal line projected along the tibial plateau and the lower end of the articular surface of the patella/length of the articular surface of patella	> 1.00	< 0.54
Biedert-Albrecht's	Maximal length of patella on the sagittal section with the thickest articular cartilage/length of trochlea that overlaps the patella	< 12.5%	> 50%

\*The values of Insall-Salvati measured on CT and MRI should be modified by adding 0.10 and 0.13 respectively

^The MRI measurement of Blackburne-Peel ratio is adjusted by adding 0.09

Rehabilitation focuses on restoration of normal range of motion, reinforcement of muscle strength, and promoting proprioception. The prerequisite for effective rehabilitation is sufficient control of pain and swelling. Cryotherapy can be effective in relieving pain and swelling within 48 h to 3–4 weeks post-injury [1, 16]. Soft tissue massage, ultrasound, and electrotherapy (e.g., muscle stimulation and interferential therapy) are useful for decreasing swelling

[16]. Electrical muscle stimulation in combination with isometric contraction of the quadriceps and gluteal muscles showed superior prevention of muscle atrophy [62]. ROM can be enhanced by proprioceptive neuromuscular facilitation (PNF) hold/relax technique and exercise bike [6, 16]. As tightness of anterior hip structure is often seen in this group of patients, stretching of the anterior hip can be done by “figure-of-four” position in prone [16].



**Fig. 1** Classification of dysplasia of femoral trochlea. Type A is shown on lateral view (a1) as crossing sign (arrow, intersecting of the anterior femoral condyle by Blumensaat trochlear groove line which normally intersects the anterior femoral cortex) and on cross-sectional view (a2) as shallow trochlea with preserved morphology. Type B is shown on lateral view (b1) as crossing sign and supratrochlear spur (arrow, a bony spur above the trochlea secondary to trochlear pre-eminence) and on cross-sectional view (b2) as flat or convex trochlea. Type C is shown

on lateral view (c1) as crossing sign and double contour sign (arrow, a projection of hypoplastic medial trochlear facet representing asymmetry of the height of the medial and lateral condyles) and on cross-sectional view (c2) as convex lateral facet with a hypoplastic medial facet. Type D is shown on lateral view (d1) as crossing sign, supratrochlear spur, and double contour sign and on cross-sectional view (d2) as asymmetry of the height of medial and lateral trochlear facets with cliff pattern

**Table 2** Radiographic manifestations of trochlear dysplasia

	Crossing sign	Supratrochlear spur	Double contour sign
Type A	+	–	–
Type B	+	+	–
Type C	+	–	+
Type D	+	+	+

Closed-chain exercise or weight-bearing is a superior strategy for muscle strengthening compared to open-chain exercise in that the former causes more balanced muscle activation than the latter [63, 64, 65]. Strength training can be complemented by muscle stimulation or biofeedback to enhance the efficiency of specific muscles control. Strengthening exercises should involve gluteal muscles, quadriceps, hamstring, and lateral trunk muscles. The quadriceps, particularly VMO, exerts medially directing force stabilizing patella dynamically while gluteal muscles rotate femur externally decreasing Q angle [16, 66]. The essence of quadriceps exercise is to promote the timing and intensity of VMO contraction in comparison to VL; however, it is unclear what exercise recruit VMO effectively [67]. Of note, specific VM exercise was not shown to yield clinically superior outcome than the general quadriceps exercise [68]. Taping can be used to control the patellar motion during rehabilitation by shortening the retinacular structure and providing extra restraint [69]. The additional mechanism by which taping technique improves the outcome of rehabilitation is its efficacy in activation of VMO and gluteal muscles or inhabitation of VL [69, 70, 71].

Patients with patellar dislocation often walk with the knee flexed to help stabilize the patella and thus lose the normal heel/toe gait pattern [16]. Gait training should be incorporated in the early phase of therapy program. Patients need to practice stepping, squatting, hopping, and lunging exercise [72]. Patient education after inaugural patellar dislocation should not be overlooked. Patients are to be taught the importance of whole limb stability, home exercise, and behavior modifications to incorporate in daily life to decrease the risk of patellar dislocation. Home exercise aims at muscle strengthening to improve dynamic stability [73]. Patient should stand with the front leg slightly externally rotated, get up from chair with tibia directly underneath the femur, and turn the whole body with both feet facing the same direction [16]. Lastly, the patient is advised to extend the leg in case recurrent dislocation occurs to reduce discomfort and avoid unnecessary emergency room visits.

## Surgical Treatment

Surgery is often indicated for recurrent patellar instability and aims at addressing the underlying soft tissue and bony deficits. Thorough radiological evaluation, as discussed above, is required for surgical planning. Surgical techniques are beyond the scope of this article.

## Comparison of Nonsurgical vs. Surgical Treatment

Surgery and conservative treatments for first-time patellar dislocation have been compared in numerous studies but there exist only few randomized or quasi-randomized prospective studies on this topic [74–76]. In a study by Smith, initial surgical fixation led to lower recurrence rate compared to that of nonsurgical treatment at 2 to 5 years of follow-up (RR 0.53 favoring surgery, 95% CI 0.33 to 0.87); however, the evidence for the benefit of surgery was weaker at 6 to 9 years of follow-up (RR 0.67 favoring surgery, 95% CI 0.42 to 1.08) [76]. Of note, no difference was found in the subjective rating and functional scores (Tegner activity scale, KOOS, Lysholm and Hughston visual analogue scale) between these two treatment groups with 47 to 75% of patients treated nonoperatively reporting good or excellent subjective scores [10, 28, 76]. Similar findings were reported in pediatric patients, which did not favor routine surgical repair in children [13, 77]. The operative treatment was associated with surgical complications as well as higher incidence of patellofemoral osteoarthritis [76, 78]. Therefore, nonoperative treatment is often favored for management of first-time traumatic patellar dislocation despite the minor short-term benefit of surgery [76]. However, 15 to 70% of patients may still report symptoms of instability or subluxation without frank dislocation after nonsurgical management. Furthermore, 29 to 82% may continue to have a positive apprehension test [72]. Surgery is generally indicated for recurrent patellar dislocation as well as certain first-time patellar dislocation that meets the criterion below [1, 6, 10, 30, 32].

- Loose body formation or cartilage/osteochondral fracture affecting more than 10% of the patellar joint surface or weight-bearing surface of the lateral femoral condyle [6]
- Failed conservative treatment with continued apprehension that limits function
- Major injury to the medial patellar stabilizing structures with signs of patellar subluxation or risk factors for recurrence, particularly in the patients with high level of athletic participation

## Return to Sports

Reportedly up to two thirds of the patients are able to return to sports at the previous level regardless of conservative or surgical treatment [73]. High-quality sport-specific rehabilitation programs and comprehensive test protocols should precede safe RTS. Sport-specific rehabilitation aims to facilitate transition to sports, but insufficient data is available from randomized clinical trials. In addition to strengthening, sport-specific training consists of various strategies relevant to sport activities to maximize dynamic stability and neuromuscular proprioception, such as cutting, pivoting, plyometrics, landing, one-leg stability, side ability et al. [73]. Sport-specific exercise programs for ACL reconstruction as reported before can serve as references for patellar dislocation [73].

The commonly used tools to evaluate the outcomes, including Kujala, Lysholm, Tegner, and Fulkerson, provided little insight in the patients' capacities in sports participation [79]. No definite criterion is available to decide RTS in patellar dislocation, but similar evaluations used for ACL reconstruction can be referred. The basic criteria for RTS include no pain, no effusion, no subjective or dynamic instability, full range of motion, and nearly normal muscle strength. Limb symmetry index (LSI) can be used for strength evaluation with the value greater >90% used to clear for RTS [80]. Assessment of core strength by prone plank, side plank, and single-limb exercises was reported [81]. Dynamic limb stability can be assessed in several special tests, such as single-leg squat, side hop test, drop and jump test, and Star Excursion Balance Test (SEBT) in which the patient stands on one foot and reaches the maximum distance around with the other leg [73]. Additional attention should be paid to the performance of the movement patterns related to specific sports, such as cutting, turning, sudden stops/starts, et al. [79]. Patients' performance during these tests should be recorded and analyzed by video so that modifications of rehabilitation program are made to correct residual deficits. Finally, it is required to assess athletes' confidence and mental readiness to RTS. There is no defined timeline for RTS; instead, it is a decision that is based on the fulfillment of the requirements of clinical evaluations and functional tests.

## Future Directions

The available clinical studies are weakened by the patients' heterogeneity regarding the underlying anatomical abnormalities. More randomized controlled trials with

stratification on the relevant anatomical characteristics are needed to conclude the optimal treatment based on individual's anatomopathological profile. Although conservative treatment is the mainstay for primary patellar dislocation, current literature provides very vague information on the options of nonoperative approach, which includes but not limit to temporary immobilization, rehabilitation exercise, modalities and behavior modifications. The duration of immobilization needs to be evaluated further in randomized controlled trials for different modern immobilization apparatus. Detailed documentation of rehabilitation therapy in terms of types, duration, and frequency and comprehensive assessments at pre- and post-treatment are required in future clinical trials to investigate optimal conservative strategies. The absence of pain and swelling, subjective knee scores as mentioned above, and symmetrical quadriceps strength do not translate to intact potential for RTS. To develop novel assessment tools for RTS, sport-specific maneuvers or activities are to be incorporated to ensure safety of RTS.

## Conclusion

Acute patellar dislocation often occurs as a result of trauma. Several anatomical properties were identified to predispose to patellar instability, including patella alta, dysplasia of femoral trochlear, and malalignment of lower limb. The diagnosis is often straightforward given a trauma history, acute knee pain, swelling, sensation of patella popping out, and positive apprehension test. Conservative treatment is mainstay for first-time patellar dislocation while surgery is indicated for recurrent dislocation and those who failed in conservative treatment or are complicated by osteochondral injury. Comprehensive radiological assessment is required for surgical planning and useful in prognosis. RTS requires resolution of pain and swelling, full ROM, and near symmetrical muscle strength as well as competence in fulfilling sports-related activities of same movement patterns and intensity.

## Compliance with Ethical Standards

**Conflict of Interest** The authors declare that they have no competing interests.

**Human and Animal Rights and Informed Consent** This article does not contain any studies with human or animal subjects performed by any of the authors.

## Appendix

**Table 3** standard rehabilitation protocol following a patellar dislocation used at Vanderbilt.

### General rehab guidelines:

Control pain and edema  
Normal ROM, proprioception, strength  
Return to normal ADLs/sports

### Phase I:

#### Goals:

Full ROM  
Control pain  
Decrease edema  
Instruct in HEP

#### Suggested exercises:

Quad sets  
Straight leg raises  
Heel slides  
Hip exercises for flexion, extension, abduction, and adduction  
Stretches: quadriceps, hamstrings, glutes, abductors, adductors, IT Band, and piriformis

#### Modalities as needed

### Phase II

#### Goals:

Increase strength  
Increase proprioception  
Increase flexibility  
Decrease pain  
Maintain ROM

#### Suggested exercises:

Closed-chain strengthening: leg press, TKEs, step-ups, wall sits, and hamstring curls

#### Abductor and adductor machines

#### Proprioceptive exercises

#### Continue with cardiovascular

#### Lower extremity stretches

#### Continue with modalities as needed

### Phase III

#### Goals:

Return to normal ADLs and/or sports without pain or limitation  
Maintain flexibility  
Independence in HEP

#### Suggested exercises:

Continue to increase strength and flexibility  
Sport-specific exercises where indicated  
Cardio progression where indicated  
Independence demonstrated in HEP

## References

- Clark D, Metcalfe A, Wogan C, Mandalia V, Eldridge J. Adolescent patellar instability: current concepts review. *Bone Joint J.* 2017;99-b(2):159–70.
- Conchie H, Clark D, Metcalfe A, Eldridge J, Whitehouse M. Adolescent knee pain and patellar dislocations are associated with patellofemoral osteoarthritis in adulthood: a case control study. *Knee.* 2016;23(4):708–11.
- Salonen EE, Magga T, Sillanpaa PJ, Kiekara T, Maenpaa H, Mattila VM. Traumatic patellar dislocation and cartilage injury: a follow-up study of long-term cartilage deterioration. *Am J Sports Med.* 2017;45(6):1376–82.
- Batra S, Arora S. Habitual dislocation of patella: a review. *J Clin Orthop Traumatol.* 2014;5(4):245–51.
- Stefancin JJ, Parker RD. First-time traumatic patellar dislocation: a systematic review. *Clin Orthop Relat Res.* 2007;455:93–101.
- Duthon VB. Acute traumatic patellar dislocation. *Orthop Traumatol Surg Res.* 2015;101(1 Suppl):S59–67.
- Fithian DC, Paxton EW, Stone ML, Silva P, Davis DK, Elias DA, et al. Epidemiology and natural history of acute patellar dislocation. *Am J Sports Med.* 2004;32(5):1114–21.
- Lewallen L, McIntosh A, Dahm D. First-time patellofemoral dislocation: risk factors for recurrent instability. *J Knee Surg.* 2015;28(4):303–9.
- Sillanpaa P, Mattila VM, Iivonen T, Visuri T, Pihlajamaki H. Incidence and risk factors of acute traumatic primary patellar dislocation. *Med Sci Sports Exerc.* 2008;40(4):606–11.
- Panni AS, Vasso M, Cerciello S. Acute patellar dislocation. What to do? *Knee Surg Sports Traumatol Arthrosc.* 2013;21(2):275–8.
- Weber AE, Nathani A, Dines JS, Allen AA, Shubin-Stein BE, Arendt EA, et al. An algorithmic approach to the management of recurrent lateral patellar dislocation. *J Bone Joint Surg Am.* 2016;98(5):417–27.
- Buchner M, Baudendistel B, Sabo D, Schmitt H. Acute traumatic primary patellar dislocation: long-term results comparing conservative and surgical treatment. *Clin J Sport Med.* 2005;15(2):62–6.
- Palmu S, Kallio PE, Donell ST, Helenius I, Nietosvaara Y. Acute patellar dislocation in children and adolescents: a randomized clinical trial. *J Bone Joint Surg Am.* 2008;90(3):463–70.
- Petri M, von Falck C, Broese M, Liodakis E, Balcarek P, Niemeyer P, et al. Influence of rupture patterns of the medial patellofemoral ligament (MPFL) on the outcome after operative treatment of traumatic patellar dislocation. *Knee Surg Sports Traumatol Arthrosc.* 2013;21(3):683–9.
- Arendt EA, Dahm DL, Dejour D, Fithian DC. Patellofemoral joint: from instability to arthritis. *Instr Course Lect.* 2014;63:355–68.
- McConnell J. Rehabilitation and nonoperative treatment of patellar instability. *Sports Med Arthrosc Rev.* 2007;15(2):95–104.
- Ahmad CS, Stein BE, Matuz D, Henry JH. Immediate surgical repair of the medial patellar stabilizers for acute patellar dislocation. A review of eight cases. *Am J Sports Med.* 2000;28(6):804–10.
- Askenberger M, Janarv PM, Finnbogason T, Arendt EA. Morphology and anatomic patellar instability risk factors in first-time traumatic lateral patellar dislocations: a prospective magnetic resonance imaging study in skeletally immature children. *Am J Sports Med.* 2017;45(1):50–8.
- Insall J, Goldberg V, Salvati E. Recurrent dislocation and the high-riding patella. *Clin Orthop Relat Res.* 1972;88:67–9.
- Steensen RN, Bentley JC, Trinh TQ, Backes JR, Wiltfong RE. The prevalence and combined prevalences of anatomic factors associated with recurrent patellar dislocation: a magnetic resonance imaging study. *Am J Sports Med.* 2015;43(4):921–7.
- Senavongse W, Amis AA. The effects of articular, retinacular, or muscular deficiencies on patellofemoral joint stability: a



- biomechanical study in vitro. *J Bone Joint Surg Br* Vol. 2005;87(4): 577–82.
22. Christoforakis J, Bull AM, Strachan RK, Shymkiw R, Senavongse W, Amis AA. Effects of lateral retinacular release on the lateral stability of the patella. *Knee Surg Sports Traumatol Arthrosc*. 2006;14(3):273–7.
  23. Tuxoe JJ, Teir M, Winge S, Nielsen PL. The medial patellofemoral ligament: a dissection study. *Knee Surg Sports Traumatol Arthrosc*. 2002;10(3):138–40.
  24. Amis AA, Firer P, Mountney J, Senavongse W, Thomas NP. Anatomy and biomechanics of the medial patellofemoral ligament. *Knee*. 2003;10(3):215–20.
  25. Diederichs G, Issever AS, Scheffler S. MR imaging of patellar instability: injury patterns and assessment of risk factors. *Radiographics*. 2010;30(4):961–81.
  26. Panni AS, Alam M, Cerciello S, Vasso M, Maffulli N. Medial patellofemoral ligament reconstruction with a divergent patellar transverse 2-tunnel technique. *Am J Sports Med*. 2011;39(12): 2647–55.
  27. Desio SM, Burks RT, Bachus KN. Soft tissue restraints to lateral patellar translation in the human knee. *Am J Sports Med*. 1998;26(1):59–65.
  28. Kang HJ, Wang F, Chen BC, Zhang YZ, Ma L. Non-surgical treatment for acute patellar dislocation with special emphasis on the MPFL injury patterns. *Knee Surg Sports Traumatol Arthrosc*. 2013;21(2):325–31.
  29. Felus J, Kowalczyk B. Age-related differences in medial patellofemoral ligament injury patterns in traumatic patellar dislocation: case series of 50 surgically treated children and adolescents. *Am J Sports Med*. 2012;40(10):2357–64.
  30. Sillanpaa PJ, Maenpaa HM. First-time patellar dislocation: surgery or conservative treatment? *Sports Med Arthrosc Rev*. 2012;20(3): 128–35.
  31. Reider B, Marshall JL, Koslin B, Ring B, Girgis FG. The anterior aspect of the knee joint. *J Bone Joint Surg Am*. 1981;63(3):351–6.
  32. Koh JL, Stewart C. Patellar instability. *Orthop Clin N Am*. 2015;46(1):147–57.
  33. Fulkerson JP, Gossling HR. Anatomy of the knee joint lateral retinaculum. *Clin Orthop Relat Res*. 1980;153:183–8.
  34. Goh JC, Lee PY, Bose K. A cadaver study of the function of the oblique part of vastus medialis. *J Bone Joint Surg Br* Vol. 1995;77(2):225–31.
  35. Farahmand F, Senavongse W, Amis AA. Quantitative study of the quadriceps muscles and trochlear groove geometry related to instability of the patellofemoral joint. *J Orthop Res*. 1998;16(1):136–43.
  36. Wong YM. Recording the vastii muscle onset timing as a diagnostic parameter for patellofemoral pain syndrome: fact or fad? *Phys Ther Sport*. 2009;10(2):71–4.
  37. Dejour H, Walch G, Nove-Josserand L, Guier C. Factors of patellar instability: an anatomic radiographic study. *Knee Surg Sports Traumatol Arthrosc*. 1994;2(1):19–26.
  38. Han Y, Duan D, Zhao K, Wang X, Ouyang L, Liu G. Investigation of the relationship between flatfoot and patellar subluxation in adolescents. *J Foot Ankle Surg*. 2017;56(1):15–8.
  39. Nguyen A-D, Boling MC, Levine B, Shultz SJ. Relationships between lower extremity alignment and the quadriceps angle. *Clin J Sport Med*. 2009;19(3):201–6.
  40. Cooney AD, Kazi Z, Caplan N, Newby M, St Clair Gibson A, Kader DF. The relationship between quadriceps angle and tibial tuberosity-trochlear groove distance in patients with patellar instability. *Knee Surg Sports Traumatol Arthrosc*. 2012;20(12):2399–404.
  41. Sheehan FT, Derasari A, Fine KM, Brindle TJ, Alter KE. Q-angle and J-sign: indicative of maltracking subgroups in patellofemoral pain. *Clin Orthop Relat Res*. 2010;468(1):266–75.
  42. Tompkins MA, Arendt EA. Patellar instability factors in isolated medial patellofemoral ligament reconstructions—what does the literature tell us? A systematic review. *Am J Sports Med*. 2015;43(9): 2318–27.
  43. Dietrich TJ, Fucentese SF, Pfirrmann CW. Imaging of individual anatomical risk factors for patellar instability. *Semin Musculoskelet Radiol*. 2016;20(1):65–73.
  44. Elias DA, White LM, Fithian DC. Acute lateral patellar dislocation at MR imaging: injury patterns of medial patellar soft-tissue restraints and osteochondral injuries of the inferomedial patella. *Radiology*. 2002;225(3):736–43.
  45. Sillanpaa PJ, Peltola E, Mattila VM, Kiuru M, Visuri T, Pihlajamaki H. Femoral avulsion of the medial patellofemoral ligament after primary traumatic patellar dislocation predicts subsequent instability in men: a mean 7-year nonoperative follow-up study. *Am J Sports Med*. 2009;37(8):1513–21.
  46. Askenberger M, Arendt EA, Ekstrom W, Voss U, Finnbogason T, Janarv PM. Medial patellofemoral ligament injuries in children with first-time lateral patellar dislocations: a magnetic resonance imaging and arthroscopic study. *Am J Sports Med*. 2016;44(1):152–8.
  47. Zhang GY, Zheng L, Ding HY, Li EM, Sun BS, Shi H. Evaluation of medial patellofemoral ligament tears after acute lateral patellar dislocation: comparison of high-frequency ultrasound and MR. *Eur Radiol*. 2015;25(1):274–81.
  48. Biedert RM, Albrecht S. The patellotrochlear index: a new index for assessing patellar height. *Knee Surg Sports Traumatol Arthrosc*. 2006;14(8):707–12.
  49. Nizic D, Pervan M, Kovacevic B. A new reference line in diagnosing a high-riding patella on routine digital lateral radiographs of the knee. *Skelet Radiol*. 2014;43(8):1129–37.
  50. Lee PP, Chalian M, Carrino JA, Eng J, Chhabra A. Multimodality correlations of patellar height measurement on X-ray, CT, and MRI. *Skelet Radiol*. 2012;41(10):1309–14.
  51. Thevenin-Lemoine C, Ferrand M, Courvoisier A, Damsin JP, Ducou le Pointe H, Vialle R. Is the Caton-Deschamps index a valuable ratio to investigate patellar height in children? *J Bone Joint Surg Am*. 2011;93(8):e35.
  52. Koeter S, Bongers EM, de Rooij J, van Kampen A. Minimal rotation aberrations cause radiographic misdiagnosis of trochlear dysplasia. *Knee Surg Sports Traumatol Arthrosc*. 2006;14(8):713–7.
  53. Skelley N, Friedman M, McGinnis M, Smith C, Hillen T, Matava M. Inter- and intraobserver reliability in the MRI measurement of the tibial tubercle-trochlear groove distance and trochlea dysplasia. *Am J Sports Med*. 2015;43(4):873–8.
  54. Ho CP, James EW, Surowiec RK, Gatlin CC, Ellman MB, Cram TR, et al. Systematic technique-dependent differences in CT versus MRI measurement of the tibial tubercle-trochlear groove distance. *Am J Sports Med*. 2015;43(3):675–82.
  55. Dickens AJ, Morrell NT, Doering A, Tandberg D, Treme G. Tibial tubercle-trochlear groove distance: defining normal in a pediatric population. *J Bone Joint Surg Am*. 2014;96(4):318–24.
  56. Mundy A, Ravindra A, Yang J, Adler BH, Klingele KE. Standardization of patellofemoral morphology in the pediatric knee. *Pediatr Radiol*. 2016;46(2):255–62.
  57. Laurin CA, Levesque HP, Dussault R, Labelle H, Peides JP. The abnormal lateral patellofemoral angle: a diagnostic roentgenographic sign of recurrent patellar subluxation. *J Bone Joint Surg Am*. 1978;60(1):55–60.
  58. Diederichs G, Kohlitz T, Komaropoulos E, Heller MO, Vollnberg B, Scheffler S. Magnetic resonance imaging analysis of rotational alignment in patients with patellar dislocations. *Am J Sports Med*. 2013;41(1):51–7.
  59. Hinton RY, Sharma KM. Acute and recurrent patellar instability in the young athlete. *Orthop Clin N Am*. 2003;34(3):385–96.

60. van Gemert JP, de Vree LM, Hessels RA, Gaakeer MI. Patellar dislocation: cylinder cast, splint or brace? An evidence-based review of the literature. *Int J Emerg Med.* 2012;5(1):45.
61. Maenpaa H, Lehto MU. Patellar dislocation. The long-term results of nonoperative management in 100 patients. *Am J Sports Med.* 1997;25(2):213–7.
62. Fujita N, Murakami S, Arakawa T, Miki A, Fujino H. The combined effect of electrical stimulation and resistance isometric contraction on muscle atrophy in rat tibialis anterior muscle. *Bosn J Basic Med Sci.* 2011;11(2):74–9.
63. Stensdotter AK, Hodges PW, Mellor R, Sundelin G, Hager-Ross C. Quadriceps activation in closed and in open kinetic chain exercise. *Med Sci Sports Exerc.* 2003;35(12):2043–7.
64. Earl JE, Hoch AZ. A proximal strengthening program improves pain, function, and biomechanics in women with patellofemoral pain syndrome. *Am J Sports Med.* 2011;39(1):154–63.
65. Hott A, Liavaag S, Juel NG, Brox JI. Study protocol: a randomised controlled trial comparing the long term effects of isolated hip strengthening, quadriceps-based training and free physical activity for patellofemoral pain syndrome (anterior knee pain). *BMC Musculoskelet Disord.* 2015;16:40.
66. Dolak KL, Silkman C, Medina McKeon J, Hosey RG, Lattermann C, Uhl TL. Hip strengthening prior to functional exercises reduces pain sooner than quadriceps strengthening in females with patellofemoral pain syndrome: a randomized clinical trial. *J Orthop Sports Phys Ther.* 2011;41(8):560–70.
67. Smith TO, Chester R, Clark A, Donell ST, Stephenson R. A national survey of the physiotherapy management of patients following first-time patellar dislocation. *Physiotherapy.* 2011;97(4):327–38.
68. Smith TO, Chester R, Cross J, Hunt N, Clark A, Donell ST. Rehabilitation following first-time patellar dislocation: a randomised controlled trial of purported vastus medialis obliquus muscle versus general quadriceps strengthening exercises. *Knee.* 2015;22(4):313–20.
69. Cowan SM, Hodges PW, Crossley KM, Bennell KL. Patellar taping does not change the amplitude of electromyographic activity of the vasti in a stair stepping task. *Br J Sports Med.* 2006;40(1):30–4.
70. Kilbreath SL, Perkins S, Crosbie J, McConnell J. Gluteal taping improves hip extension during stance phase of walking following stroke. *Aust J Physiother.* 2006;52(1):53–6.
71. McCarthy Persson U, Fleming HF, Caulfield B. The effect of a vastus lateralis tape on muscle activity during stair climbing. *Man Ther.* 2009;14(3):330–7.
72. Smith TO, Davies L, Chester R, Clark A, Donell ST. Clinical outcomes of rehabilitation for patients following lateral patellar dislocation: a systematic review. *Physiotherapy.* 2010;96(4):269–81.
73. Menetrey J, Putman S, Gard S. Return to sport after patellar dislocation or following surgery for patellofemoral instability. *Knee Surg Sports Traumatol Arthrosc.* 2014;22(10):2320–6.
74. Sillanpaa PJ, Mattila VM, Maenpaa H, Kiuru M, Visuri T, Pihlajamaki H. Treatment with and without initial stabilizing surgery for primary traumatic patellar dislocation. A prospective randomized study. *J Bone Joint Surg Am.* 2009;91(2):263–73.
75. Nikku R, Nietosvaara Y, Aalto K, Kallio PE. Operative treatment of primary patellar dislocation does not improve medium-term outcome: a 7-year follow-up report and risk analysis of 127 randomized patients. *Acta Orthop.* 2005;76(5):699–704.
76. Smith TO, Donell S, Song F, Hing CB. Surgical versus non-surgical interventions for treating patellar dislocation. *Cochrane Database Syst Rev.* 2015;2:Cd008106.
77. Nwachukwu BU, So C, Schairer WW, Green DW, Dodwell ER. Surgical versus conservative management of acute patellar dislocation in children and adolescents: a systematic review. *Knee Surg Sports Traumatol Arthrosc.* 2016;24(3):760–7.
78. Smith TO, Song F, Donell ST, Hing CB. Operative versus non-operative management of patellar dislocation. A meta-analysis. *Knee Surg Sports Traumatol Arthrosc.* 2011;19(6):988–98.
79. Fisher B, Nyland J, Brand E, Curtin B. Medial patellofemoral ligament reconstruction for recurrent patellar dislocation: a systematic review including rehabilitation and return-to-sports efficacy. *Arthroscopy.* 2010;26(10):1384–94.
80. Bizzini M, Hancock D, Impellizzeri F. Suggestions from the field for return to sports participation following anterior cruciate ligament reconstruction: soccer. *J Orthop Sports Phys Ther.* 2012;42(4):304–12.
81. Monson J, Arendt EA. Rehabilitative protocols for select patellofemoral procedures and nonoperative management schemes. *Sports Med Arthrosc Rev.* 2012;20(3):136–44.