

# Stamm Gastrostomy

Gady Barutwanayo, Richard Davis

## Introduction:

Gastrostomy is used for patients with functional or obstructing lesions of the upper aerodigestive tract or esophagus. Indications include obstructing tumors, severe infections, and inability to feed due to neurologic lesions or other severe illness. Administering feeds directly to the stomach makes use of its natural reservoir function, allowing feeds to be administered in bolus fashion several times per day.

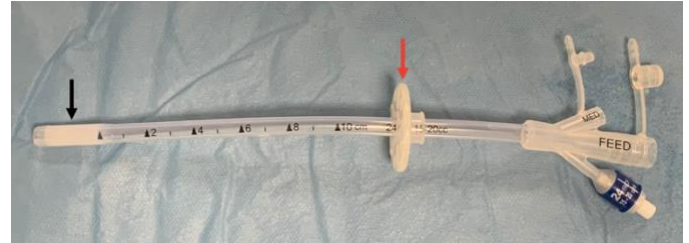
Gastrostomy is contraindicated in patients with obstruction of the pylorus or duodenum, or functional problems downstream such as anastomotic leakage in the small intestine. Such patients are better served by a jejunostomy. However jejunostomy is much more difficult to manage, requiring continuous rather than bolus infusion, and being more vulnerable to blockage of the smaller-caliber tube.

Percutaneous endoscopic gastrostomy (PEG) using a flexible fiberoptic gastroscope avoids laparotomy for tube placement, but requires specialized equipment as well as a non-obstructed upper gastrointestinal tract to allow passage of the scope. This procedure is discussed in a separate chapter.

Both open and percutaneous gastrostomy make a hole in the stomach. After 5-7 days (but more reliably after 2 weeks) a tract is formed between the skin and the stomach. After that time, the tube can be changed if needed, or simply replaced if it falls out. If the tube becomes dislodged before 5-7 days post surgery, a repeat laparotomy may be required. In case of dislodgement of a recently placed tube, after the tube is returned to place, a contrast study should be used to confirm its position in the stomach. If the tube passes easily into the stomach when replaced and the operation was more than 2 weeks previous, a contrast study is not necessary.

A variety of tubes can be used in resource-limited settings, including Foley catheters, Malecot catheters, and dedicated gastrostomy tubes. Foley catheters are very common and are often used for gastrostomy, however the balloon must not be allowed to migrate across the pylorus or it will cause bowel obstruction. The problem with using a foley

catheter for a gastrostomy is that it will forever be prone to either falling out if the balloon is not inflated, or migrating to the gastric outlet and causing obstruction if the balloon is inflated. The solution to both problems is to make sure it is well secured to the abdominal skin.



Commercially available gastrostomy tubes have a balloon at the tip (Black Arrow) and a flange (Red Arrow) that can be slid along the tube. After placement of the tube, the flange is slid distally so that the gastric and abdominal wall are squeezed gently together by the inflated balloon on the inside, and the flange on the outside.

In general, the steps of open gastrostomy placement are:

- Mini-laparotomy
- Selection of the tube placement site
- Mobilization of the stomach into the surgical field
- Placement of two purse-string sutures
- Passage of the gastrostomy tube through the abdominal wall
- Gastrostomy and passage of the tube into the stomach lumen
- Closure of the purse-string sutures
- Securing the anterior stomach to the abdominal wall
- Fascial and skin closure.

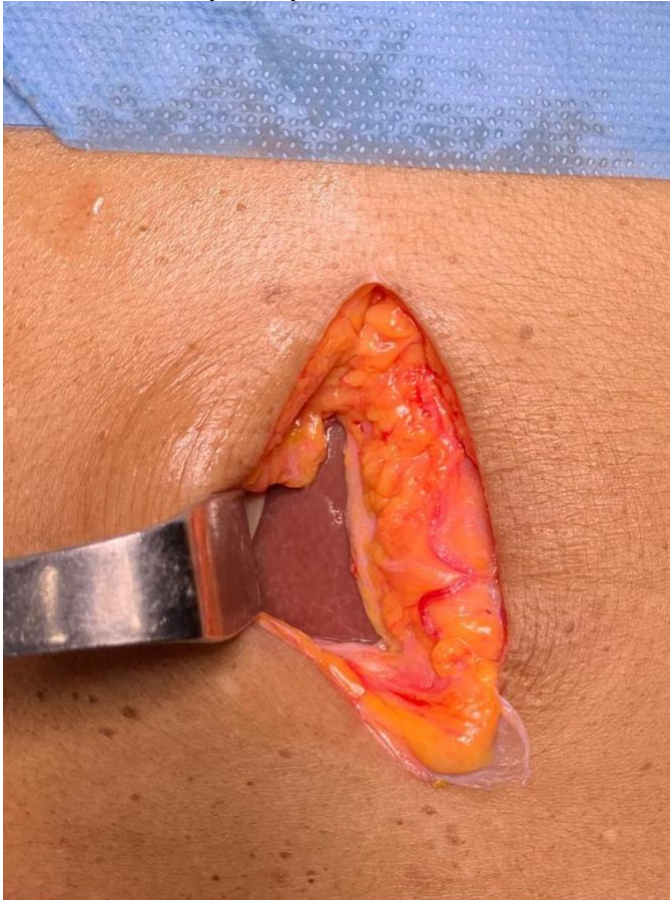## Steps:

1. The clinical status of the patient as indication for gastrostomy tube placement is quite enough most of the time, but in case of esophageal obstructive tumor, an OGD should be done if not done previously to rule out the possibility of a PEG tube placement vs open.
2. General anesthesia is preferred if there is no contraindication. If the generation condition of the patient puts the patient at high risk for general anesthesia, the procedure can be done under light sedation and local anesthesia.

## Stamm Gastrostomy

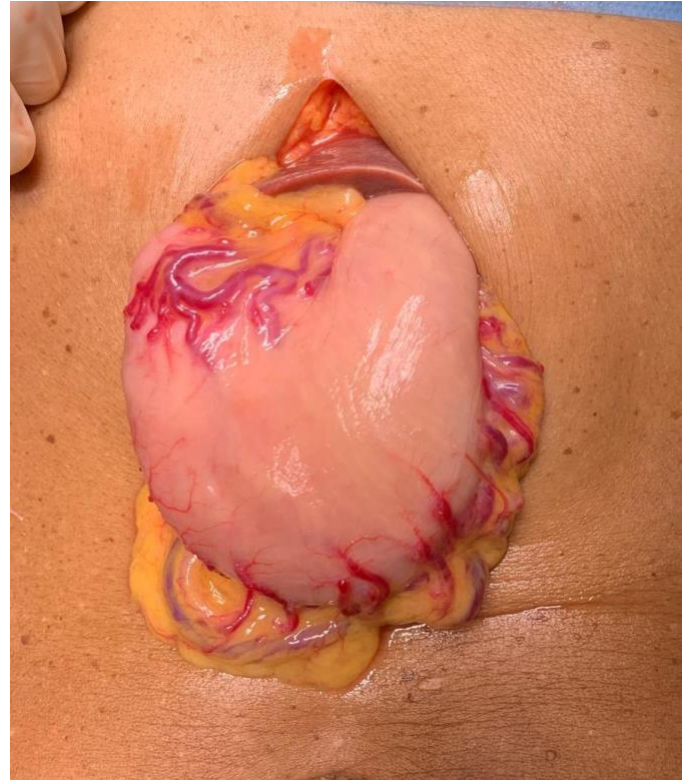
Gady Barutwanayo, Richard Davis

- The patient lies supine, prepared and draped from the inframammary line to the umbilicus. The surgeon stands on the patient's right side.
- A 6cm long supra-umbilical midline incision is made at the epigastrium region, about 4cm below the xiphoid process.



An incision about 6cm in length is made beginning about 4cm below the tip of the xiphoid process. The left lobe of the liver is usually immediately below this location and the stomach just to the patient's left.

- The stomach is retrieved and an avascular area is identified on its anterior aspect at the greater curvature where the gastrostomy tube will be inserted. Make sure that this point will be easily mobilized without tension when anchoring the stomach to the abdominal wall.



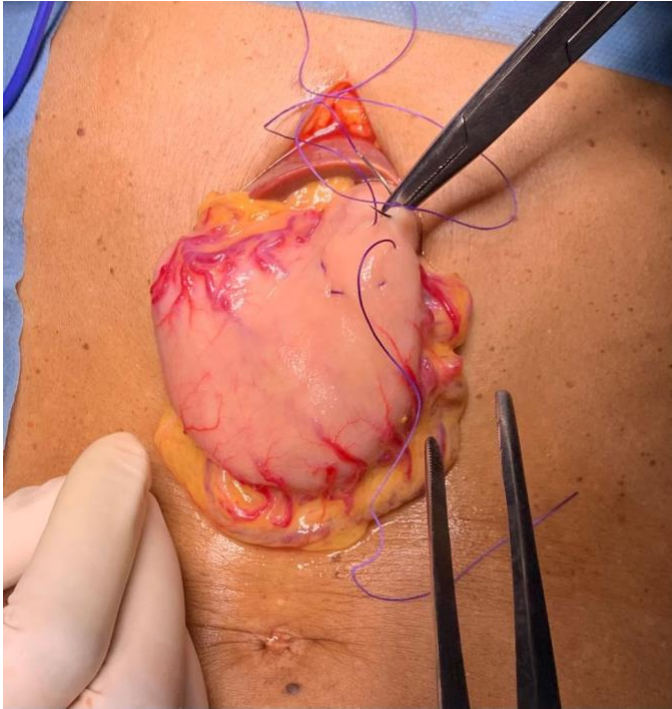
The stomach is usually freely mobile and the distal body can reach the anterior abdominal wall easily. Once the location for tube placement has been chosen, this part of the stomach is delivered through the abdominal incision. If intra-abdominal adhesions prevent this mobilization or delivery, the incision can be extended for adhesiolysis.

- Two purse string sutures are done. The outer one remains with the needle which will be used to anchor the stomach to the abdominal wall. This suture starts and ends on the patient's left. When the stomach is anchored to the anterior abdominal wall, the left-most anchoring stitch is the most difficult to place. Leaving the needle on after the purse string is tied allows this suture to be directly placed into the abdominal wall.

## Stamm Gastrostomy

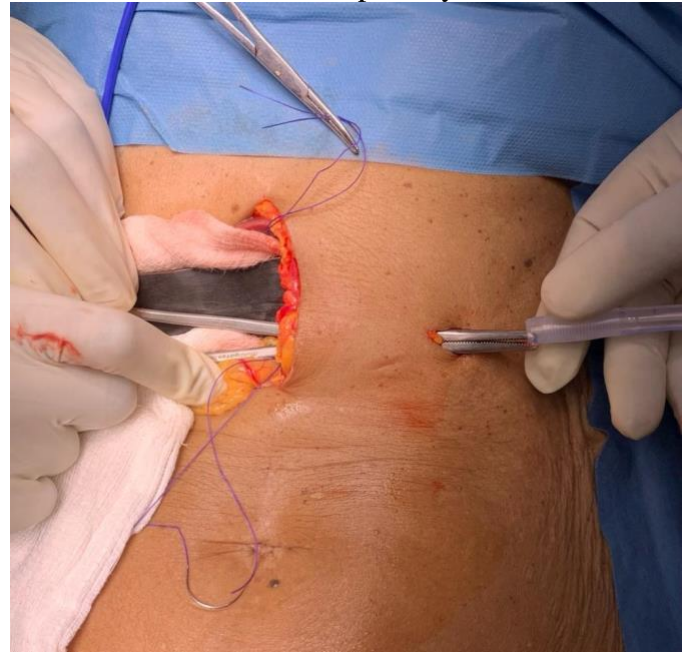
Gady Barutwanayo, Richard Davis

*can be used to anchor the stomach to the abdominal wall after the tube has been placed.*

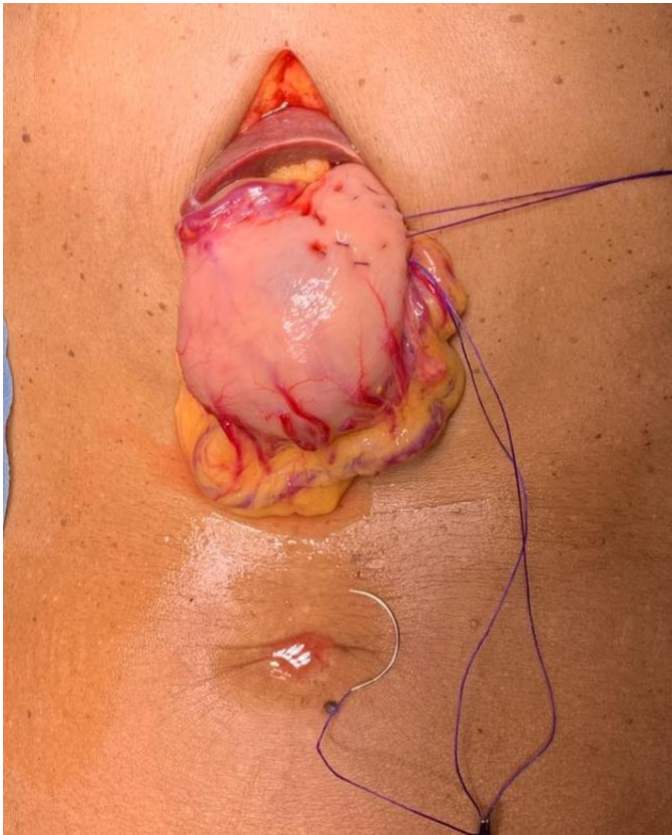

*The inner purse string is placed first, the location it starts and ends does not matter.*

7. A small incision is made to the left of the laparotomy site, in the area where the stomach was found to reach without tension. A Kelley forceps is passed from the abdominal cavity, through the abdominal wall and then through the incision. The gastrostomy tube must be grasped on the very end to avoid tear of the balloon. The balloon of the tube must be tested before insertion to confirm its patency.



*Abdominal wall stab incision is made in the area where the tube will pass. A Kelley or similar forceps is then passed from inside the abdominal wall and used to grasp the tube. Care must be taken to avoid damage to the balloon.*

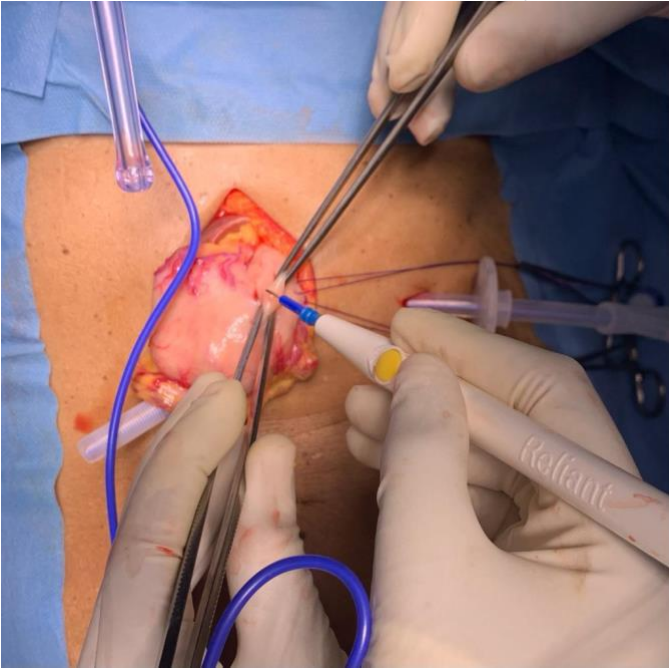


*The outer purse string is then placed, starting and ending on the patient's left. The needle is not cut off, so that this suture*

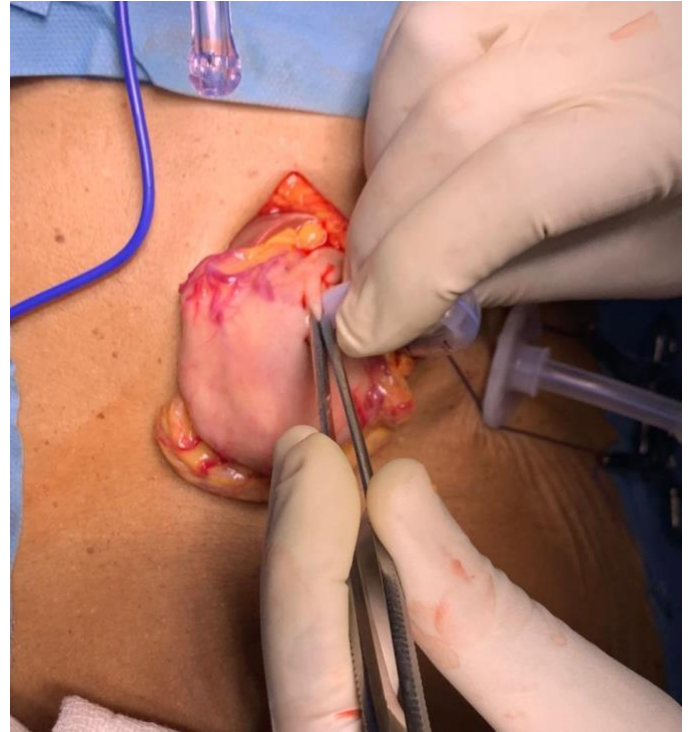
8. A gastrotomy is made within the innermost purse string suture using an electrocautery and extended using an artery forceps.

## Stamm Gastrostomy

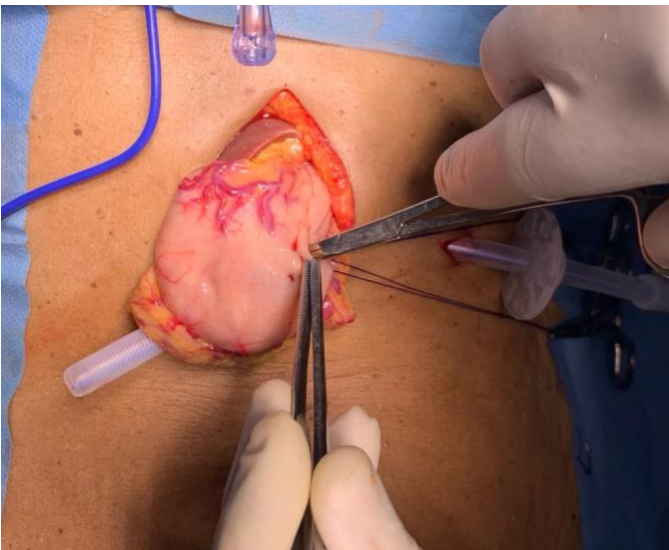
Gady Barutwanayo, Richard Davis



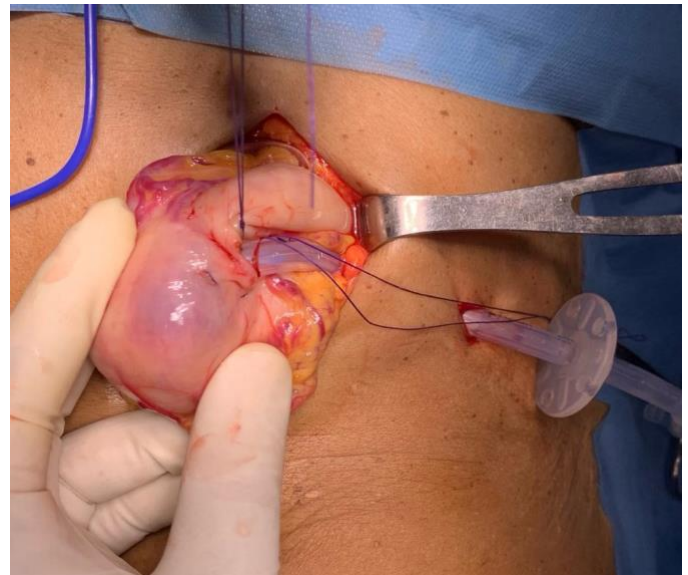
The serosa and subserosal muscular layers are incised with electrocautery, in the center of the inner purse string.



Grasping the side of the gastrotomy gently with forceps, the surgeon passes the tube into the lumen of the stomach.



A sharp hemostat, rather than continued electrocautery, is used to complete entry into the stomach. The operator may feel a “pop” as the mucosa and submucosa are breached.



The balloon is inflated and the inner purse string is tied.

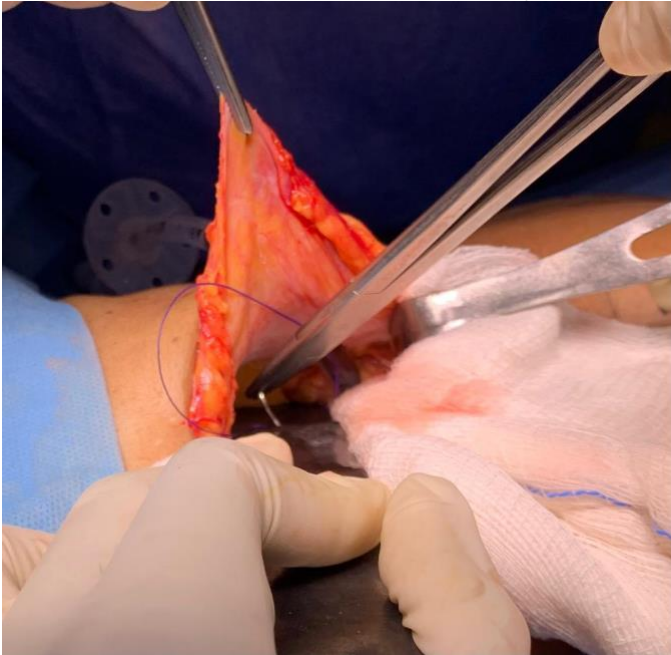
9. The gastrostomy tube is then inserted inside the stomach, the balloon is inflated and inner purse string suture is tied.

10. The outer purse string is tied while gentle inward pressure is applied to the tube to “bury” the inner purse string. The suture is not cut.

11. The stomach is attached to the abdominal wall using the suture of the outer purse string, just to the left of where the tube enters the abdominal wall.

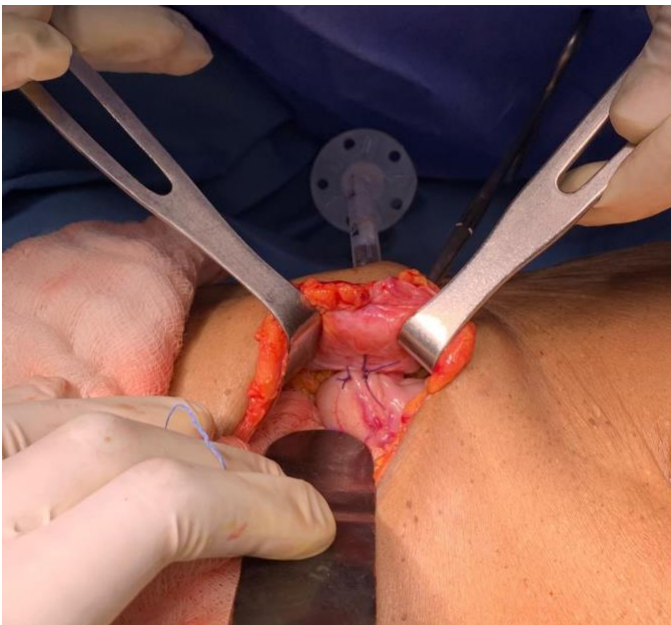
## Stamm Gastrostomy

Gady Barutwanayo, Richard Davis



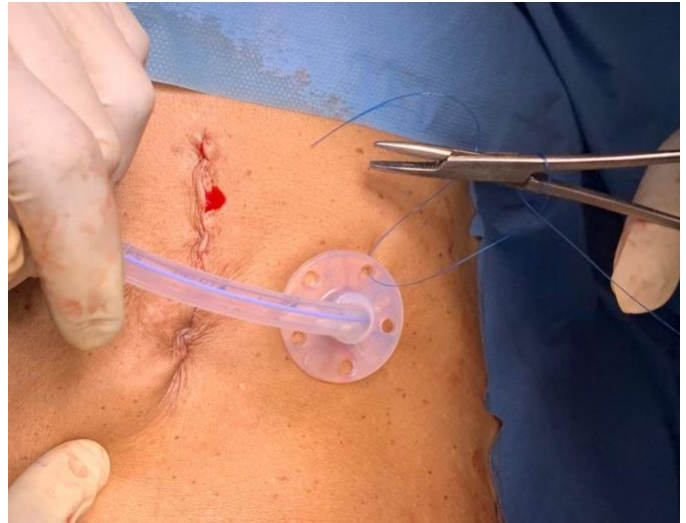
The anchoring stitch that is lateral to the tube is the most difficult one to see and place. The suture from the outer purse string, with the needle still attached, is used. Note that in this picture, the clamp in the top of the picture is attached to the peritoneum, providing some visualization. If it were grasping the fascia, retraction would be more effective.

12. Two or three more stitches can be applied circumferentially to complete the attachment of the stomach to the abdominal wall.



These sutures are closer to the surgeon and easier to visualize with proper retraction.

13. The flange is slid downwards until it is snug but not overly tight on the abdominal skin. It is then secured to the skin.



The flange is usually adherent to the tube and it remains in place after it is pulled down snug to the abdominal wall. If using a Foley or Malecot catheter, secure the catheter to the skin directly, taking care not to tie it too tightly and occlude it.

14. Tube feeds can be begun within a few hours after the surgery, starting with small boluses and checking the residual amount in the stomach before every feed. If the patient has nausea or vomiting, the tube can be opened and connected to a drainage bag. Before discharge, the patient or family are counseled on management of the tube including cleaning the skin, flushing with water after administering feeds, and applying barrier cream if there is leakage and irritation.

### Pitfalls

- Early dislodgement of the tube may result in a hole in the stomach that drains freely into the peritoneal cavity. The surgeon must be aware of this possibility. It is generally acceptable for an experienced hand to try to replace any dislodged tube, but a contrast study is mandatory before using a tube that has fallen out and been replaced within two weeks of its placement.
- Foley catheter balloons can migrate across the pylorus and cause gastric outlet obstruction. It is tempting to inflate the balloon and rely on a suture to prevent this occurrence, but inevitably the suture will become dislodged. Conversely, not inflating the balloon makes the tube more

## Stamm Gastrostomy

Gady Barutwanayo, Richard Davis

prone to dislodgment. For this reason, Foley catheters should be avoided for gastrostomy if any other option at all is available.

forget to address nutritional status carefully before attempting this operation (See Chapter, Nutritional Assessment.)

- Commercially available open and percutaneous gastrostomy tubes include a flange that is cinched down on the skin to prevent leakage and secure the tube. If this flange is too loose, leakage will occur. If it is too tight, necrosis of the skin or even of the abdominal wall can occur. Our practice is to cinch it down until it is tight, then release it 1cm. Full thickness necrosis of the abdominal wall leads to gastrocutaneous fistula. This is a devastating complication that is best avoided by erring on the side of “too loose” rather than “too tight.”
- All gastrostomy tubes will allow some degree of leakage around the tube. Proper care of the tube includes keeping the skin clean including under the flange, assuring proper tightness of the flange, and protecting the skin with zinc barrier cream if irritation starts to occur. Most skin complications will occur after discharge, so the patient and family should be taught proper care of the tube. Other solutions to persistent leakage around the tube include changing the tube to a larger size, increasing frequency of feeds while decreasing volume, and assessing gastric emptying function and treating with prokinetics if appropriate. In extreme cases the patient may need closure and placement of the tube in another part of the stomach, or conversion to Janeway gastrostomy.
- When gastrostomy tubes are no longer needed and removed, the tract usually closes spontaneously within 2-5 days at most. When it does not close, a gastrocutaneous fistula is present. The most common causes of this are poor nutrition or distal obstruction. This complication can make nutrition difficult, as the patient will often voluntarily restrict feeds to decrease fistula output, leading to a “vicious cycle” in an already malnourished patient. If measures to improve the patient’s nutrition do not lead to fistula closure, laparotomy and closure of the fistula may be required. This is a difficult situation. Assess for gastric emptying pathology or gastric outlet obstruction. Don’t

Gady Barutwanayo, MBBS  
AIC Kijabe Hospital  
Kenya

Richard Davis, MD FACS FCS(ECSA)  
AIC Kijabe Hospital  
Kenya

February 2022

