

# Partial “Wedge” Gastrectomy

Richard Davis

## Introduction:

The partial gastrectomy, also known as wedge gastrectomy, is useful for gastric tumors that require only limited resection. Most gastric tumors are adenocarcinomas and require margins of 5cm; formal gastric resections (Distal, Subtotal or Total gastrectomy) are described elsewhere in this atlas.

Situations that demand only a localized resection are rarer. These include Gastrointestinal Stromal tumors, Neuroendocrine tumors (formerly called “Carcinoid,”) and gastric lymphomas that have perforated during chemotherapy. In such cases a margin of 1cm is acceptable. The focus should be on removing the tumor, maintaining the reservoir function of the stomach, and assuring a closure that will be unlikely to leak postoperatively.

Be careful using partial gastrectomy on the lesser curvature of the stomach: it is possible to resect small tumors here, but at least one branch of the vagus nerve should be preserved. If this is not possible, perform a distal or subtotal gastrectomy instead. If both branches of the vagus are severed, the stomach will not drain properly.

The surgeon must be certain of the histology of the tumor: using wedge gastrectomy as an “excisional biopsy” is unwise, as the most likely cause of a neoplastic mass in the stomach is adenocarcinoma. If you have no access to immunostaining, a gastric spindle cell neoplasm in the submucosa of the stomach wall (by plain histology) is enough evidence to assume a Gastrointestinal Stromal tumor, in our opinion. If you have no access to pathology services at all, formal gastric resection with 5cm margins is the right almost all of the time.

Partial gastrectomy proceeds in the following steps:

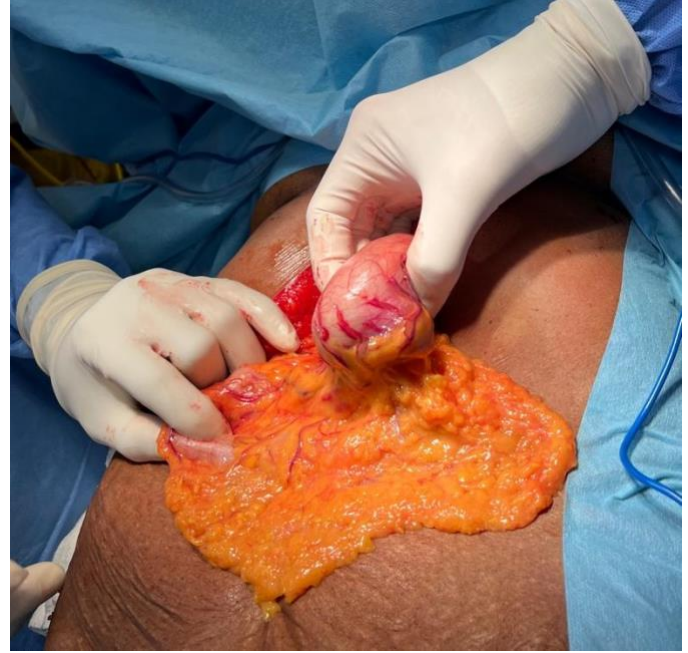- Exploration of the abdomen
- Complete mobilization of the stomach, including entry into the lesser sac if necessary
- Excision of the tumor
- Closure of the gastric wall

## Steps:

1. Midline abdominal incision is suitable for most cases of partial gastrectomy. For a tumor

confined to the fundus a left subcostal incision is also acceptable.

2. Explore the abdomen thoroughly; Neuroendocrine tumors are prone to metastasize to the liver. Locate the tumor and assess for local invasion of any adjacent structures.

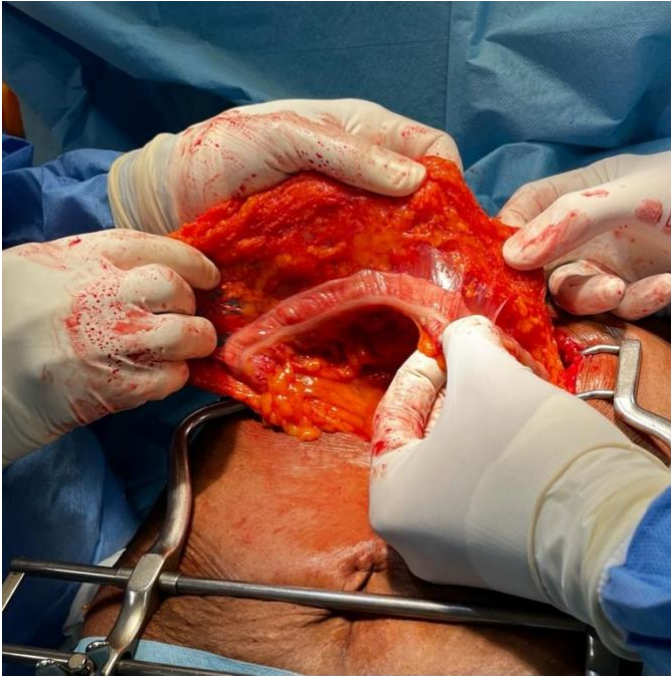


*This tumor is located along the greater curvature below the gastroepiploic vessels, which will be resected adjacent to the tumor, along with the attached omentum.*

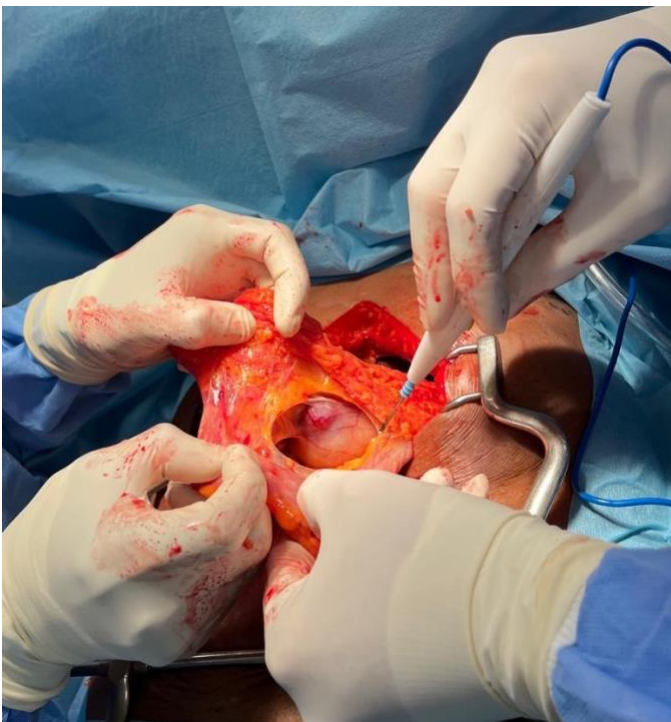
3. If necessary, enter the lesser sac through the avascular plane between the omentum and the left transverse colon. Expand this entry to the left and right until the tumor is clearly visible. This plane can be developed to the patient’s right all the way to the origin of the right gastroepiploic artery, and to the left all the way to the esophageal hiatus and short gastric vessels. Avoid ligating any of the stomach’s blood supply that is not necessary for the resection. Take special care to preserve the short gastric vessels if possible.

## Partial “Wedge” Gastrectomy

Richard Davis



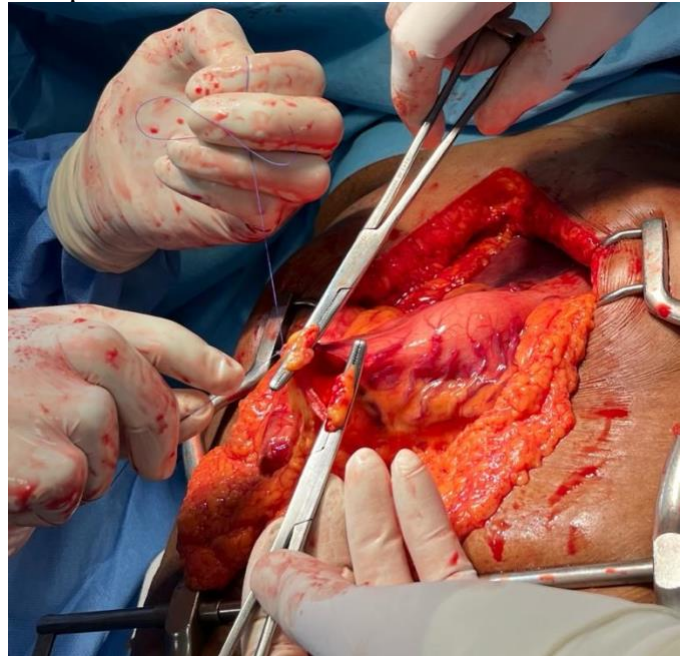
*The avascular plane between the colon and omentum allows easy entry into the lesser sac and access to the posterior stomach. The avascular space is opened by the hands of the surgeon on the patient's left.*



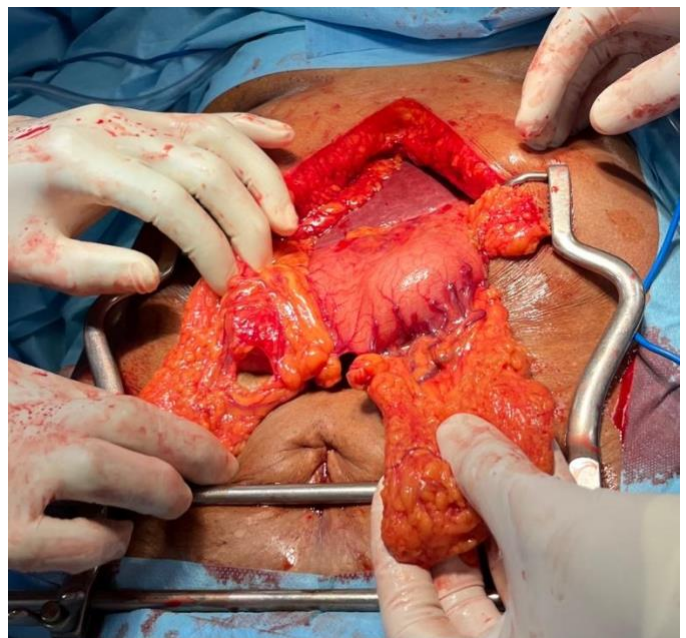
*Division of the plane between the colon and omentum reveals the lesser sac, posterior gastric wall, and the tumor.*

4. If the tumor is adjacent to the gastroepiploic vessels, ligate these on either side and divide the

omentum that will be removed with the specimen.



*The gastroepiploic vessels are ligated on either side of the tumor. The omentum supplied by the devascularized portion of these vessels must be resected as well.*



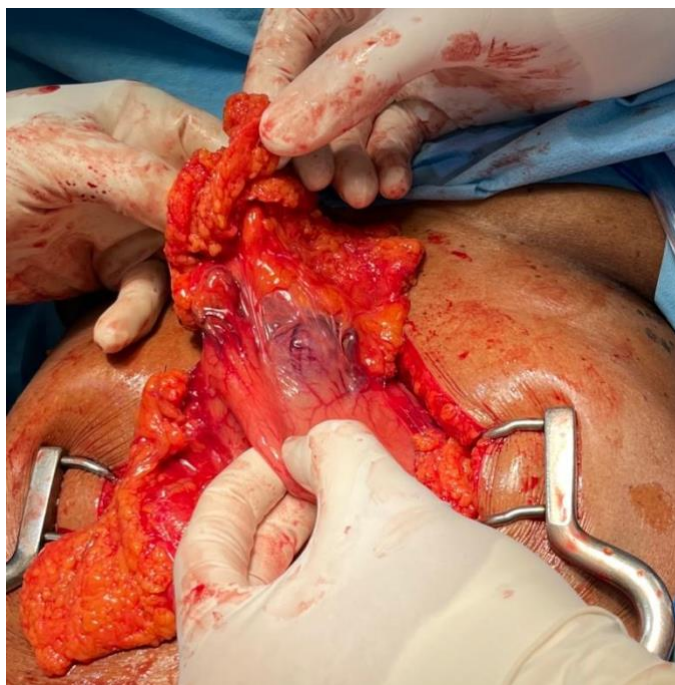
*The divided gastroepiploic arcade and omentum adjacent to the tumor.*

5. It can be difficult to assess the margins from outside the stomach. Evaluate the gastric wall adjacent to the tumor by gently pinching it.



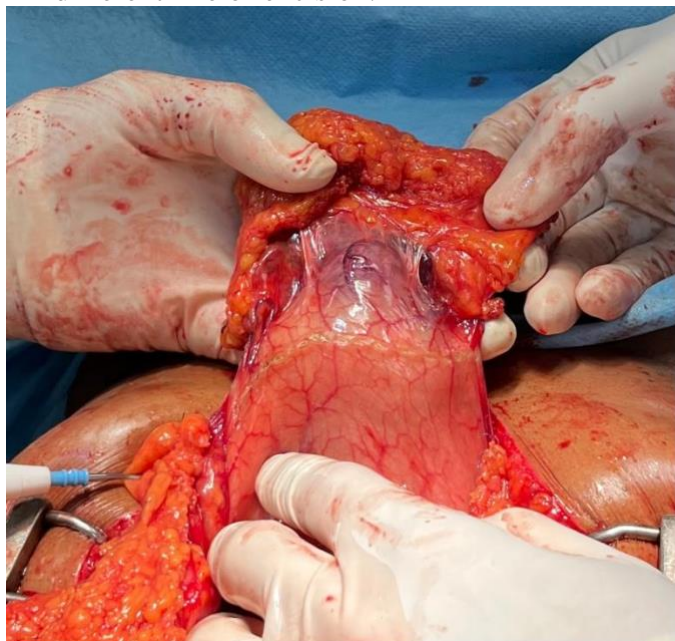
## Partial “Wedge” Gastrectomy

Richard Davis



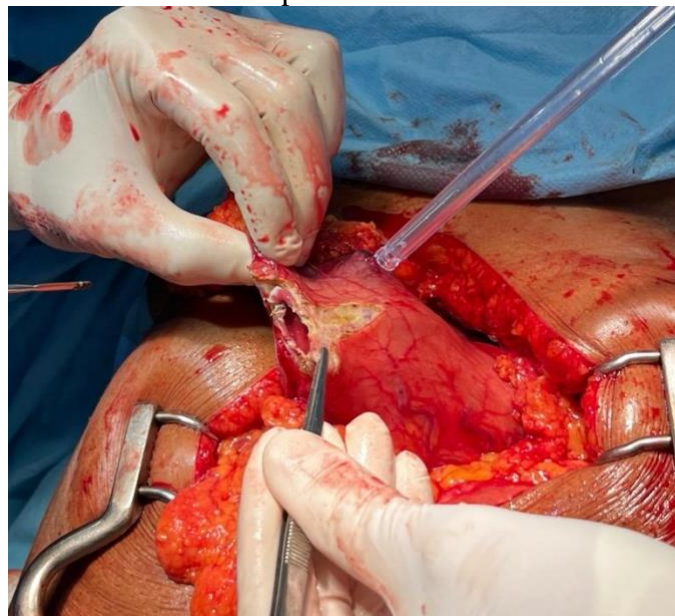
*Gently palpating the gastric wall adjacent to the tumor allows it to be assessed and a line of incision planned.*

6. Once you have chosen a likely margin, score the serosal surface with gentle taps with the diathermy. Do not make these marks very deep; upon opening the stomach you may choose a different line of excision.



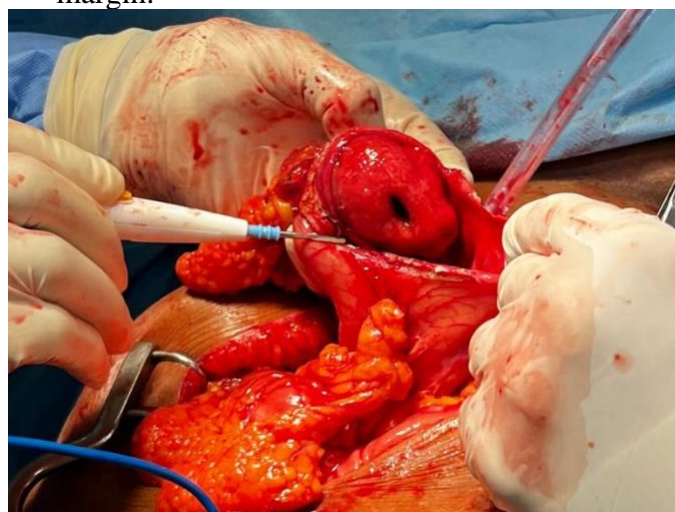
*Gently scoring the serosa in the area of planned incision. These are not deep marks, so the line of incision can be changed once the tumor is seen from inside the lumen of the stomach.*

7. Open one part of the stomach along the line you have chosen. Go slowly and assure hemostasis, as the stomach is prone to bleed when divided.



*The stomach is opened in one location and the tumor is visualized from inside. The incision is then extended.*

8. Once the stomach is open enough to see the tumor, adjust your planned lines of excision if necessary. Avoid removing more than a 1cm margin.



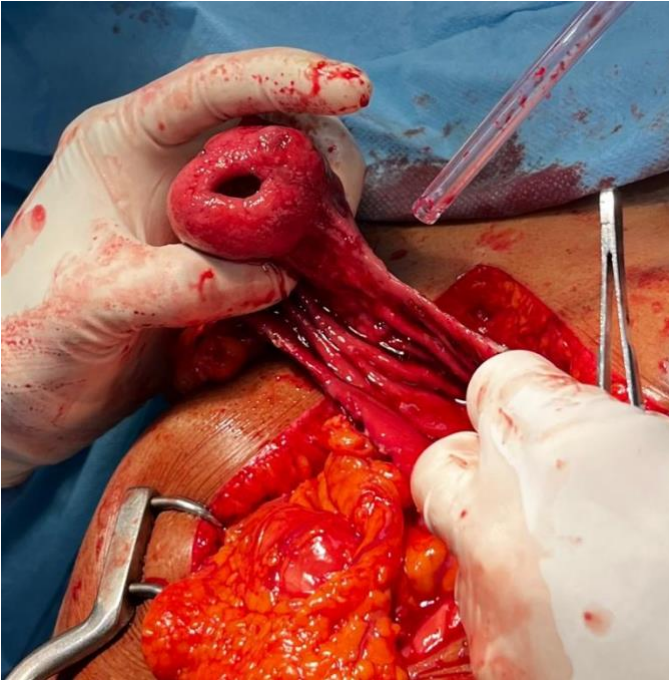*As the tumor becomes more visible, it is easier to assure that the margin of excision is neither too large nor too small.*

9. Complete the tumor excision.

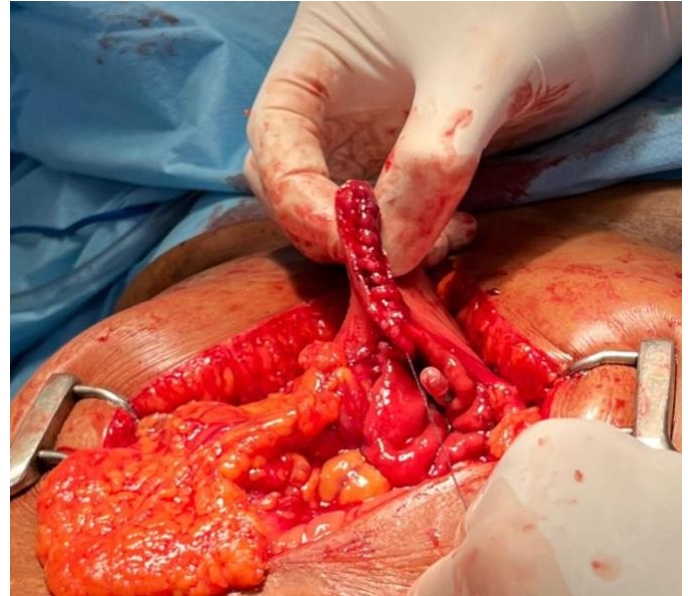

## Partial “Wedge” Gastrectomy

Richard Davis

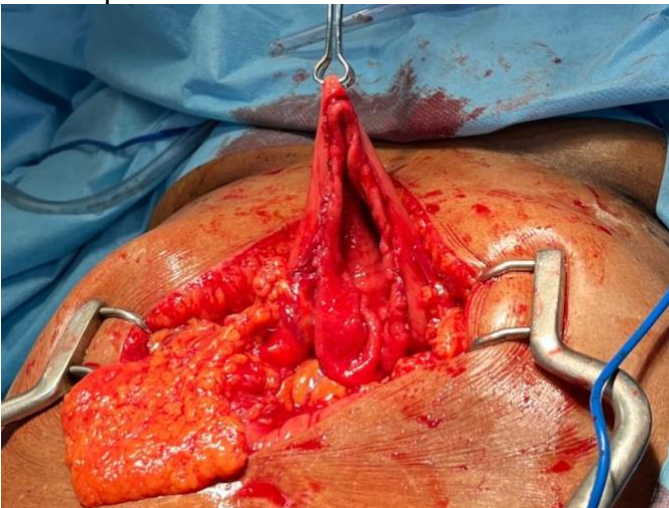


*Completing the excision, taking care to control bleeding points on the cut stomach wall.*

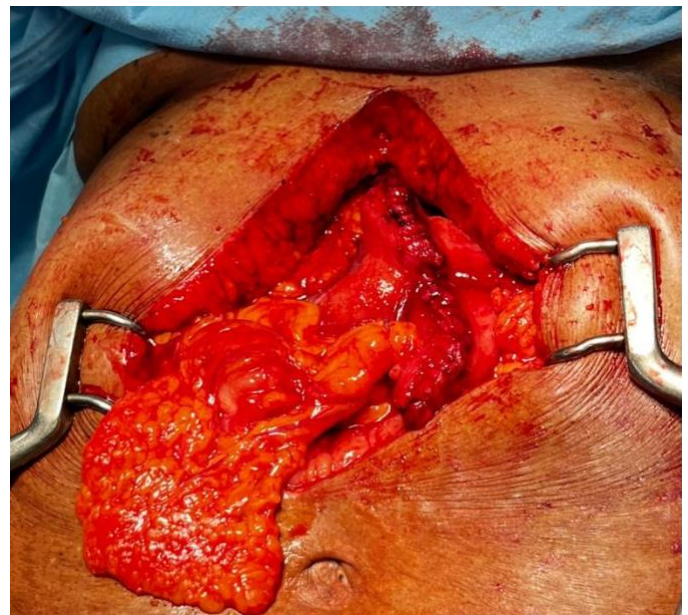

*As the serosa retracts after the stomach is cut, it is easy to close in two layers, with the mucosa and submucosa only in the first layer. The tip of the nasogastric tube is seen in the lower part of the gastrotomy. This should be pulled back to avoid any pressure on the suture line.*

10. Decide on the orientation of the closure that will most closely preserve the stomach’s reservoir function. Avoid narrowing the stomach in the mid-portion and thus dividing it into “two compartments.”



*In this case, the decision was made to close the stomach transversely, as a longitudinal closure might have narrowed it and led to two compartments connected by a narrow tube.*



*The first layer of closure, completed.*

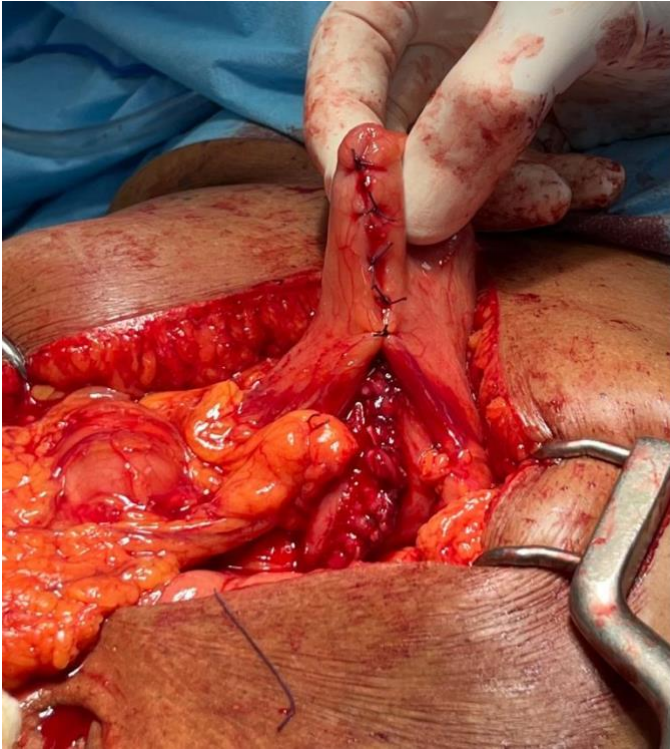
11. Close the stomach in two layers: the first layer will be the mucosa and submucosa only.

12. The second layer will be seromuscular sutures to invert the first suture line.

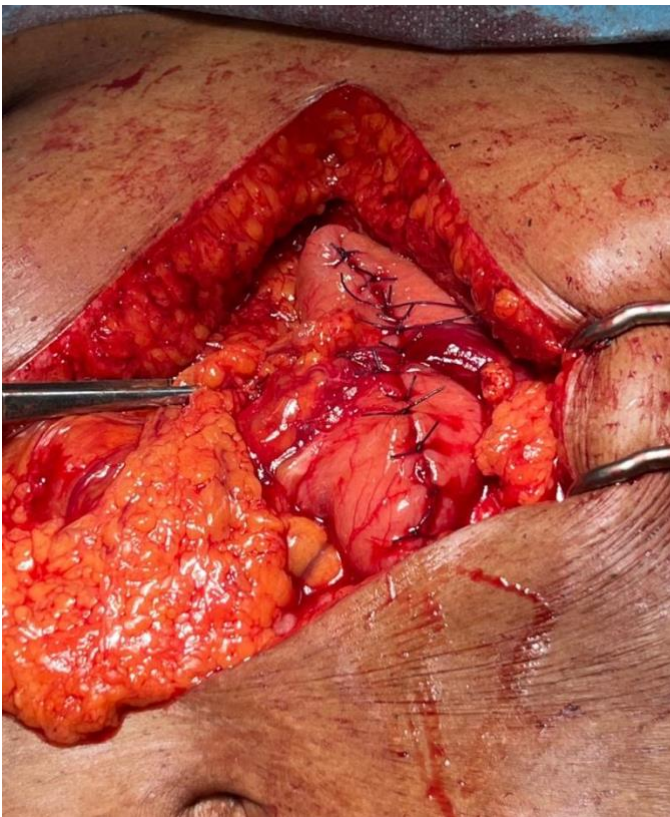


## Partial “Wedge” Gastrectomy

Richard Davis



*Interrupted seromuscular sutures invert the first suture line completely.*



*The completed closure of the gastric wall.*

13. In cases of malnutrition or ongoing chemotherapy, we prefer to reinforce the suture line with a “tongue” of omentum, a third layer, secured with seromuscular sutures that bury the suture line further within the omentum.

### Pitfalls

- Suture line leak is best prevented by meticulous technique. Strive for a technically perfect first layer and then completely invert the suture line with the second layer. Our practice is to leave a nasogastric tube in place and remove it on the first postoperative day if the abdomen is not distended.
- Devascularizing the stomach by taking too large of a portion of it is a devastating complication. When this occurs, your best option is converting the resection to a subtotal gastrectomy. This will only be possible if the short gastric vessels are still intact, as they are the main blood supply to the remnant stomach after a subtotal gastrectomy. If you need to divide the short gastric vessels during a wedge gastrectomy, do so only if you are sure you will not need to convert to a subtotal gastrectomy (one example would be a tumor confined to the fundus.) Carefully inspect the mucosa and serosa at the end of the resection to be sure it is a normal color. Compare the color of the stomach serosa to the small intestine if necessary.
- Patients on active chemotherapy for gastric lymphoma with a perforated tumor present a special challenge. Wedge resection with 1cm margins is appropriate oncologically, affords the patient the smallest operation possible, and allows closure with viable tissue. But due to poor nutrition and steroid use, these operations are most prone to leakage and other complications. You are wise to leave the NG tube in for a longer time. As with any gastric or esophageal surgery on a malnourished patient, place a feeding jejunostomy tube. This allows you to manage a small leak with drainage alone and maintain nutrition. An omental patch sutured loosely over your two layer closure acts as another “safety net” in any patient at risk for complications.

# Partial “Wedge” Gastrectomy

Richard Davis

Richard Davis MD FACS FCS(ECSA)

AIC Kijabe Hospital

Kenya

April 2022

**OPEN MANUAL OF SURGERY IN RESOURCE-LIMITED SETTINGS**

[www.vumc.org/global-surgical-atlas](http://www.vumc.org/global-surgical-atlas)

This work is licensed under a [Creative Commons Attribution-ShareAlike 3.0 Unported License](https://creativecommons.org/licenses/by-sa/3.0/)

