

Management of Open Abdomen and Enteric Fistula

Richard Davis, Daniel Moenga, Elizabeth Mwachiro

Background:

An enterocutaneous fistula is one of the most feared complications for the abdominal surgeon. It can be the devastating consequence of a single lapse in judgment during a long, tedious operation, either by yourself or another surgeon.

The three stages of fistula management are classically described as resuscitation and infection control, investigation, and intervention. In this chapter, we will focus on the latter two stages, and the difficult management decisions and strategies to get you to a successful result. Regarding the first stage, remember that a leaking intestine inside the abdomen will leak into the peritoneum before finding its way to the skin. Sepsis control consists of draining the peritoneum and assuring a consistent exit of the leakage. Usually this will involve re-opening the abdominal incision, or making a new opening over the leaking site, and not closing it. This results in the dreaded “open abdomen.” We discuss this entity here as well.

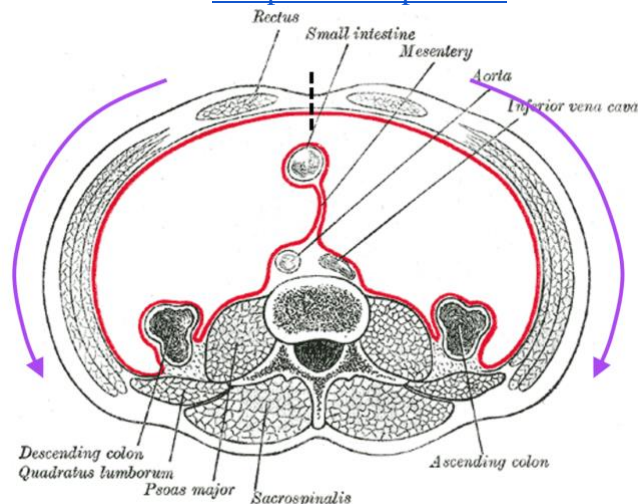
The best possible outcome for a fistula is for it to close on its own. In deciding whether this outcome is likely, remember the FRIENDS of a fistula. These are conditions that make a fistula less likely to close spontaneously:

- Foreign body (including mesh)
- Radiation history
- Infection
- Epithelization of the tract (this is especially important in anal fistulas, a different subject.)
- Neoplasia
- Distal obstruction: this one is especially important in the open abdomen, and is also responsible for many anastomotic leaks!
- Steroid use

In our opinion, it is a failure of understanding to try to treat a fistula by only making a patient “NPO,” placing them on parenteral nutrition, and waiting for the fistula to close on its own. Although this approach might be needed with very proximal fistulas, in most situations there are other options that cost less money and allow a patient to experience the joy of eating. In any event, in a resource-limited setting, prolonged hospitalization and parenteral nutrition are not realistic options.

Anatomy:

The lateral abdominal wall muscles originate at the posterior aspect of the abdominal cavity, along the lumbodorsal fascia and other midline posterior structures. They insert into the lateral aspect of the rectus sheath on each side. If the two rectus sheaths are separated, as in open abdomen, the lateral abdominal wall muscles will retract. After about 7 days, this retraction is so extensive that the abdominal incision can not be closed again without measures such as [components separation](#).



When the linea alba, between the two rectus muscles (Straight dotted line) is divided, the lateral abdominal wall muscles begin to contract, unopposed, towards their origin (Purple arrows.) If this contraction is allowed to persist for more than 7 days, it may be impossible to reapproximate the linea alba at the midline. An “open abdomen” is usually the result.

Within the abdominal cavity, any sort of intervention leads to severe inflammation. Especially if there is spillage of enteric contents or of purulent material, this inflammation can be significant. As a general rule of thumb, if the patient had an uncomplicated laparotomy, you should not attempt to operate in their abdomen during the time period of 2-6 weeks after surgery. If there was spillage of succus or infection, do not operate for at least 3 months: 6 months would be preferable. Failure to heed these timelines leads to a difficult and bloody operation that has a very high chance of causing an inadvertent enterotomy.

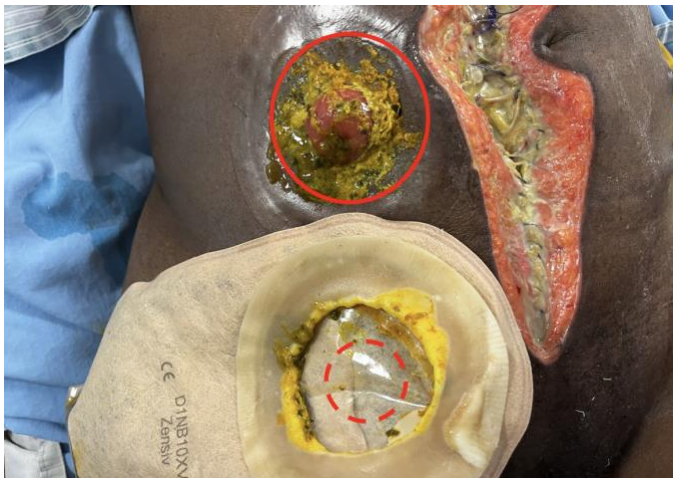
If you are operating on a patient with malnutrition or severe intra-abdominal contamination, it is best to avoid any bowel anastomosis or suture if possible. If you must suture bowel, there are several options for reinforcing the

Management of Open Abdomen and Enteric Fistula

Richard Davis, Daniel Moenga, Elizabeth Mwachiro

suture line, including omentum, the gastroepiploic arcade, and the round and falciform ligaments. The classic example of such reinforcement is the Graham patch for closure of a duodenal perforation. Some of these options are described further below in “Prevention.”

Succus entericus, the content of the small intestine, is very caustic and damaging to both peritoneum and skin. This is why most surgeons recommend avoiding operation for 3-6 months after intraperitoneal spillage. But the surgeon should also do their best to prevent this fluid from coming in contact with the skin. Once the skin is irritated, it will be painful to the patient and much more difficult to apply dressings or ostomy appliances to. One common mistake is cutting the hole in the ostomy appliance too big: it must be trimmed to almost exactly the size of the exposed mucosa or wound. Peri-wound or peristomal skin excoriation is much better avoided than treated, as we describe further below.



An ostomy appliance that has been cut too large exposes the skin to enteric contents (within solid Red circle) which can cause irritation over time. It would be better to cut the appliance to just a little smaller than the ostomy (dashed Red circle.)

Small bowel is very adaptable. Over time, it can make itself more able to absorb nutrients and water according to the needs of the patient. Surgeons caring for patients with “short gut syndrome” have found that the intestine can adapt so much that an adult can survive with only 75 cm of small intestine. However this transition takes several months; in high-resource settings, patients are helped through this time with total parenteral nutrition. In our settings, patients may survive with as little as 100 cm

of small intestine, but this process is very difficult for both the patient and the surgeon. We offer some tips for slowing bowel transit, increasing absorption, and avoiding dehydration below.

Principles:

We divide this section into three parts:

- Prevention, including dealing with an intraoperative enterotomy that is at risk for becoming a fistula
- Wound care, including prevention of further injury to exposed bowel and isolating fistula output.
- Output management, including thickening the succus, slowing transit time, and maximizing enteral nutrition.

Prevention:

Preventing an enterotomy is much better than treatment. Recognize situations where you are at risk for developing an enterocutaneous fistula. Try as best you can to avoid operating in the abdomen between 2 and 6 weeks after the most recent laparotomy. If there was infection or excessive contamination, wait 3 months at a minimum.

When performing adhesiolysis, use meticulous surgical technique including sharp dissection. For especially tightly scarred adhesions, we sometimes use a scalpel to carefully open up the plane between two serosal surfaces. Use diathermy only if there is an easily seen plane of tissue between the objects you are trying to separate. Avoid blunt dissection with a fingertip, tearing adhesions. The fingertip will enter much more readily into the lumen of the bowel rather than the adhered space between loops of bowel. If you expect difficult adhesions and a “hostile” abdomen, be sure to give yourself enough time for these operations; consider allotting the whole day for such patients.

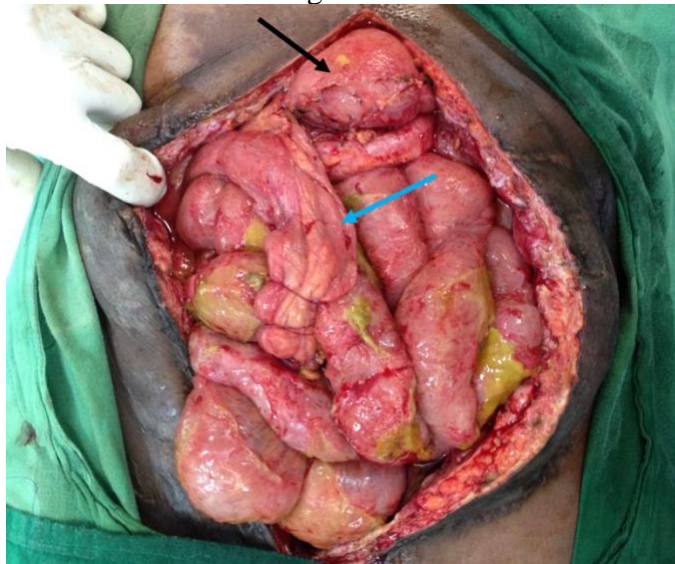If you are operating on a patient who is malnourished, if the bowel cannot be mobilized, or if there are extensive dense adhesions, you may get an inadvertent enterotomy. This is very difficult situation to manage. It is tempting to put a few stitches and close the bowel in this situation. This approach will inevitably fail. Do your best to mobilize the enterotomy enough to create an ostomy,

Management of Open Abdomen and Enteric Fistula

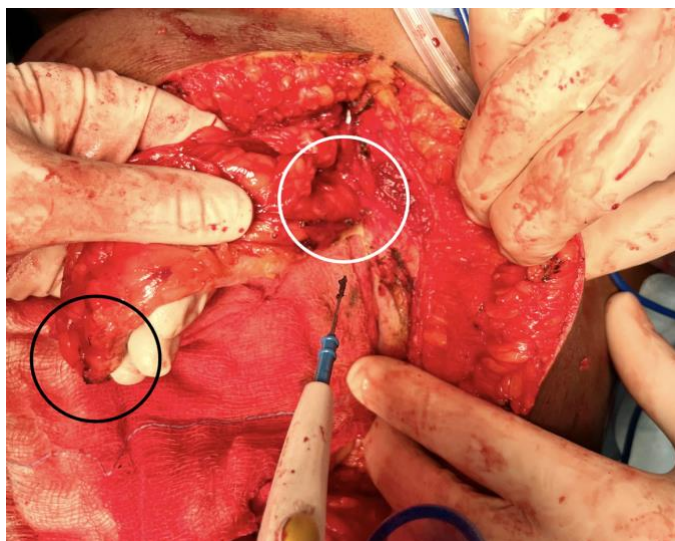
Richard Davis, Daniel Moenga, Elizabeth Mwachiro

separate from the abdominal incision or, in last resort, through it.

If your inadvertent enterotomy is in the duodenum or proximal jejunum, you must repair it because an ostomy here would be incompatible with life. Reinforce your repair with omentum, as you would with a perforated duodenal ulcer. If the omentum is not available, other options include the round ligament of the liver or the gastroepiploic arcade dissected off the greater curvature of stomach.



This patient had late presentation of an intraoperative injury to a proximal loop of jejunum. The omentum was contracted and could not be mobilized to the site of injury. We divided the gastroepiploic vessels on the left side of the stomach (Black arrow) and dissected these vessels to the stomach until we had a length of well-vascularized, fatty tissue (Blue arrow) that could reach the repaired jejunum. We then used this tissue to reinforce the repair.

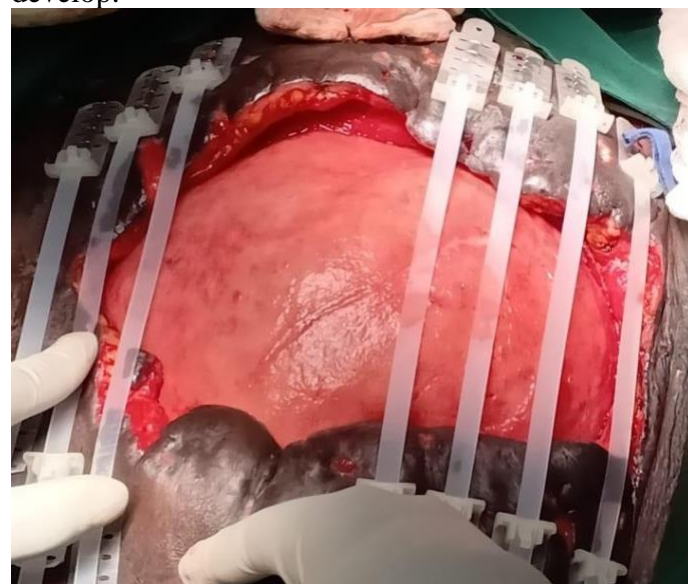


A round ligament (Ligamentum Teres) flap can be harvested during laparotomy by ligating the round ligament at its

connection to the umbilicus (Black circle) and then disconnecting the fatty tissue within the falciform ligament from the abdominal wall at the midline (White circle.) This flap will usually reach the intra-abdominal esophagus, stomach, duodenum, and central parts of the liver.

Wound Care

In all cases, the best coverage of exposed bowel is the patient's own tissue if possible. Reapproximate fascia if you can do so, especially if the laparotomy was within the last 7 days. This is especially important when re-operating for laparotomy dehiscence. Often if the fascia alone cannot be closed (if >1 week since opened,) the skin will still come together at the midline and cover the intestines. See [Temporary Abdominal Closure](#) and [Closure of Laparotomy Dehiscence](#). Remember, the longer the intestines are exposed to the air, the more likely that an entero-atmospheric fistula will develop.



For an open abdominal wound such as this one, immediate closure will be impossible. The exposed bowel must be protected and covered as soon as possible. One way to accomplish this is to use a device that exerts continuous traction on the skin and pulls it together in the midline, as shown. We explain this concept further in the Guide below.

If you are faced with exposed bowel that can not be covered with skin or fascia, you must protect it relentlessly. Do not allow it to become dehydrated. If the serosa has some adherent necrotic tissue, do not attempt to directly debride it, no matter how contaminated it might appear. You may sharply debride fascia, muscle, or subcutaneous tissue if you

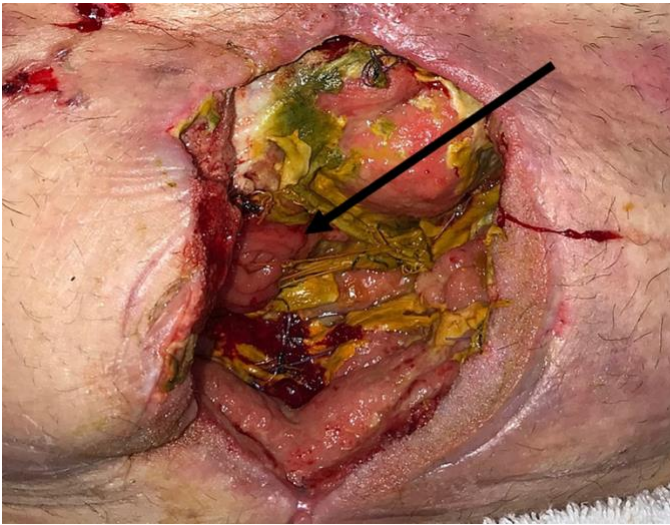Management of Open Abdomen and Enteric Fistula

Richard Davis, Daniel Moenga, Elizabeth Mwachiro

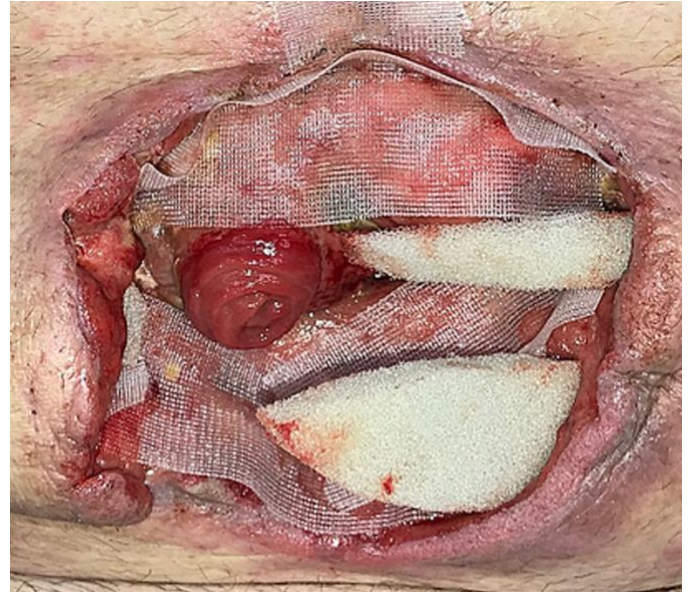are sure the necrosis is involving these tissues only, but avoid debriding bowel directly.

Avoid repeated dressing changes with gauze or sponge directly on bowel: this “wet to dry” wound care strategy may work well in other parts of the body. But it makes the wound clean by removing a bit of tissue every time the gauze is removed. On the bowel, this will inevitably lead to a fistula. Instead, use petroleum jelly (Vaseline®) gauze. In resource-rich countries, the KCI Wound-Vac system has a proprietary “white” sponge that can be safely applied directly to the serosa of the bowel.

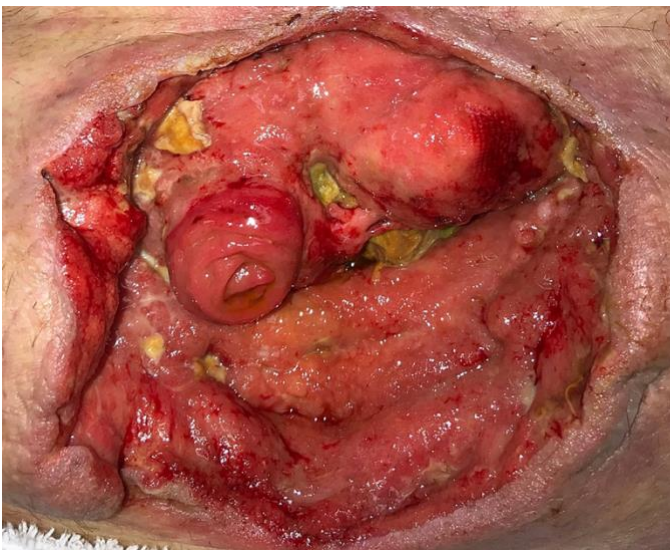
decreased and granulation tissue is beginning to appear. When all of the eschar has disappeared and the wound is relatively flat, it can be allowed to close more by wound contraction, or the exposed bowel can be covered with a split-thickness skin graft and the fistula closed later. Source: Desvigne MN et al, doi:10.7759/cureus.36



Initial appearance of a wound after dehiscence and development of a fistula (Black arrow.) Sharp debridement the eschar should be done where possible, but avoid it on the surface of the exposed bowel. Source: Desvigne MN et al, doi:10.7759/cureus.36



When caring for wounds such as these, exposed bowel must be covered with petroleum jelly (Vaseline®)- soaked gauze or other non-adhesive material. It must not be treated with serial “wet to dry” dressing changes or more fistulae will result. Here, all exposed tissue except the fistula will be covered with a vacuum dressing. Source: Desvigne MN et al, doi:10.7759/cureus.36



Appearance of the same wound after application of the principles in this chapter. The eschar on the bowel has



We make our own petroleum jelly gauze by impregnating plain gauze with jelly in a reusable sterilizable container.

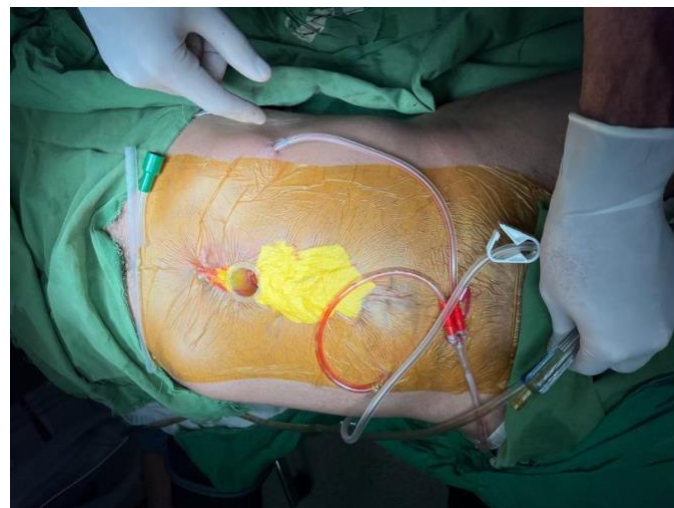If you have a combination of exposed serosa and a fistula opening, the best strategy for wound care is to keep the enteric contents and the rest of the wound separate. You may choose to intubate the fistula with a tube that will stay in place on its own,

Management of Open Abdomen and Enteric Fistula

Richard Davis, Daniel Moenga, Elizabeth Mwachiro

such as a Malecot or T-tube, especially if the fistula opening is small. Some authors recommend this practice and others do not. If a tube will make management easier for you, do not hesitate to do so (it may help align a wound protection device or a vacuum device.) But do not imagine that the tube will drain all of the effluent. As you use the strategies described here to make the effluent thicker, it will block the tube and management will be easier without it.

Attempt to isolate the fistula from the rest of the wound and collect its effluent separately. Use barrier devices to divert and collect enteric contents and protect the wound. Resource-rich countries have dedicated silicone devices that create a barrier around the fistula site.

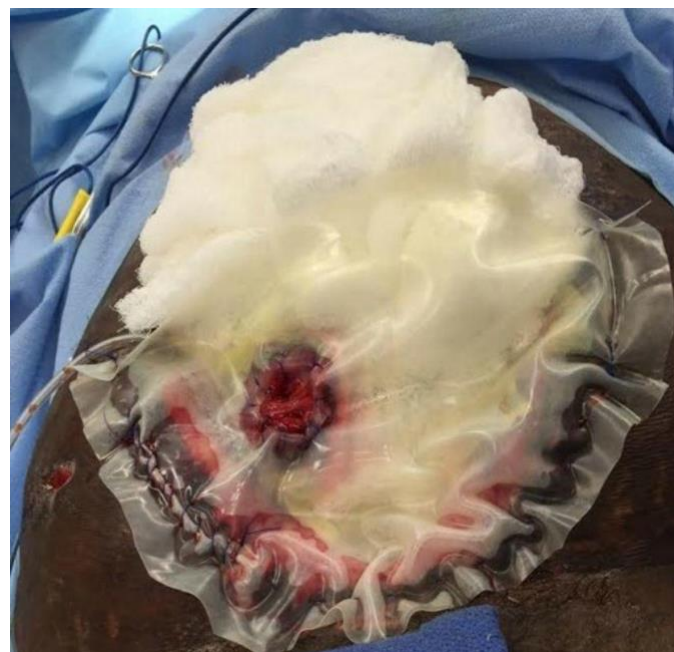

A vacuum-assisted closure dressing applied to an open abdomen, with a circular silicone appliance isolating the fistula from the rest of the wound. We explain how to set up this dressing below.



Commercially available silicone fistula management devices, such as these from KCI™ can be trimmed as needed and used with commercial negative pressure wound therapy devices. Source: <https://www.acelity.com/healthcare-professionals/global-product-catalog/catalog/fistula-solution-devices>

In our setting, such devices are usually not available and we must be creative. Baby bottle nipples, especially those intended for babies with cleft palate, can be useful. We have also used the silicone from an ambu-bag, cut into the shape of a “fence” to isolate the stoma from the rest of the wound. A silicone cupcake mold with a hole cut in the base, or other modified silicone items, would probably work well for this purpose. We demonstrate this kind of wound device in the Guide at the end of this chapter.



Another technique that has been described for separating stoma output from the rest of the wound: the “Floating Stoma” technique involves suturing a piece of thick plastic to the wound edges, making a hole over the stoma, and then suturing the mucosa to the hole. The bowel below the plastic can then be treated with serial dressing changes with petroleum jelly gauze, while an ostomy appliance sticks to the plastic and collects the effluent. You will need to frequently re-suture the mucosa to the plastic to maintain a seal here. Source: Gross DJ et al doi: 10.1136/tsaco-2019-000381

Remember that improvised vacuum dressings and barrier devices, such as those described in the next section, are extremely labor-intensive and prone to failure. In resource-rich settings, where

Management of Open Abdomen and Enteric Fistula

Richard Davis, Daniel Moenga, Elizabeth Mwachiro

dedicated equipment and nursing are available, they are usually changed every 3-5 days. In our settings, they will fill with succus and overflow onto the skin much more quickly. Do not be discouraged when this happens, and be prepared for a long road.

Output Management

In our setting, simply withholding all oral intake and giving long term parenteral nutrition are not realistic options. As much as you can, you must use the patient's intestine to maintain their nutrition.

Patients with "short gut syndrome" and 75 cm of jejunum can survive if parenteral nutrition is used as a "bridge" for a few months while the small bowel mucosa adapts. In our setting, 100 cm of jejunum is probably enough. Decide whether this is the case with your patient: if the small intestinal fistula is at least 100 cm downstream from the ligament of Treitz, they will survive with the methods described below.

Medications and dietary measures can be used to thicken the secretions. The goal is for the small bowel succus to be about the thickness of toothpaste, and for colonic fistula output to be formed stool. The following medications can be used, most effectively in combination. All patients with enterocutaneous fistula are on the first two medicines, with the final three added as needed.

- Omeprazole and other proton pump inhibitors are given orally to decrease gastric secretions
- Oral rehydration solutions: these will both thicken the effluent and replace lost electrolytes. In patients with an enteric fistula, we use double-strength oral rehydration solution at a target dose of 3L per day, which the patient drinks slowly all day long.
- Loperamide, an antidiarrheal. We use up to 24mg per day divided into three or four daily doses. At high doses, there is an increased risk of torsades de pointes and other lethal arrhythmias.
- Codeine is very effective especially in combination with loperamide. Like all narcotics, this medicine has a potential for addiction if used for a prolonged time.
- Diphenoxylate / atropine is very effective at thickening succus. It has a side effect of dry mouth and tachycardia. This medication may not be available in some countries. It may be too

effective, especially when used in combination with other antimotility agents.

The patient's diet can make a large difference on the quality and quantity of output from the fistula. Feed them a diet rich in complex carbohydrates and low in fat. Hypertonic fluids, such as soda and fruit juices, should be avoided, because they usually worsen diarrhea. Remember that uncontrolled sepsis can cause nausea and worsen the patient's appetite, so consider whether the patient has an undrained focus of infection.

Using this approach along with meticulous wound care allows you to effectively convert the fistula to an "ostomy." Then the patient can take nutrition orally and wait until an appropriate time for repair- usually 3-6 months.

You will find that in some cases, as the fistula closes, more enteric contents will go distally past the fistula and come out as stool. When that happens, the medicines described above will cause the patient constipation. If the patient begins to have abdominal pain and constipation, taper the medicines down, starting with codeine because of its addictive potential.

Decision Making:

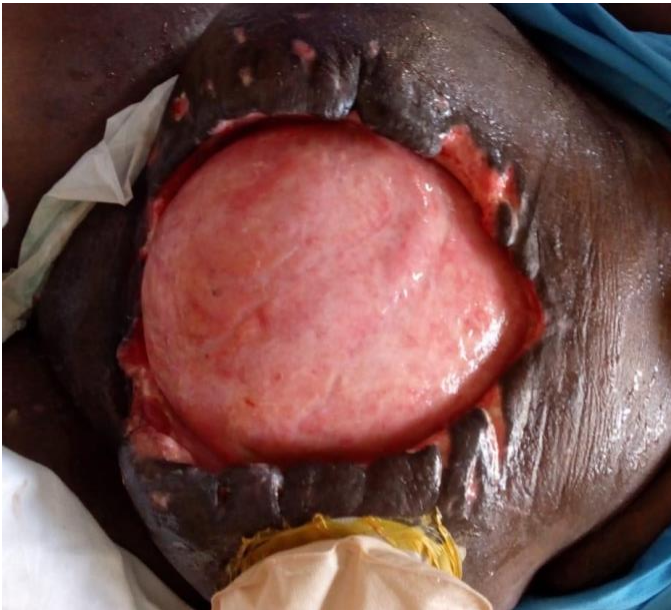
You will be faced with the following situations:

Open Abdomen, No Fistula: Take great care of the exposed bowel and try to close the fascia or skin over it progressively! Do not debride necrotic tissue directly on the bowel, and do not apply anything except petroleum jelly-soaked gauze or other compatible material directly to the bowel.



Management of Open Abdomen and Enteric Fistula

Richard Davis, Daniel Moenga, Elizabeth Mwachiro



This open abdomen has been cared for well: the exposed bowel has completely granulated. This wound could be treated with a split thickness skin graft (covered after placement for 5 days with a vacuum dressing) or with a continuous traction technique as described in the Guide below.

Open Abdomen With Fistula: Keep the wound clean and try to keep enteric contents away from the skin using the techniques described in this article. Try to decide if the fistula is >100 cm from the ligament of Treitz. There are several ways to do this:

- Carefully examine any films you may have, especially a CT scan with oral contrast.
- Perform a Gastrografin small bowel study and examine the films carefully to estimate how much bowel is present before the fistula. The radiographer may need to take films earlier than usual for very high fistulas.
- Attempt to use techniques described in the previous section to thicken the succus and slow transit time. If, on maximum dosages, the output is still >500cc per day, likely you will not succeed with non-operative management.

If the fistula is more than 100 cm from the ligament of Treitz, your main problems become wound care, keeping the patient hydrated and free of infection, and psychological care of the patient. This last matter is not trivial, we will discuss it further below.

If the fistula is less than 100 cm from the Ligament of Treitz, this is where prolonged TPN and bowel rest would be used in a resource-rich setting.

Examples include duodenal, pancreatic, biliary or proximal jejunal fistulas that have already failed multiple attempts at operation. In our setting, the only option is to operate and attempt to close the fistula. You must use meticulous sharp dissection, reapproximate bowel under no tension, and reinforce your closure with well-vascularized tissue as described above. Remember that this closure will fail if there is distal obstruction.

During any of these operations, if you have any reason to suspect distal obstruction, take no chances. The patient may have a colon tumor, stricture at a previous anastomosis or ostomy site, or extensive adhesions. Make an ileostomy or jejunostomy that leaves at least 100 cm, preferably much more. If you form the ostomy well, its output will be easier to manage.

Patients with a colonic fistula may only need loperamide and oral rehydration solutions. Patients with more proximal fistulas may need all of the medications, with their risks of side effects. Keep the patient on IV fluids as you titrate the dosages upwards.

It is tempting to try to refeed secretions to the distal small intestine as they come out of the fistula. This option is frequently discussed in textbooks. In practice this is very difficult to do, especially in low-resource settings. It cannot be done by bolus feeds, as there is no gastric reservoir; the feeds inevitably reflux back into the wound if given as a bolus. Attempting to feed them by “dripping” them into the intestine will inevitably block the tubing, as you likely do not have a pump.

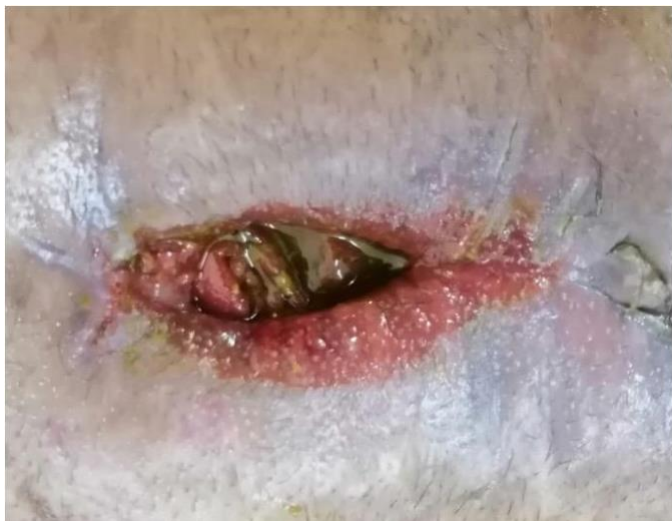Open Fistula, Now Controlled

Once the wound is clean and you are able to successfully control the output, the next question is how to treat the wound. If it is getting smaller on its own, continue your current treatment. It may reach a steady state, or it may continue to shrink and close on its own. As it becomes smaller, decide whether a simple ostomy appliance can be trimmed to fit directly over it. In general, your goals are to make the appliance stick to the skin and to keep the efflux from contacting the skin. It is acceptable to allow some of the efflux to pool in the wound, as long as it does not go anywhere else. You may be able to

Management of Open Abdomen and Enteric Fistula

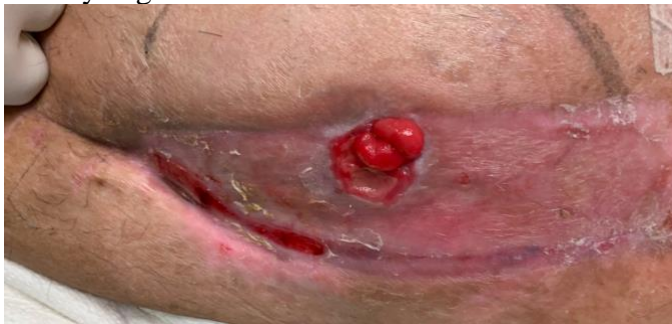Richard Davis, Daniel Moenga, Elizabeth Mwachiro

discharge the patient at this time, if they are able to care for the wound well.



This wound, which previously needed a vacuum-assisted dressing and fistula isolation, eventually got small enough that an ostomy appliance alone could be applied. In fact, the wound likely contracted further since the last appliance was placed. As this occurred, the skin came in contact with the bowel contents and got excoriated as shown. We would not do any further intervention on this wound, except possibly to decrease stool-thickening agents as output decreases and more enteric contents remain within the intestines. .

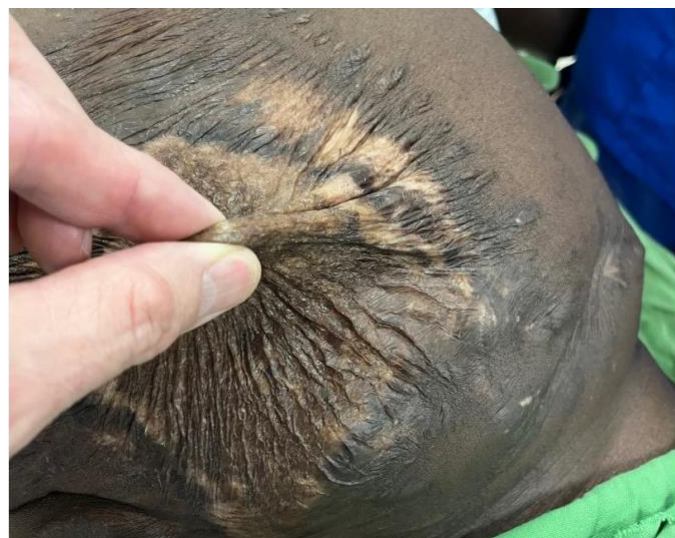If the wound still has large amounts of exposed bowel, but is otherwise very clean, you may skin graft the serosal surface of the bowel. At this point your vacuum dressing should be able to stay in place for 4 or 5 days without being changed. Apply a skin graft under the vacuum dressing, along with your barrier device that directs the efflux into the ostomy bag.



This patient had an injury to the ileum during attempted repair of an incarcerated incisional hernia. An open abdomen resulted, with exposed bowel and a single fistula. The wound was managed as described here until the exposed bowel could be skin grafted. The fistula now functions as an ileostomy: an appliance can be fitted to it and the patient can eat and maintain nutrition until an ideal time for definitive repair. Photo courtesy of Dr. Demetrios Demetriades.

Previous Fistula, Now Converted To “Ostomy”

These patients will (understandably) be eager to have their ostomy closed. Many will have an incisional hernia that must be repaired at the same time. It is best to wait 6 months if you can, to operate on this type of abdomen. If the patient is very disturbed by the fistula, 3 months may be acceptable but this is a minimum. If you have applied a skin graft directly to bowel, you must be able to pinch it and feel that it is freely mobile over the bowel.



This patient had an open abdomen (without fistula) and had a skin graft applied directly to the bowel. Now, the skin is freely mobile and can easily be “pinched” away from the bowel. He is ready for repair of his incisional hernia.

You will have the greatest chance of success if you wait until all the inflammation has completely died down. These are lengthy and difficult operations, with careful adhesiolysis of all of the small bowel, resection of the fistula and anastomosis, and likely [component separation](#) for closure. Some advocate having two teams for these operations: one to do the lysis of adhesions, fistula takedown, and anastomosis, and another to do the components separation and fascial closure. This is wise advice.

Emotional Toll of Fistula

This condition is very disturbing for both the patient and the physician. The patient will very quickly realize that when they eat and drink less, there is less output from the fistula. Especially if output causes pain, or an embarrassing smelly mess, they will restrict their oral intake. Nothing could be

Management of Open Abdomen and Enteric Fistula


Richard Davis, Daniel Moenga, Elizabeth Mwachiro

worse for them- they need nutrition most of all! Avoid this situation, first by decreasing and controlling fistula output as described here, and second by explaining the situation to the patient and encouraging them. Encourage the family also, to stay at the bedside if your hospital allows, or to visit frequently.

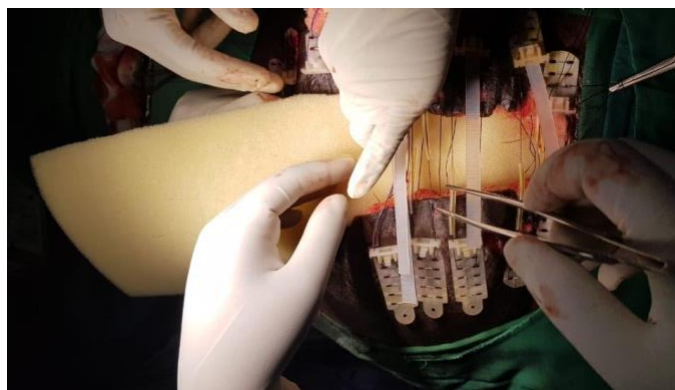As a surgeon you will also find these cases exhausting, especially if you feel that the fistula was caused by an error on your part. Learn what lessons you can from the case. Do not let your discomfort with the patient's condition cause you to avoid them. Ask a more senior colleague for help if you need it. See [Managing Complications Part 1- Yourself](#).

Guide: Closure of Skin Over Open Abdomen by Continuous Traction

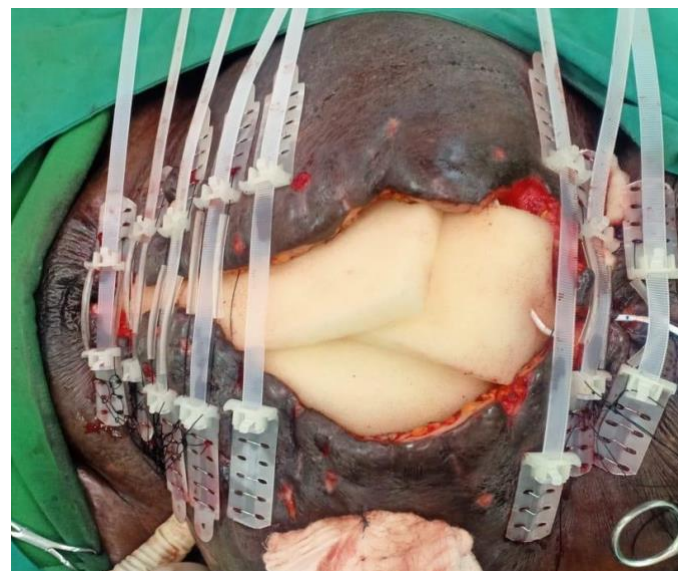
We show a proprietary system, the Top Closure Tension Relief system below. It may be possible to modify ordinary Zip-Ties (used in automotive and other applications) to this purpose. This approach has been well described for closing lower extremity and other wounds after fasciotomy.



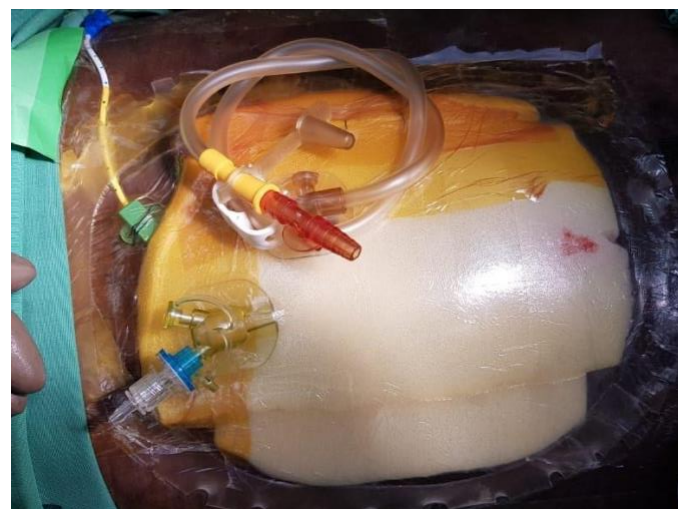A system for closing wounds slowly over time using nylon ratcheting ties. Source: Ahmad I et al, <https://www.doi.org/10.36106/ijsr>



Once the decision is made to treat the wound in this manner, the devices are sutured or stapled to the skin in multiple locations. Shown is the Top Closure Tension Relief system. This system consists of an adhesive plate which both sticks to skin and is sutured to it, placed 2cm from edge and skin staples. The provided straps go between: tightening them a few mm every time the dressing is changed allows the wound to be gradually closed.



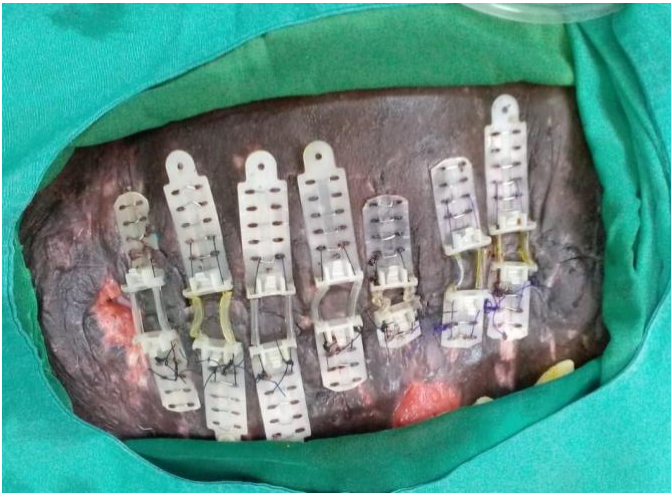The bowel is protected using material that is designed to be in contact with it. As shown in this chapter, petroleum jelly-impregnated gauze is also acceptable. Plain gauze is not. This photo shows commercially made foam that is purpose-designed with one side that is non-adherent. Other options include coating one side of the foam with Tegaderm wound dressing, or applying a plastic sheet such as a cut urine bag, to the bowels.



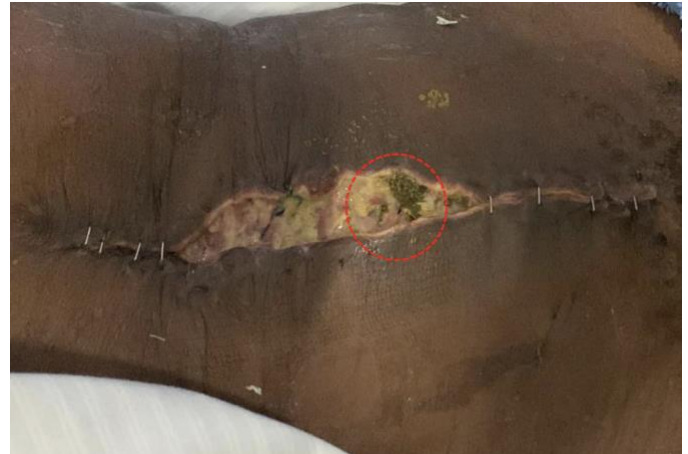The entire assembly can be covered with a negative pressure dressing to control output and keep the wound moist. This is changed every 3-5 days, with the system tightened at the time. Serial changes of the outer dressing with tape and dry gauze are also acceptable, but more labor-intensive.

Management of Open Abdomen and Enteric Fistula

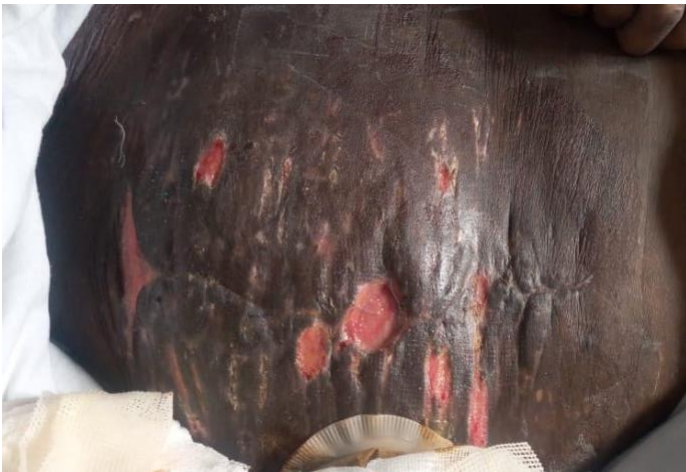Richard Davis, Daniel Moenga, Elizabeth Mwachiro



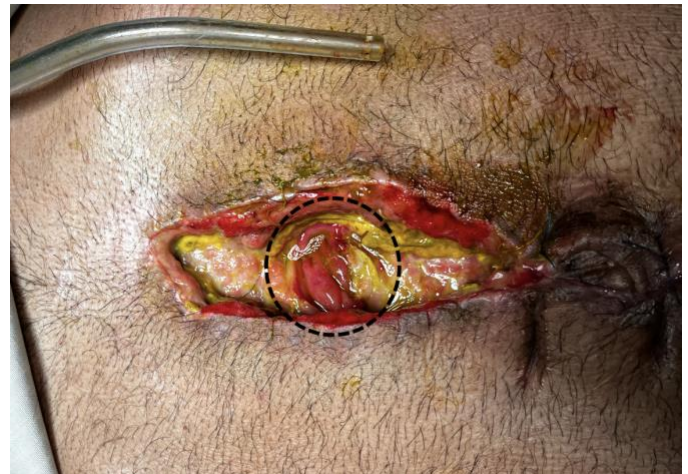The devices are tightened a few mm every alternating day until the skin meets at the midline. At this time the devices can be removed.



This patient with severe malnutrition had wound dehiscence after laparotomy for internal hernia with bowel resection. Enteric contents were seen in the wound in the area inside the Red circle. Our strategy will be to isolate this part of the wound from the rest of it, and to collect the effluent in an ostomy bag.



The final result is a wound that is completely covered in the patient's own abdominal skin, and an incisional hernia underneath.



This patient had an operation for suspected bowel ischemia two weeks after laparotomy for incarcerated incisional hernia. During abdominal entry, an enterotomy was made and the abdomen was found to be "frozen." No attempt at repair was made and the wound was left open. The mucosa of the bowel is clearly visible within the Black circle. We will attempt to isolate it, collect its output, and apply a vacuum dressing to the rest of the wound.

Guide: Fistula Isolation and Negative Pressure Dressing

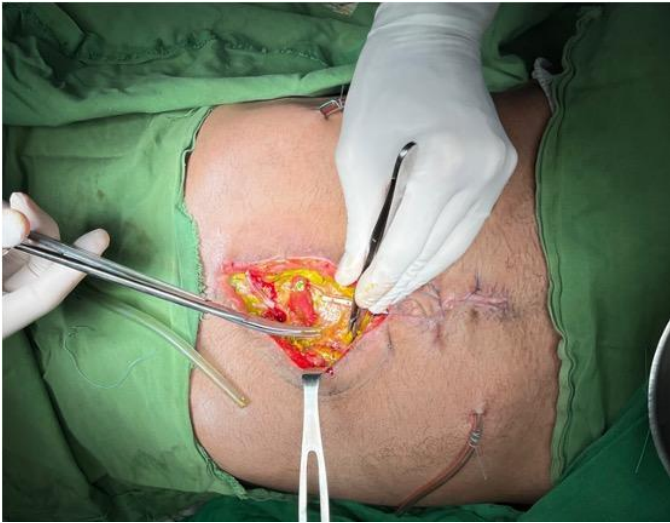It is very important to control the output of the fistula. If leakage gets out of your control, the skin becomes excoriated and further management becomes very difficult: no appliance will stick to the skin. You will have a very painful and messy situation.

Remember that at best, a setup like this will last 2-3 days. The more liquid the output is, the more difficult it is to manage. Some liquid will inevitably sneak around the silicone barrier into the gauze sponge. Once liquid fills the gauze, it will overflow onto the skin and begin irritating it. Change the dressing before this happens!

1. Debride necrotic tissue sharply on the fascia and wound edges. Do not attempt to debride any necrotic tissue directly on bowel.

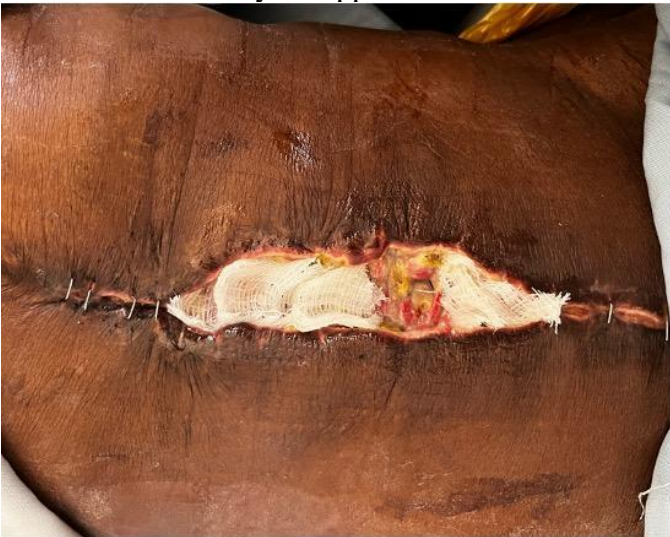Management of Open Abdomen and Enteric Fistula

Richard Davis, Daniel Moenga, Elizabeth Mwachiro



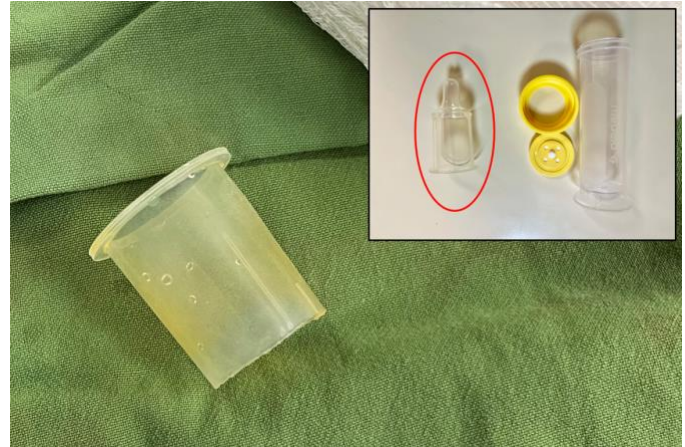The necrotic edges of the abdominal wall are sharply debrided, but no attempt is made to debride the necrotic tissue on the surface of the bowel itself.

2. Apply petroleum jelly-soaked gauze to the exposed bowel, except for the fistula site itself. Leave room for your appliance.



Petroleum jelly-soaked gauze is applied to the exposed bowel, except at the fistula site itself.

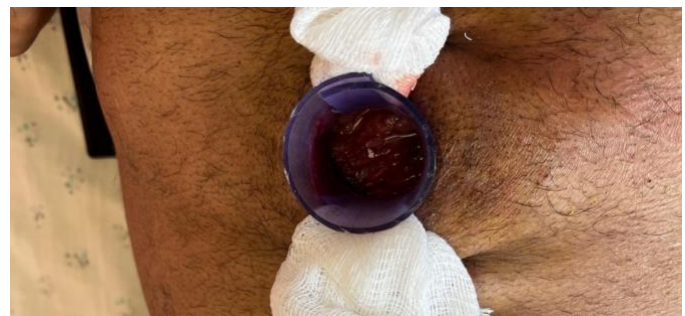3. Apply the appliance directly to the bowel adjacent to the fistula site. Make sure no gauze is under your appliance: it should be applied directly to the bowel, completely outside the fistula site.



For a small fistula opening, a silicone nipple from a feeding bottle for infants with cleft palate (inset, Red circle) is trimmed and used.



For a fistula opening that is larger than the nipple of a feeding bottle, a piece of convex silicone from a pediatric ambu-bag can be cut and used as a "fence" around the fistula site.



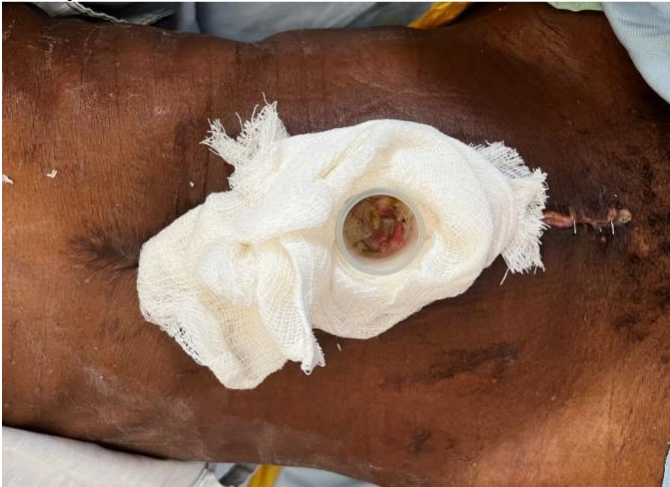The "convex" portion of the ambu-bag above, cut into a strip, used as a "fence" around the fistula. This allows the rest of the wound to be within a suction dressing.

4. Fill the wound with dry gauze. If the fistula is in the center of the wound and you need suction on both sides, use a "bridge" of gauze to one side of the appliance. Alternatively, place closed suction

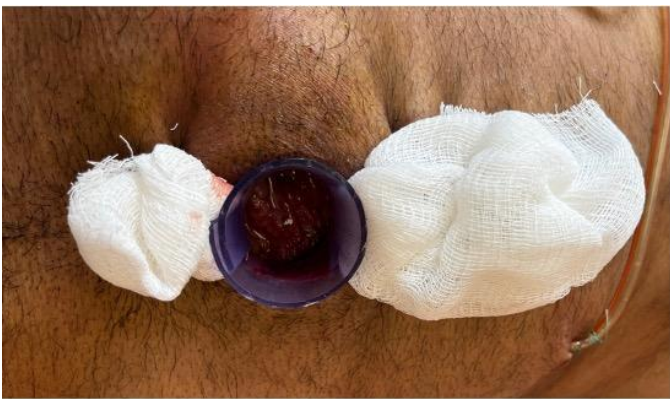Management of Open Abdomen and Enteric Fistula

Richard Davis, Daniel Moenga, Elizabeth Mwachiro

drains through the skin into the wound. Both options are shown here.

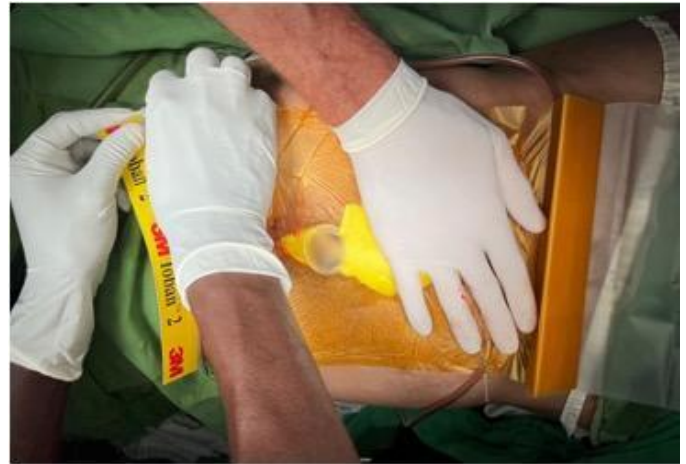

With the baby bottle nipple in place, the rest of the wound is filled with gauze, including a "bridge" around the appliance. The gauze can pass to both sides of the appliance as shown, or to only one side.



Here, closed suction drains under the skin enter the wound on both sides of the silicone appliance, so it is not necessary to leave a "bridge" of gauze around it.

5. Apply the adhesive dressing over the gauze and the appliance. Ideally, the appliance is a little taller than the gauze, so that when suction is applied it will be pressed downward onto the wound.



Holding the gauze and silicone appliance in place, the adhesive plastic dressing is applied.

6. Cut a small hole in the adhesive dressing and insert a trimmed nasogastric tube into the gauze. Cover this junction with a small piece of adhesive dressing.

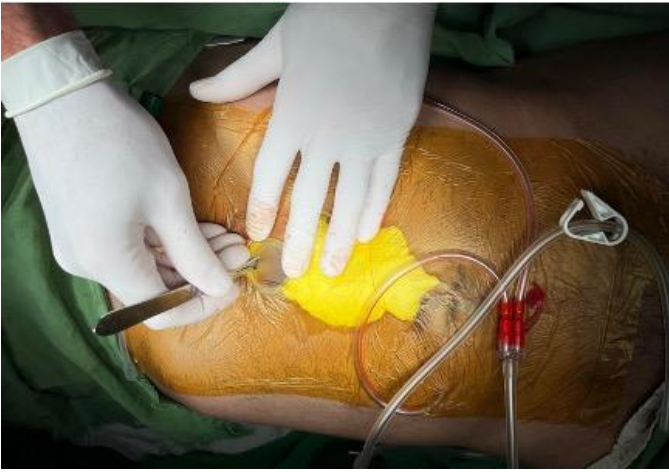

A nasogastric tube is passed through a hole in the adhesive plastic, and then a smaller piece of plastic is used to make this connection airtight. Suction applied to the NG tube will now exert continuous suction on all of the gauze sponge.

7. Trim the part of the adhesive dressing that covers the appliance.

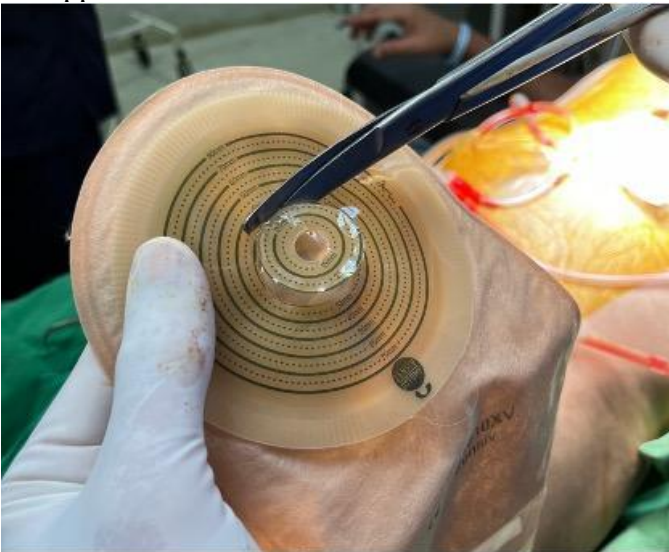
Management of Open Abdomen and Enteric Fistula

Richard Davis, Daniel Moenga, Elizabeth Mwachiro



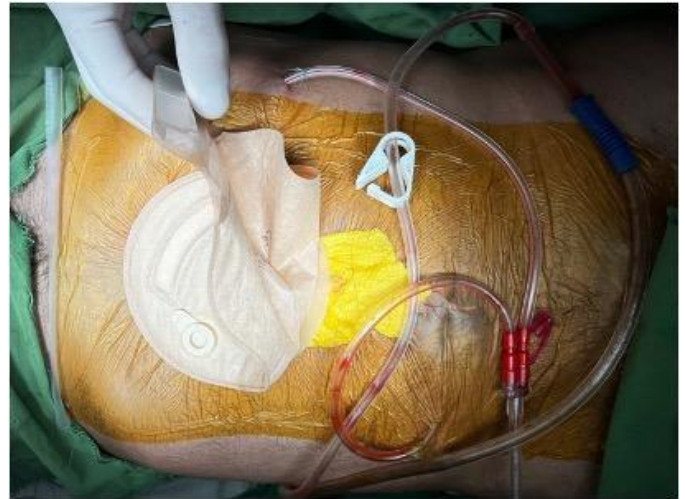With a scalpel or scissors, trim the part of the plastic that covers the silicone appliance, making sure part of it remains adherent to the silicone.

8. Engage suction and confirm that there is minimal leakage around the appliance.
9. Trim the ostomy hole to the size of your appliance.



Measure the size of the hole in the silicone appliance and trim the ostomy wafer to the same size.

10. Apply the ostomy directly to the dressing, over the appliance.



Finally, the ostomy bag is positioned so that it will catch all output from the ostomy.

Richard Davis MD FACS FCS(ECSA)
AIC Kijabe Hospital
Kenya

Daniel Moenga MBBS FCS(ECSA)
Tenwek Hospital
Kenya

Elizabeth Mwachiro MBBS FCS(ECSA)
Tenwek Hospital
Kenya

Resource-Rich Settings

Total Parenteral Nutrition
Octreotide
Wound Vac ® system and “White Sponge”
Teduglutide (Gattex) to promote mucosa growth (in Short Bowel Syndrome) and nutrient absorption