

Intestinal Anastomosis

Richard Davis

Introduction:

In this chapter we present one technique for a hand-sewn bowel anastomosis. There are many ways to anastomose bowel using sutures, staples, or a combination of the two. All successful anastomoses will involve well vascularized tissue, under no tension, with the bowel being inverted, or folded into itself. Our technique is easy to learn, easy to teach, and relatively safe even in inexperienced hands. Please note as you review the pictures that this technique assumes both surgeons sew the inner layer by passing the needle from their left to their right.

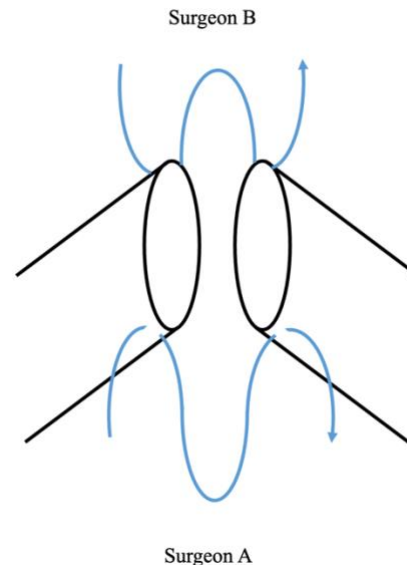
This is the same two layered technique we use for [Billroth 1 gastroduodenostomy](#) after partial gastrectomy, see that chapter for more photos and explanation of the technique.

Two layer, hand sewn intestinal anastomosis proceeds according to the following steps:

- Alignment of the two pieces of bowel with traction sutures
- Posterior outer layer- interrupted
- Posterior inner layer- running
- Anterior inner layer- running
- Anterior outer layer- interrupted
- Closure of any mesenteric defect.

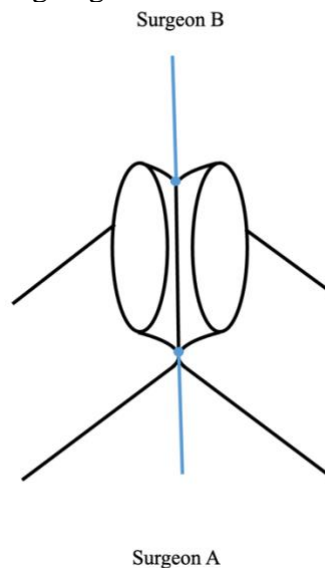
Steps:

1. The two ends of the bowel should not be kinked or twisted- this can be confirmed by aligning the mesenteries of both segments. The two ends should meet with absolutely no tension. Especially when anastomosing the colon, we prefer to see and feel a pulsatile vessel in the mesentery immediately adjacent to the cut edge of the bowel. Place a traction suture through the serosa and muscular layer of the mesenteric and antimesenteric sides of the bowel to align it. If possible, it should be aligned so that the anastomosis will be in a line between the two operators, as shown below:



Traction sutures through the serosa and muscular layer of the bowel on both sides of the anastomosis, on both the antimesenteric (top) and mesenteric (bottom) layers of the bowel. The locations of the two surgeons are also shown here; preferably the anastomosis will be parallel to a line drawn between them.

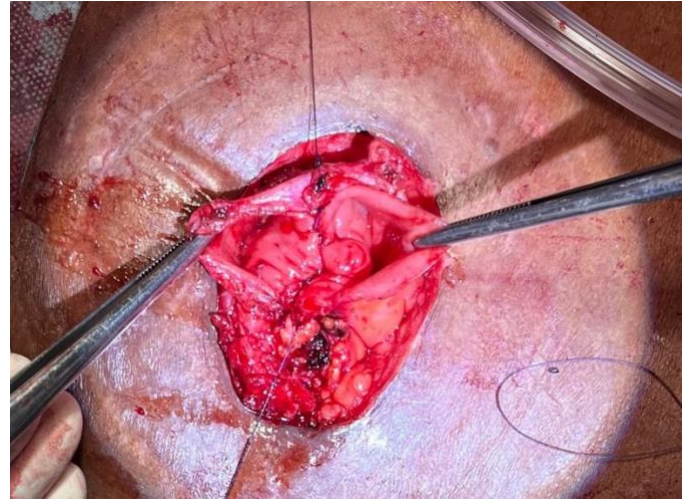
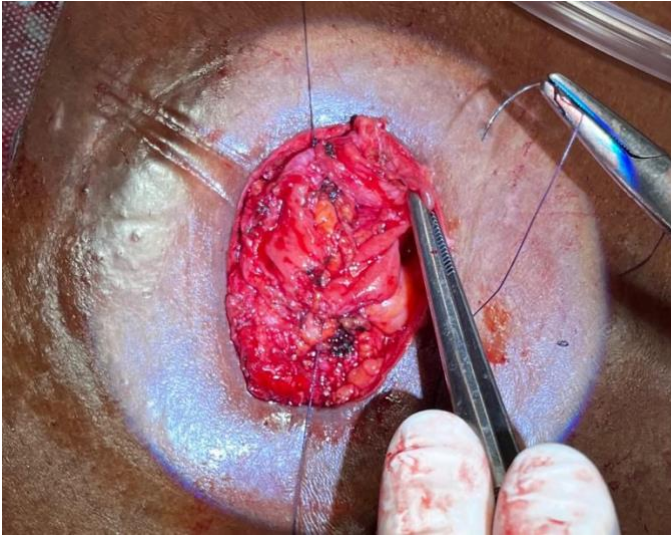
2. Tie the traction sutures and put them on slight tension, aligning the bowel.



Well placed traction sutures will align the bowel so that the two lumens lie next to each other and are ready to be sewn together.

Intestinal Anastomosis

Richard Davis

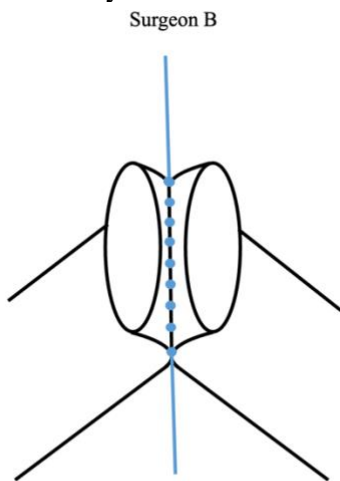


The posterior outer layer is complete and the two lumens of the bowel are aligned and ready for the posterior inner layer.

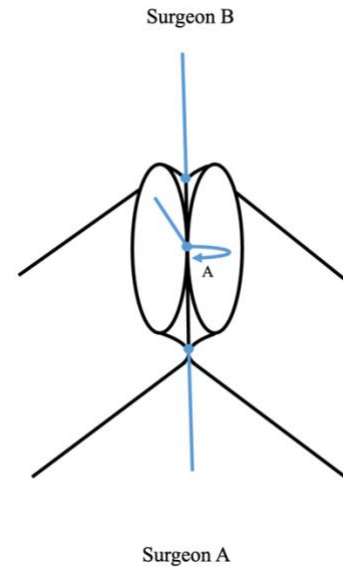
As seen here, the traction sutures hold and align the pieces of bowel that are to be anastomosed. The surgeon is preparing to place the posterior outer layer of sutures, as described further below. These photographs are from the closure of a loop colostomy: both ends of the bowel easily reached the skin, where the anastomosis was performed. Once the anastomosis was complete, it was placed inside the abdomen and the fascia was closed.

4. Surgeon A begins the posterior inner layer of the anastomosis by suturing the mucosa of both sides together, right in the center. Put a hemostat on the other side of the suture, Surgeon B will tie to it later. Surgeon A then sews towards her/himself.

3. Perform the posterior outer layer of the anastomosis, passing the needle through the serosa and muscular layers of the bowel on both sides, aligning it further. We prefer interrupted sutures for this layer.



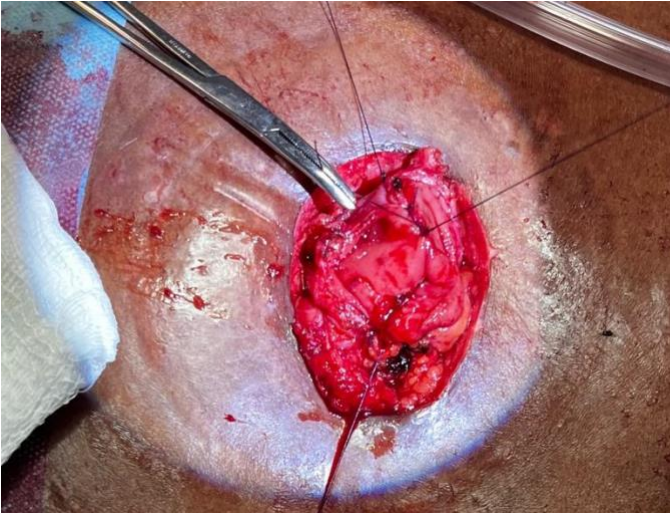
Surgeon A



Place interrupted seromuscular sutures about 3-5mm apart in between the two traction sutures. This is the posterior outer layer of the anastomosis. Either surgeon may perform this step.

Intestinal Anastomosis

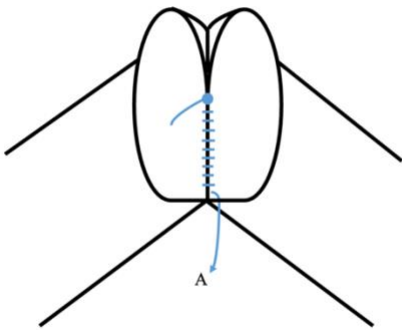
Richard Davis



Surgeon A, standing inferior to this picture, has tied the suture and is about to start a running suture, sewing towards her/himself.

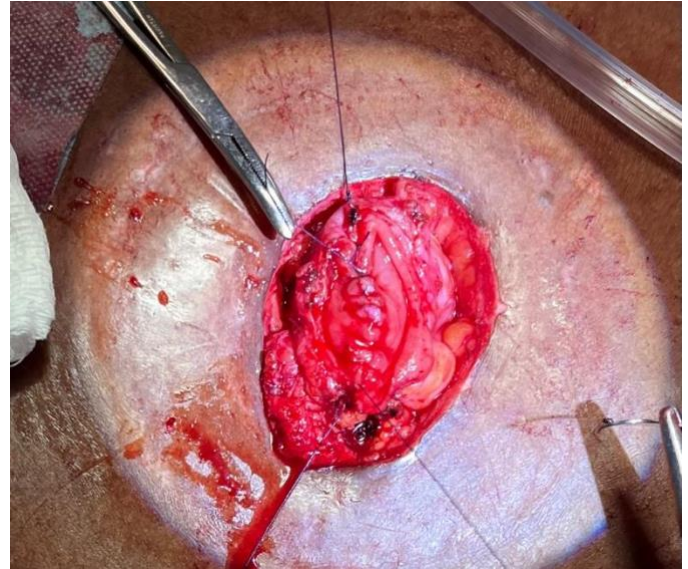
5. Surgeon A continues the posterior inner layer suturing towards her/himself. Once you reach the edge of the bowel, you will pass the suture through each side separately.

Surgeon B



Surgeon A

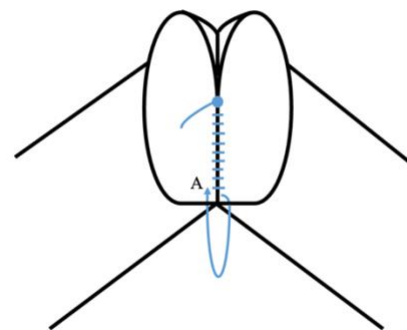
As the running suture nears the edge of the bowel, Surgeon A must be mindful of the orientation of each stitch. This one is passed from inside to outside the lumen of the bowel on Surgeon A's right.



This photo shows that the most recent stitch has been taken on the lumen to the right, from inside out. The needle is now outside the lumen of the bowel, and the next stitch will be from the outside in on the lumen to the left.

6. When surgeon A reaches the edge of the bowel, it is critically important to remember when the needle is inside and when it is outside the bowel. Each pass of the needle will now be separate, going from inside to outside the lumen, and then from outside to inside. Failure to maintain this orientation can result in an anastomotic leak.

Surgeon B

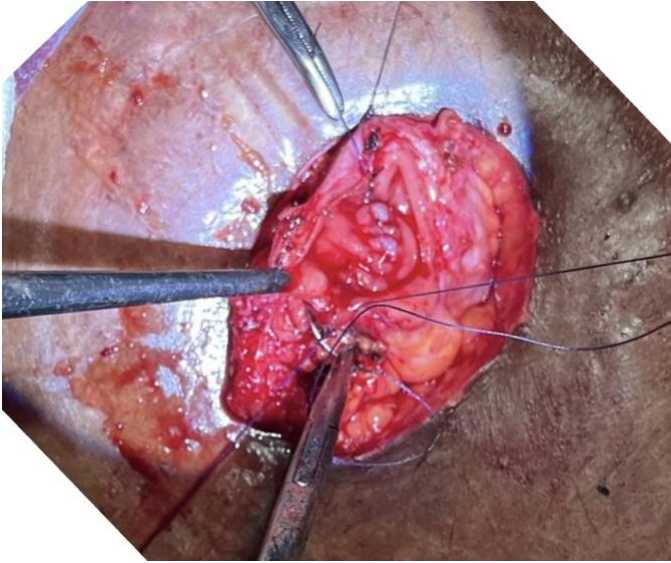


Surgeon A

Surgeon A now passes the needle from outside the lumen to inside on the bowel on the left.

Intestinal Anastomosis

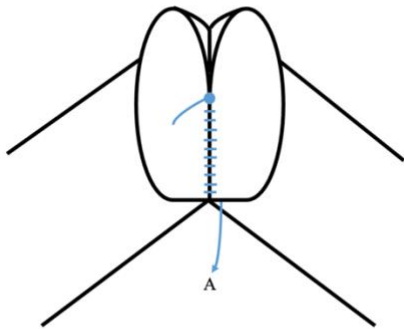
Richard Davis



The needle passes from outside to inside on the bowel on the left.

7. After a few such “corner” stitches, Surgeon A is finished. The suture is left outside the lumen by convention, so that later, when Surgeon B starts suturing with it, it is clear what should be done next. Do not tie the suture at this point.

Surgeon B

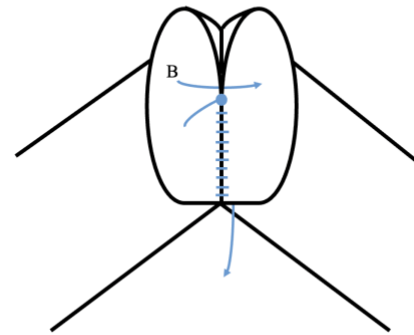


Surgeon A

Surgeon A is finished, having taken 3-4 such stitches and having “rounded the corner.” Do not tie the suture at this point: later on, Surgeon B will continue sewing with this suture towards him/herself, performing the anterior inner layer.

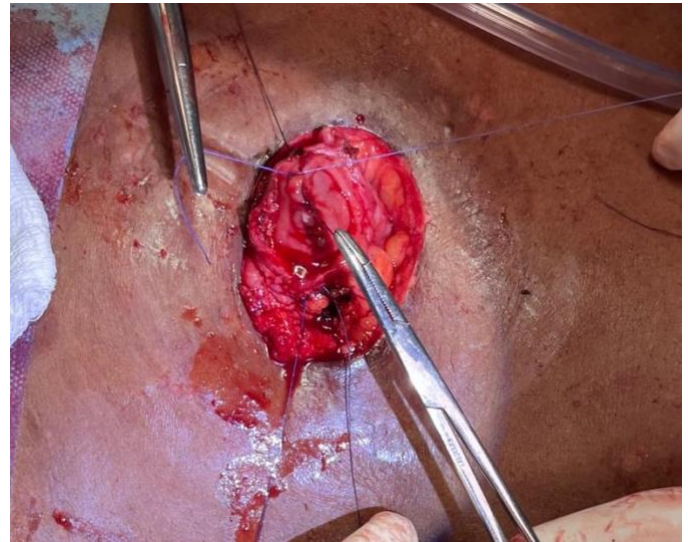
8. Surgeon B then passes another suture adjacent to Surgeon A’s original knot, ties the suture, and then ties to the tail of Surgeon A’s knot.

Surgeon B



Surgeon A

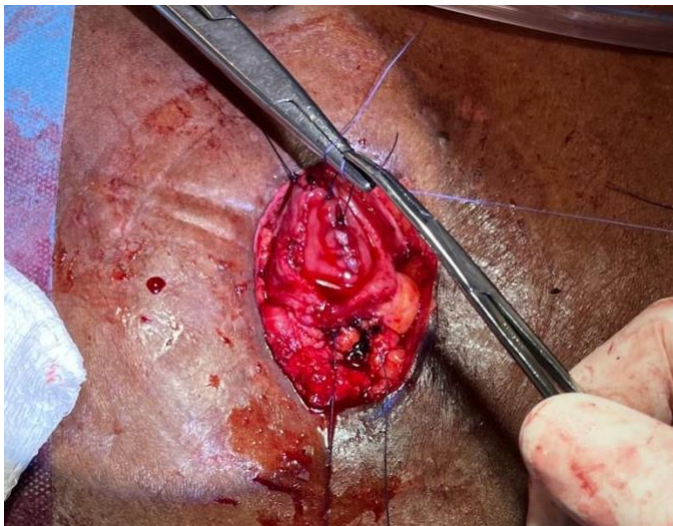
Surgeon B now starts their part of the posterior inner layer, passing the first stitch through the mucosa next to the knot that Surgeon A had tied previously.



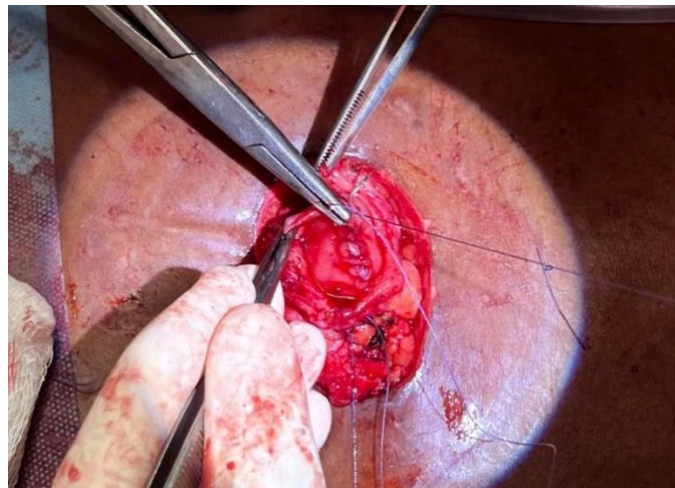
Surgeon B ties the suture to itself. The tail of surgeon A’s suture is held by a hemostat.

Intestinal Anastomosis

Richard Davis



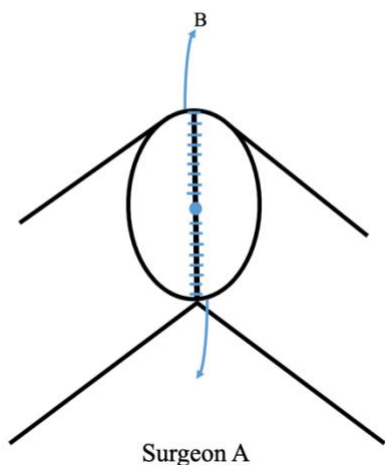
Surgeon B then ties the suture to the tail of Surgeon A's knot, still held by the hemostat in this picture.



Surgeon B continues "rounding the corner" and eventually takes their final bite of the posterior inner layer, passing the needle through the lumen on their right and leaving the suture outside the lumen.

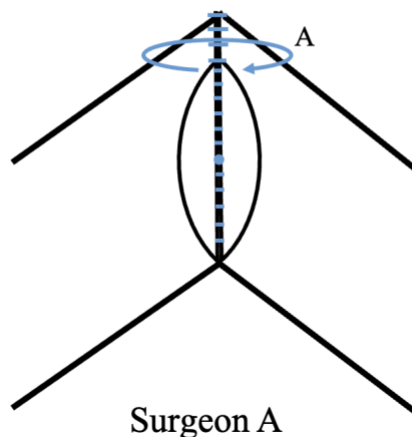
9. Surgeon B then begins sewing towards him/herself, just as Surgeon A did. Upon reaching the edge of the bowel, Surgeon B must also remember to pass the needle inwards and outwards from the lumen, taking the last stitch from inside out.

Surgeon B



10. Surgeon A now takes the needle opposite them (that was previously placed by Surgeon B) and begins sewing the anterior inner layer of the anastomosis, towards her/himself. Be careful during this stage that you see the needle as it passes, so you do not catch the "back wall" of the anastomosis and narrow it.

Surgeon B

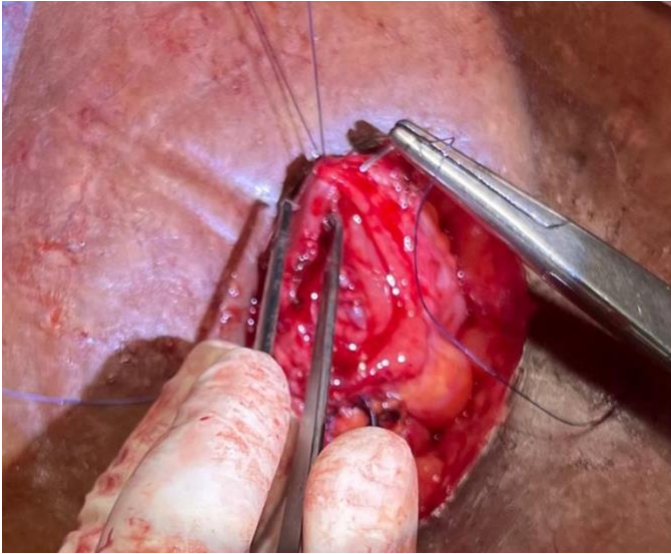


Surgeon B now sews their portion of the posterior inner layer, obeying the same rules as described above. For Surgeon B, standing opposite the viewer in this picture, the needle passes inside-out on the side that is on their right, as shown above. Surgeon A will now take this needle and begin the anterior inner layer of the anastomosis.

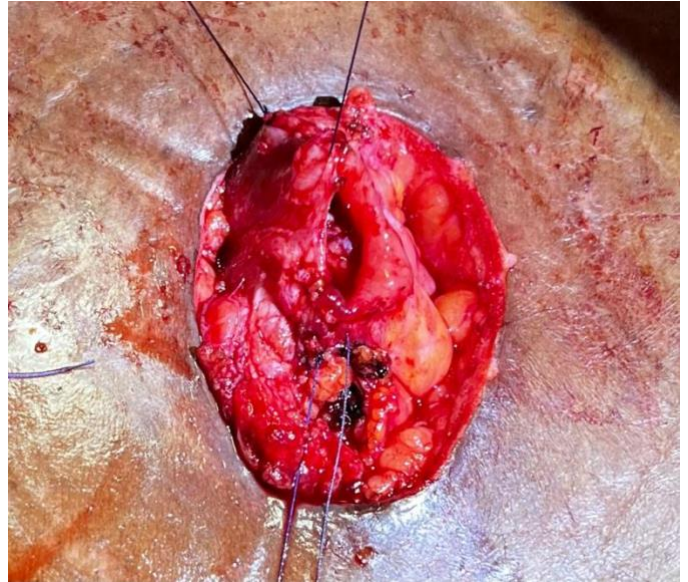
Surgeon A is now sewing the anterior inner layer, using the needle that Surgeon B just finished with. The needle continues in the same orientation of "outside-in, inside-out" that Surgeon B was doing. If this transfer was done correctly, the direction and inside-out orientation of the needle is unchanged.

Intestinal Anastomosis

Richard Davis



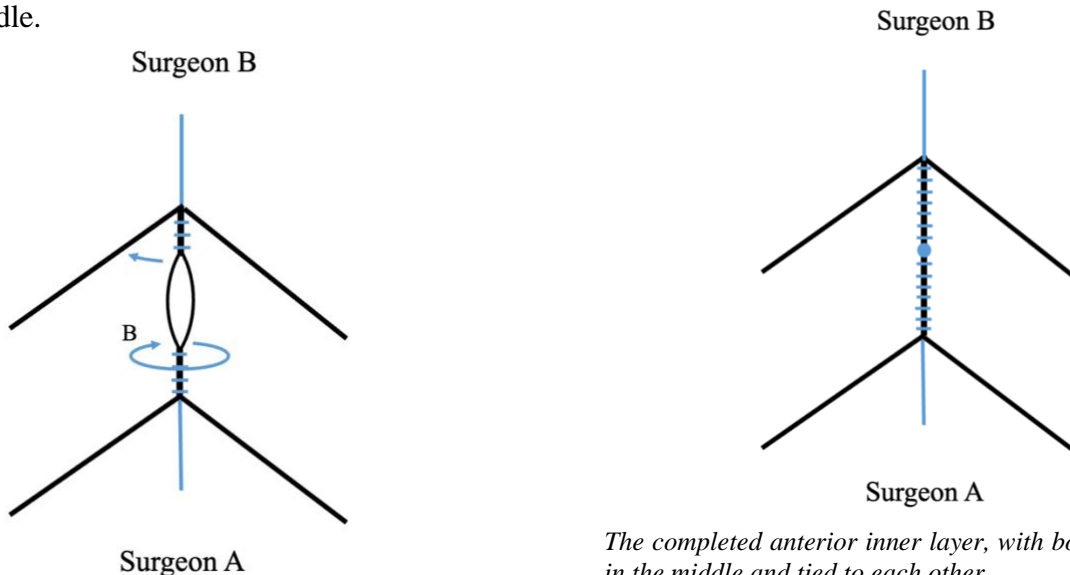
Surgeon A is now sewing the anterior inner layer, using the suture that Surgeon B has just finished with.



Surgeon B is sewing towards him/herself and finishing the anterior inner layer of the anastomosis.

11. Once Surgeon A has reached approximately the center of the bowel, Surgeon B takes the opposite needle (previously placed by Surgeon A in step 7) and starts sewing towards themselves. As the remaining defect becomes smaller, it becomes easier to inadvertently catch the “back wall” with your needle.

12. Once the two needles meet in the middle, they should be on opposite sides of the bowel. They are then tied to each other (by either operator,) finishing the anterior inner layer of the anastomosis.

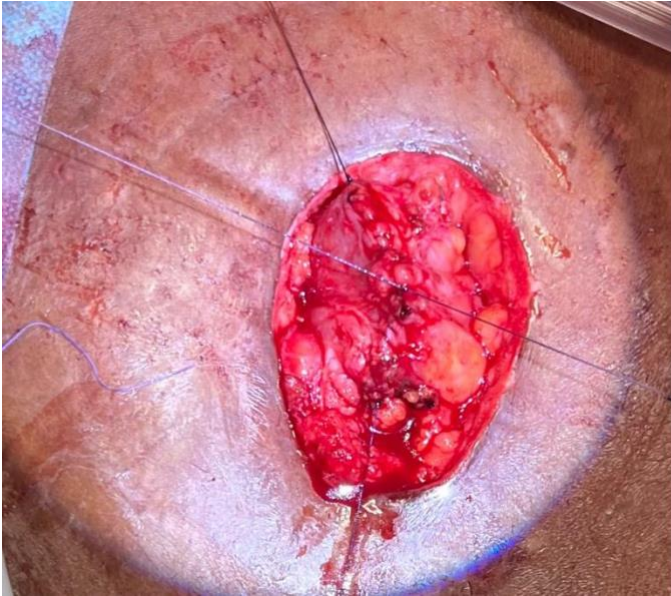


Surgeon B has taken the needle left by Surgeon A (in Step 7) and started sewing, towards him/herself, the anterior inner layer of the anastomosis.

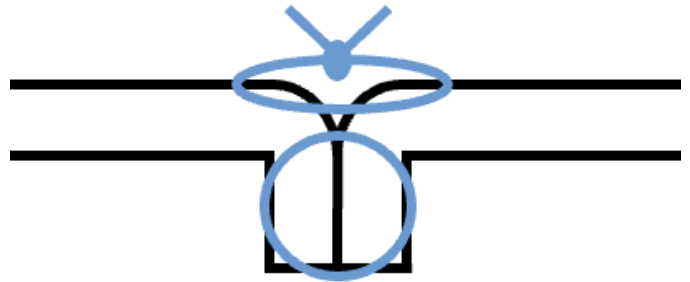
The completed anterior inner layer, with both sutures meeting in the middle and tied to each other.

Intestinal Anastomosis

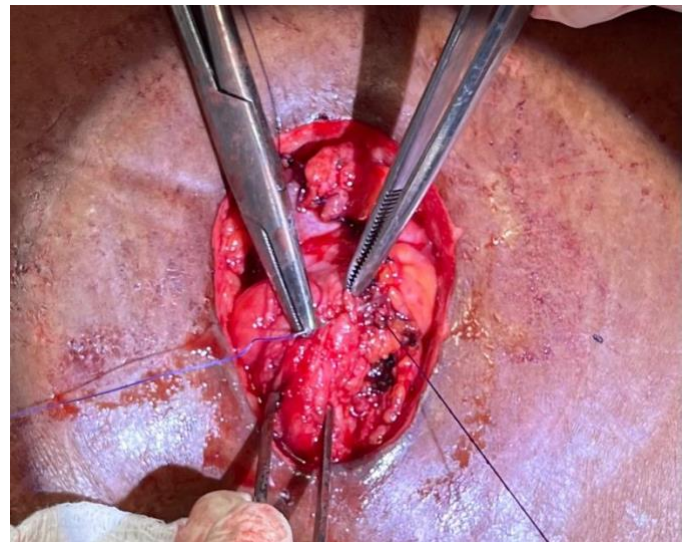
Richard Davis



Appearance of the bowel after the anterior inner layer is complete. The next step is to completely bury this suture line, just as the posterior inner layer was “buried” by the posterior outer layer in Step 3

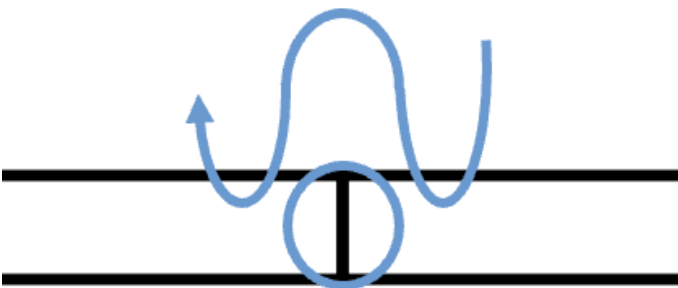


Once the Lembert stitch is tied, the previous suture line becomes inverted, as shown.



It may be tempting to take both bites with a single pass of the needle at this point, but the inversion of the suture line will be more complete if each bite is taken separately.

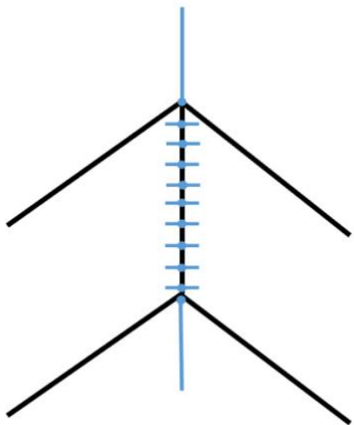
14. These interrupted sutures are placed 3-5mm apart, on the anterior aspect of the anastomosis all the way between the two traction sutures.



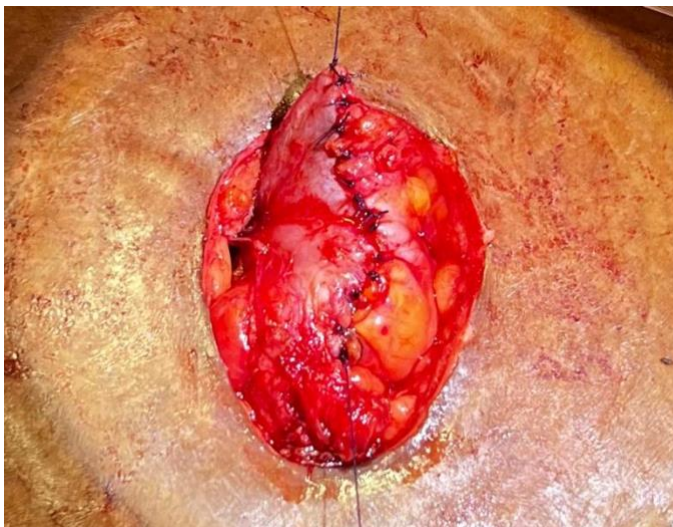
A bite of serosa and muscularis is taken from either side of the suture line. Each bite is taken with a separate pass of the needle, making it more likely that the suture line will be “buried.”

Intestinal Anastomosis

Richard Davis



Once all the Lembert sutures have been placed, there will be a continuous line of these sutures between the two traction sutures. The suture line of the inner layer is completely covered and inverted by the outer layer.



The anastomosis is now complete, with two separate layers of sutures making an anastomosis that is inverted on itself circumferentially.

15. A defect in the mesentery will often remain. Close this with interrupted sutures, taking care not to encircle and ligate any blood vessels that are supplying the anastomosis.
16. Postoperative care includes allowing the patient to take clear liquids and awaiting flatus. Continue IV fluids during this time, as the patient will not be able to keep hydrated until gastrointestinal function resumes. Some surgeons will advance the diet beyond clear liquids before the patient passes flatus. Doing so has no effect on the anastomotic leak rate at all, but patients will not

tolerate much intake by mouth until all of their GI tract has awakened.

17. Generally, patients will restrict their own feeds until they are ready to eat. No feeding strategy has proven to be superior as long as pain is well controlled and hyperglycemia, hypoxia, and hypotension are avoided. However, patients who are confused or otherwise not mentally competent should not be given unlimited food or drink, as they may overeat and vomit.

Pitfalls

- Any technical error, especially not remembering the orientation of the needle relative to the lumen, may result in a leak. You may even choose to say out loud the words, “Outside in” and “Inside out” as you pass the needle, to help yourself remember which one you did last.
- Some surgeons like to manipulate the bowel, “pinching” the lumen to be sure that it is patent. We prefer not to manipulate the anastomosis excessively once it is complete. If you carefully follow these principles you will not need to “verify” anything once you are done.
- Recognizing an anastomotic leak can be very difficult. The signs can be very subtle. We discuss this matter further in [Recognizing Postoperative Intra-Abdominal Sepsis](#).

Richard Davis, MD FACS FCS(ECSA)
AIC Kijabe Hospital
Kenya

January 2023