

# Brachial-Cephalic Arteriovenous Fistula Creation

Jerry Svoboda, Richard Davis

## Introduction:

Brachial-Cephalic Arteriovenous fistula is the preferred option for patients who have no useable veins in their distal forearm, or who have failed fistula creation there. The cephalic or medial antecubital veins are reliable in this area. They must be evaluated for suitability though, as this is a favorite area for venipuncture and IV's.

This procedure can and should be done under local anesthesia, due to perioperative risks of general anesthesia in patients with renal disease. If the patient is already receiving dialysis, surgery is done on a non-dialysis day.

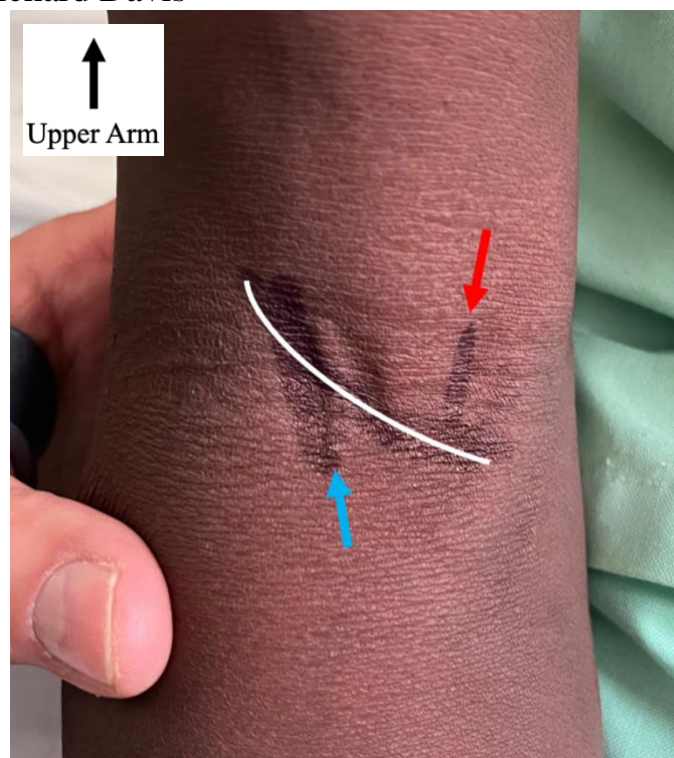
Meticulous attention to detail is needed for success. As with all vascular anastomoses, poor attention to detail or hasty, "ham-fisted" technique will lead to a poor result. An acceptable failure rate is 10% despite the best technique. While you are learning this operation, take notes on each procedure you do and track your patency rate. This will allow you to refine your technique.

Brachial-Cephalic fistula formation proceeds in the following steps:

- Careful evaluation of the patient's superficial venous and arterial systems and marking of the planned surgical site.
- Incision, exposure, and dissection of the cephalic vein
- Exposure of the brachial artery
- Confirmation that the vein will reach the artery and further mobilization if necessary
- Systemic administration of heparin and clamping of vessels
- Tailoring of the artery and vein for anastomosis
- Anastomosis
- Confirmation of patency and closure

## Steps:

1. The venous and arterial system must be evaluated carefully. Vein(s) and the arterial pulsation are marked and the planned incision is indicated. Local anesthetic with epinephrine is infiltrated intradermally only, to avoid the possibility of injury to the vein, which may be very superficial at this point.

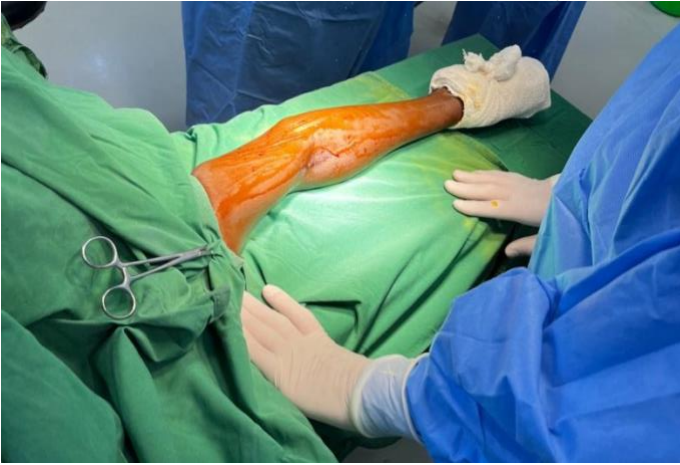

*The right antecubital fossa has been examined and marked. The upper arm and shoulder are up in the photo. The line shown by the Blue arrow indicates the cephalic vein, which is visible and palpable after application of the phlebotomy tourniquet. This vein often extends laterally as it runs in a cranial direction, upwards and towards the left in this photo. The line shown by the Red arrow is the brachial artery location, as assessed by palpation. This is just medial to the biceps tendon, which is also palpable in the antecubital fossa. The white line is the planned incision, extending transversely across the elbow crease and then superiorly up the lateral aspect of the upper arm.*

2. A wide and stable operating armboard is used. Alternatively a narrow table is brought next to the operating table. The regular armboards may not be stable enough, though using two of them together on the bed rail may be an option. The arm is prepared and draped from the axilla to the wrist, using betadine rather than chlorhexidine or alcohol-based prep, to avoid erasing the lines that have been drawn.

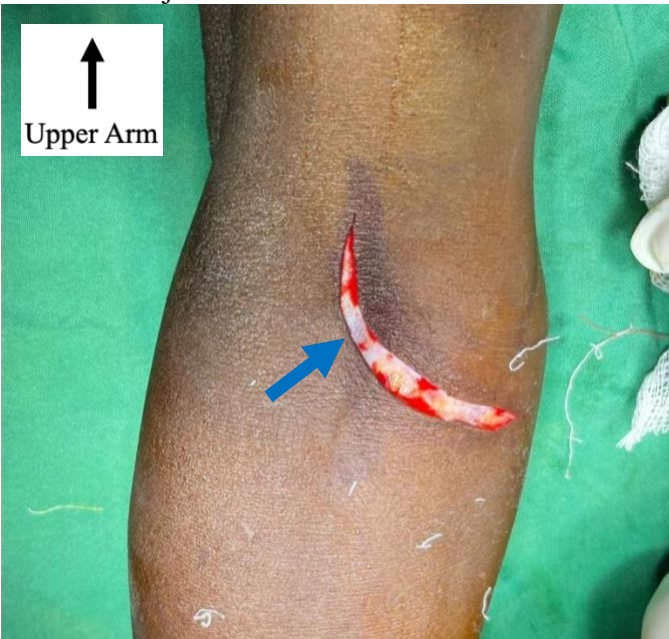
# Brachial-Cephalic Arteriovenous Fistula Creation

Jerry Svoboda, Richard Davis



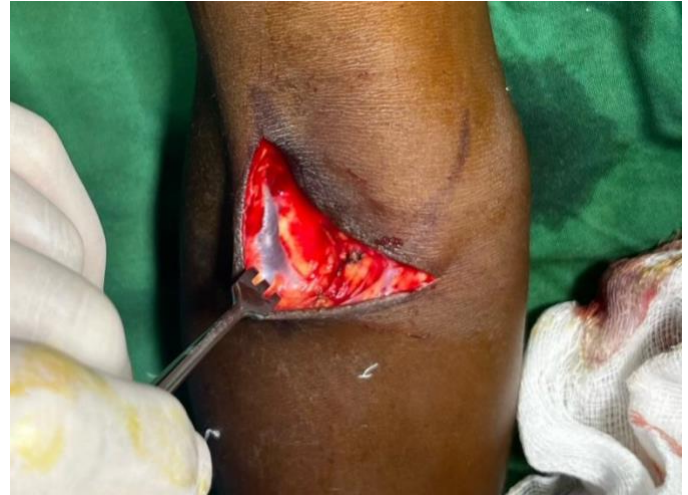The arm is prepared with iodine-based prep.

3. A curvilinear incision is made through the epidermis and dermis in a controlled fashion. In many cases the vein is adherent to the dermis and can be injured with a careless incision.



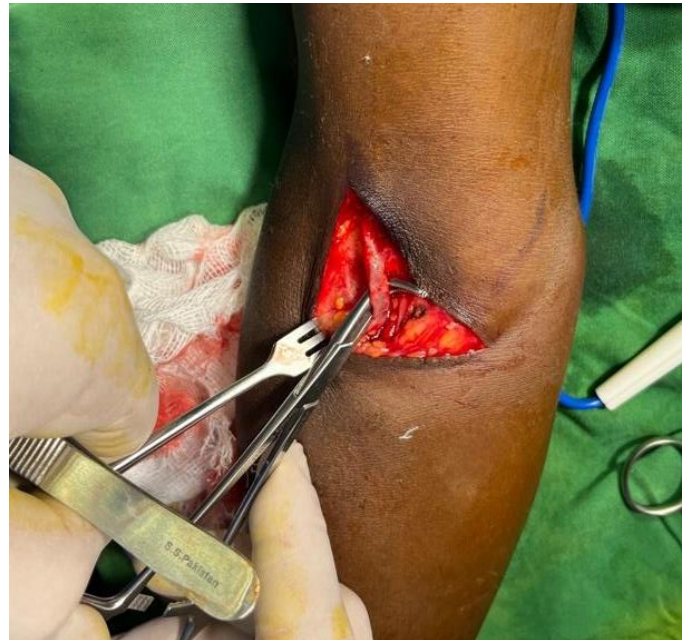
Right arm incision, upper arm and shoulder are up in this picture. The incision is made carefully, in layers, with adequate retraction, through the epidermis and then through the dermis. The cephalic vein is just below the dermis, visible as a blue shadow on the left (lateral) aspect of this incision (Blue arrow.) Note that the arm is rotated more medially in this photo than the following photos.

4. With the vein in sight, careful dissection continues through the remainder of the dermis, which is dissected off the vein.



The vein becomes more visible during careful dissection in a cranial and caudal direction.

5. The vein is encircled carefully with a right angle clamp and a vessel loop is passed around it. Traction on this vessel loop is then used to retract the vein during further dissection. There are often many tiny branches, which must be individually dissected and ligated with 4-0 silk, otherwise these will leak when arterial pressure is applied to the vein.

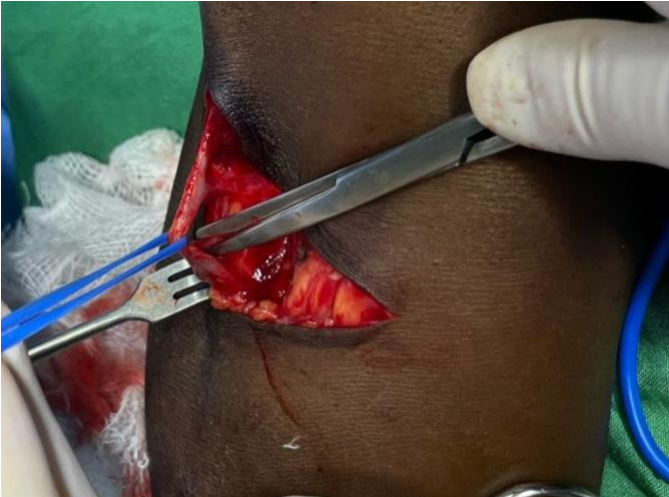

Once dissection is sufficient, a right angle clamp is used to pass a vessel loop around the vein.

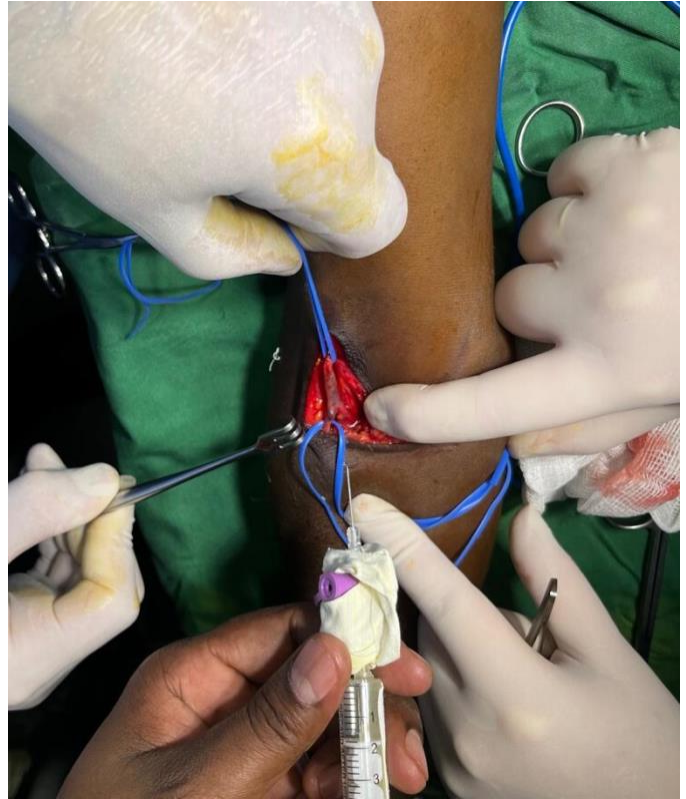


## Brachial-Cephalic Arteriovenous Fistula Creation

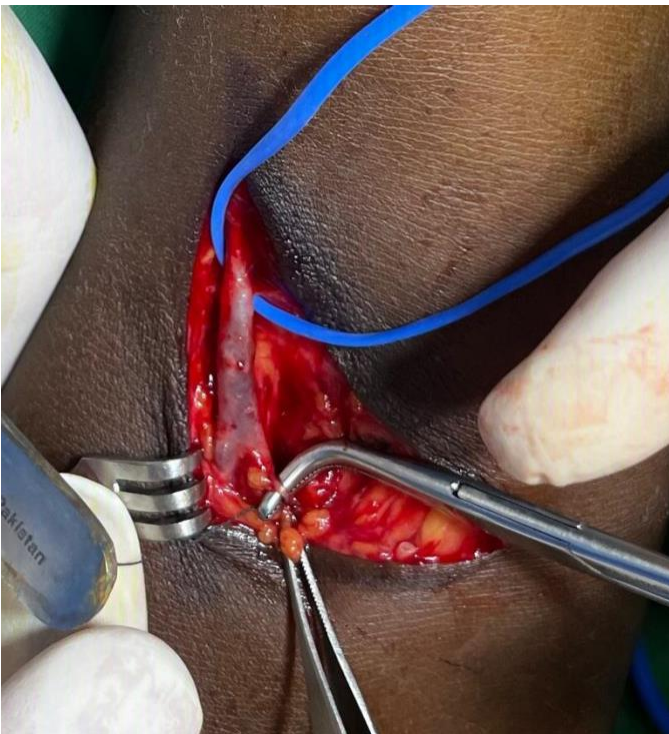
Jerry Svoboda, Richard Davis



*The assistant places traction on the vessel loop while the surgeon continues the dissection. .*



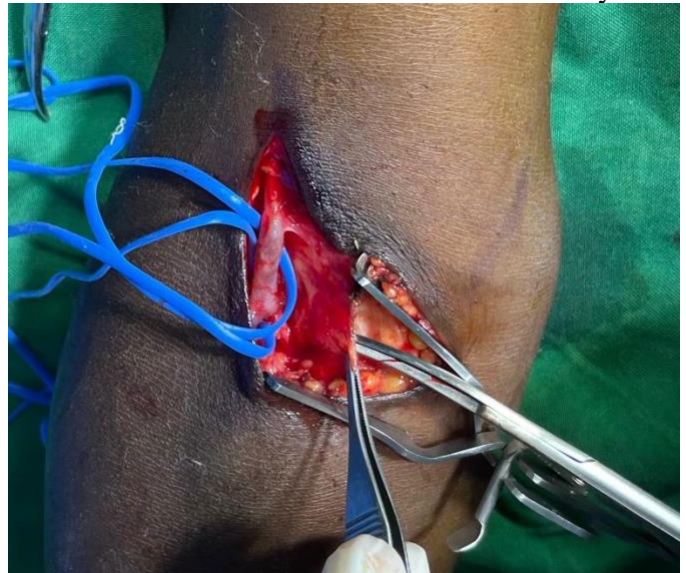
*Papaverine is applied periodically by a non-sterile assistant to relieve spasm of the vein.*



*Side branches of the vein, no matter how small, must be dissected and ligated.*

6. Undiluted papaverine HCl is applied to the vein throughout the dissection, to help it dilate. This can be done by a non-sterile assistant who dispenses drops at a time through an intravenous cannula, to economize the medication.

7. Attention is now turned to the brachial artery. Two layers of fascia must be passed. The first is the fascial tissue that envelops the upper arm. This is located just underneath the subcutaneous fat. Divide it with scissors or electrocautery.



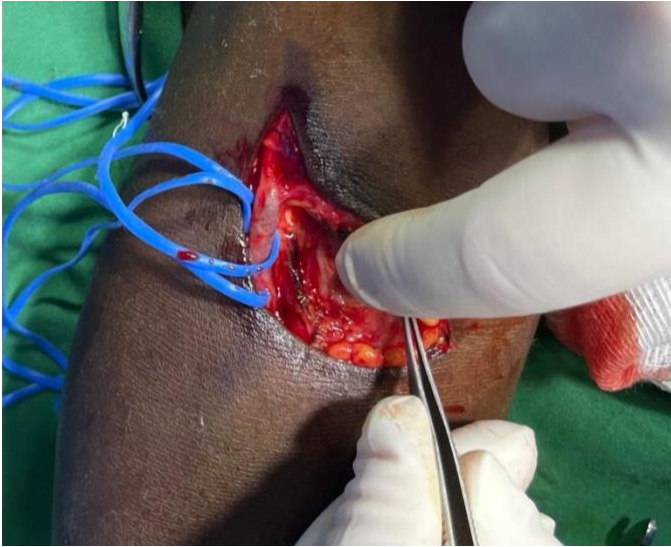
*The fascia of the upper arm is divided to reveal a small amount of fat covering the bicipital aponeurosis.*



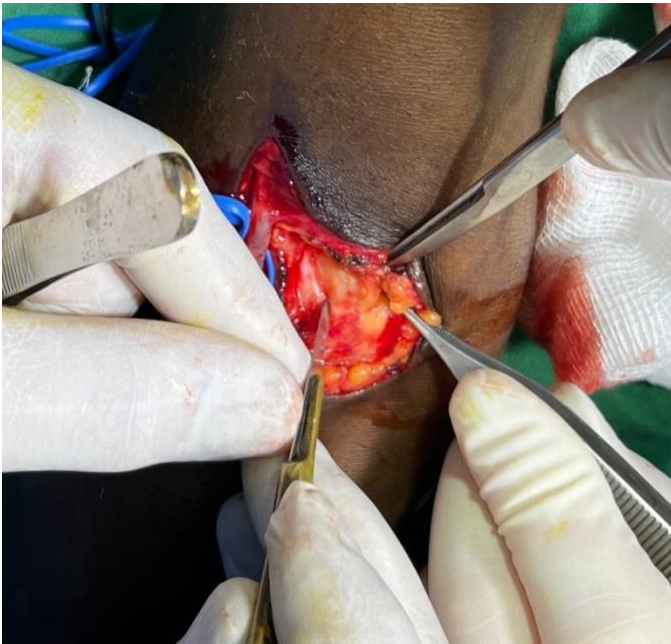## Brachial-Cephalic Arteriovenous Fistula Creation

Jerry Svoboda, Richard Davis

8. The brachial artery can now be more easily palpated through the bicipital aponeurosis. Feel this structure, clear any fat, and then divide the bicipital aponeurosis. Be careful here as the artery may be either medial to it or directly underneath. It is acceptable to make a cruciate incision, a notch from the medial side, or to even excise a “window” of the aponeurosis, as this structure is not essential to arm function.

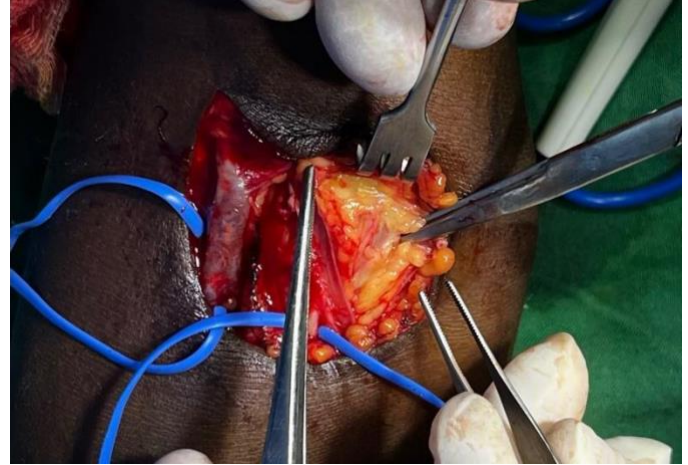


*The artery is palpated after the superficial fascia is divided, to help decide where to cut the bicipital aponeurosis.*

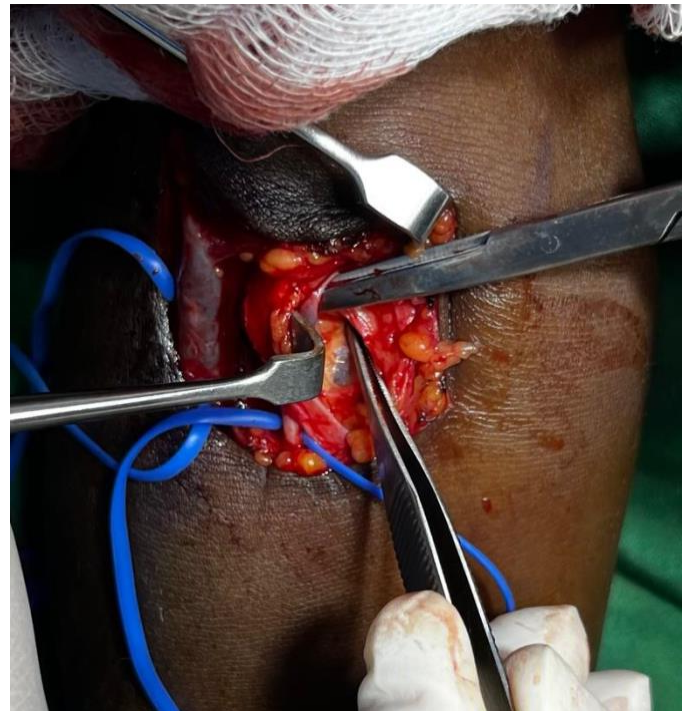


*The bicipital aponeurosis may be a thick structure. The artery may be directly underneath so it is divided in a controlled fashion, first with a scalpel and then with scissors.*

9. Gently dissect the fat below the divided bicipital aponeurosis. Palpate periodically as you search for the brachial artery. Be careful, there are veins running next to the artery and bleeding can be difficult to control if they are cut.



*The deep fat of the antecubital fossa is gently dissected searching for the brachial artery.*



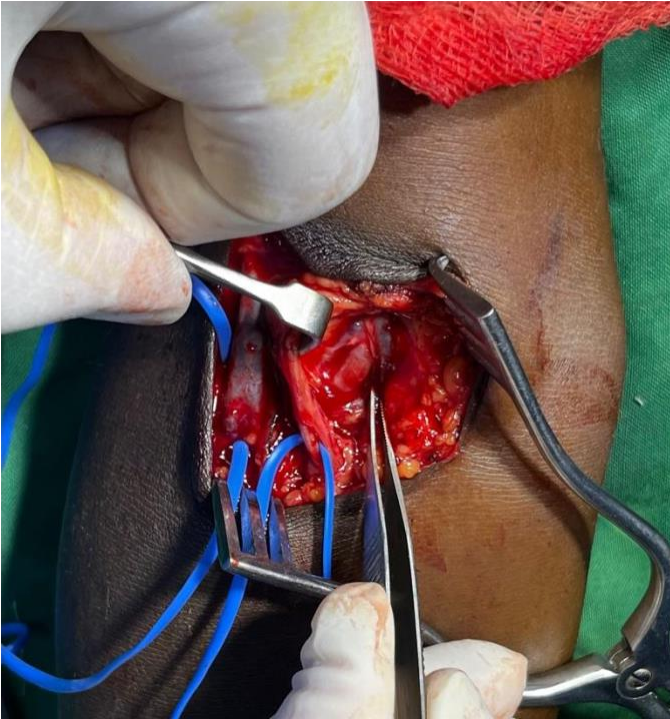
*Inevitably there are one or two large veins running adjacent to the artery, often these are seen before the artery itself.*

10. Once the artery is seen, dissect it carefully and encircle it with a vessel loop. This allows further dissection of the artery. Take care not to injure the adjacent veins. Do not use electrocautery here to avoid injury to the median nerve.

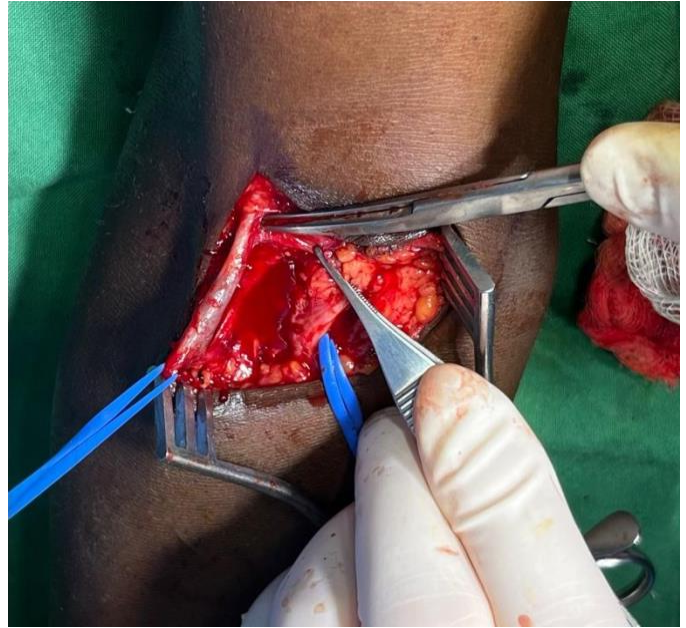

## Brachial-Cephalic Arteriovenous Fistula Creation

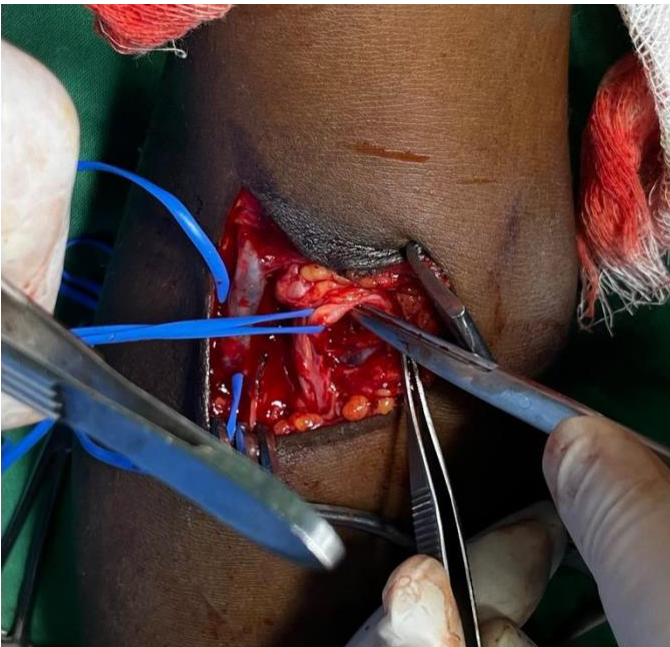
Jerry Svoboda, Richard Davis



*The brachial artery is clearly seen in the base of the incision. The adjacent veins have been dissected free.*

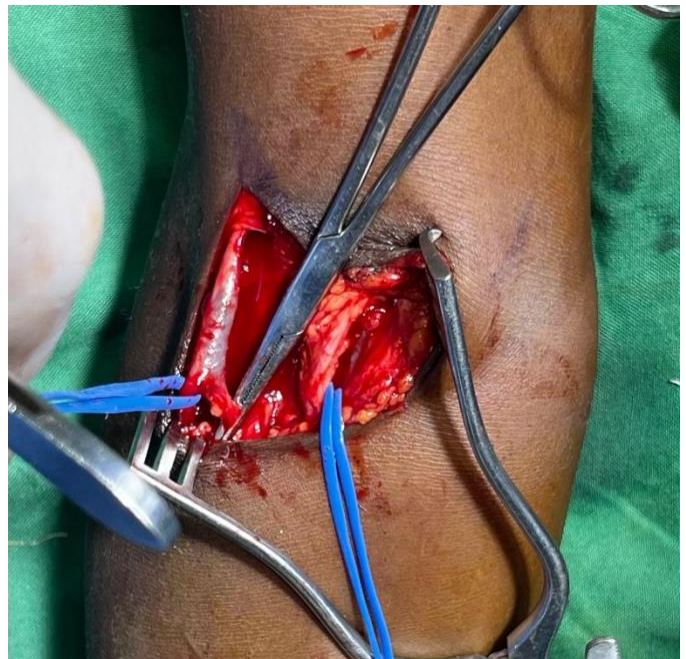


*Further dissection of the proximal and distal aspect of the cephalic vein will allow it to reach the brachial artery.*



*Once the artery is encircled by a vessel loop, gentle traction on the loop allows further dissection and mobilization of the artery. A second vessel loop is placed after further dissection.*

11. Mobilize the cephalic vein further to be sure it will reach the dissected brachial artery without tension. Prepare the distal end of the vein for division.



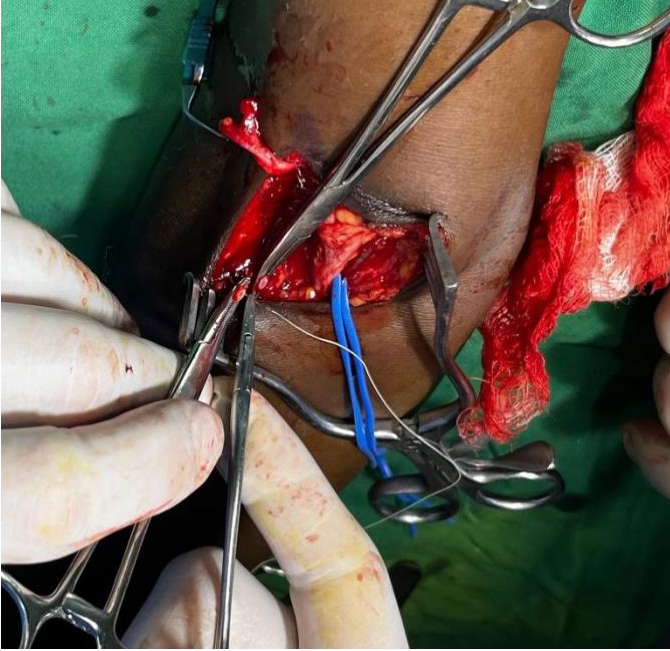
*The cephalic vein branches distally in this case. The surgeon will divide both branches and use the junction point to make a "hood" for a wide anastomosis.*

12. Once it is adequately mobilized, apply a Diethrich (fine Bulldog) clamp to the proximal end of the cephalic vein. Doubly divide and ligate the distal end. Take care here, slippage of the distal tie would result in a hematoma and possible loss of the fistula.



## Brachial-Cephalic Arteriovenous Fistula Creation

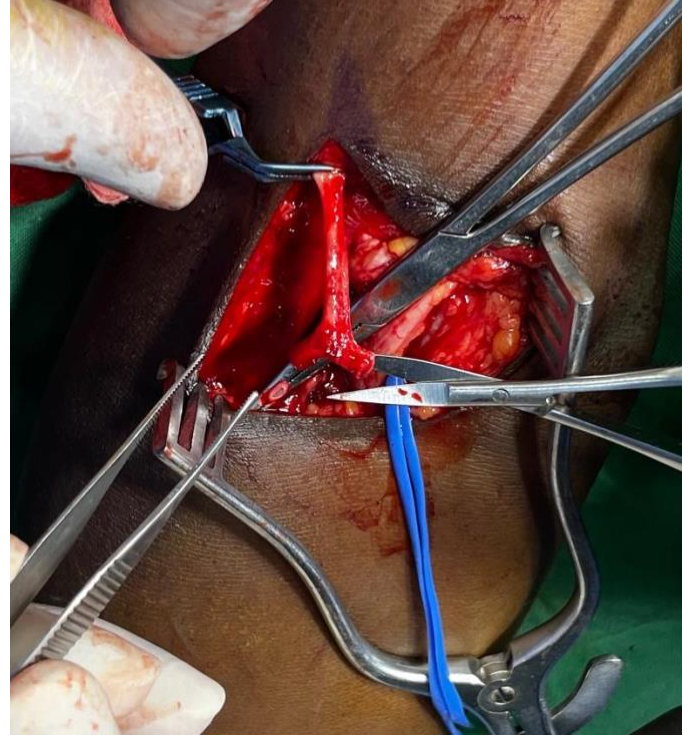
Jerry Svoboda, Richard Davis



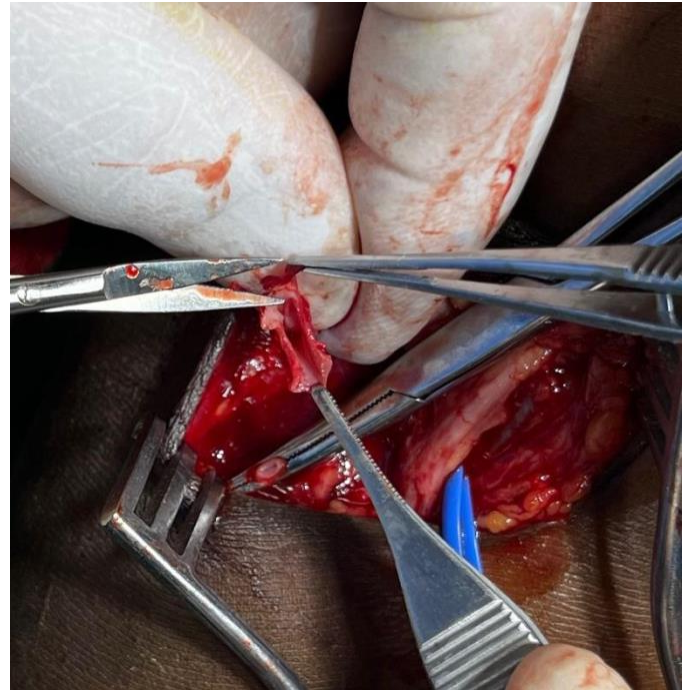
*After division of the cephalic vein, the distal end is first ligated and then suture-ligated to prevent a postoperative hematoma.*

*Back bleeding from the vessel is not usually a problem, but the Diethrich clamp helps preserve its orientation.*

13: Optional: If the distal vein is divided near a branch point, this area can be tailored to allow the surgeon to control the width of the anastomosis. An incision is made through the “confluence” of the branch point which results in a widened part of the vein, whose width can be controlled as needed later during the anastomosis.



*The confluence, the place where the vein divides, is cut.*



*After the division of the vein has been cut, the two branches can be splayed open, resulting in a widened area that can be tailored as needed to the width of the anastomosis.*

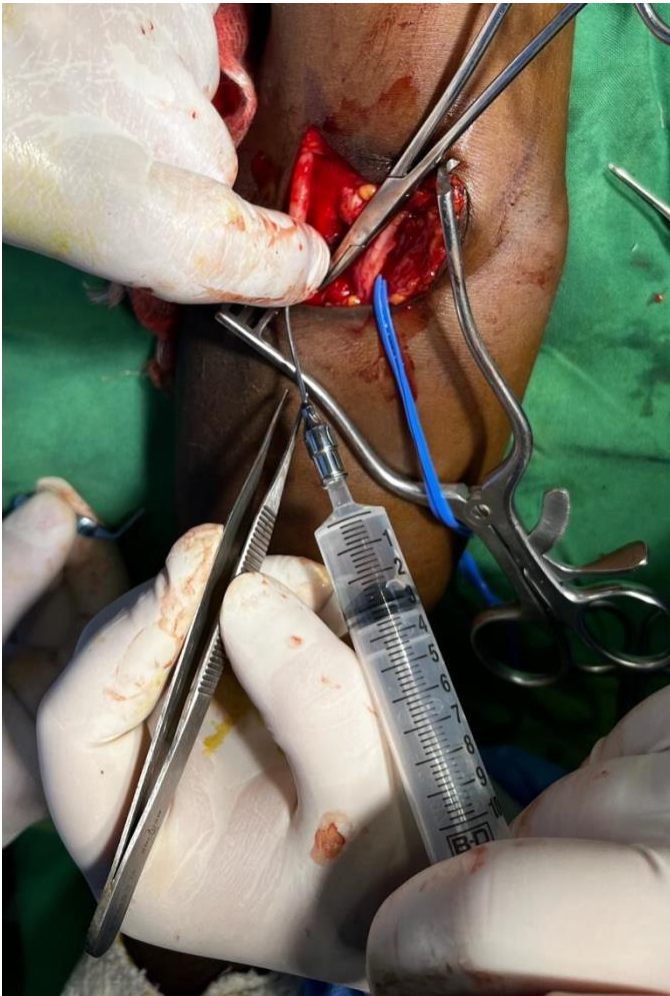14. Verify the patency of the vein and its capacity for flow by inserting the olive-tip catheter and injecting heparinized saline. 1cc should easily pass within



## Brachial-Cephalic Arteriovenous Fistula Creation

Jerry Svoboda, Richard Davis

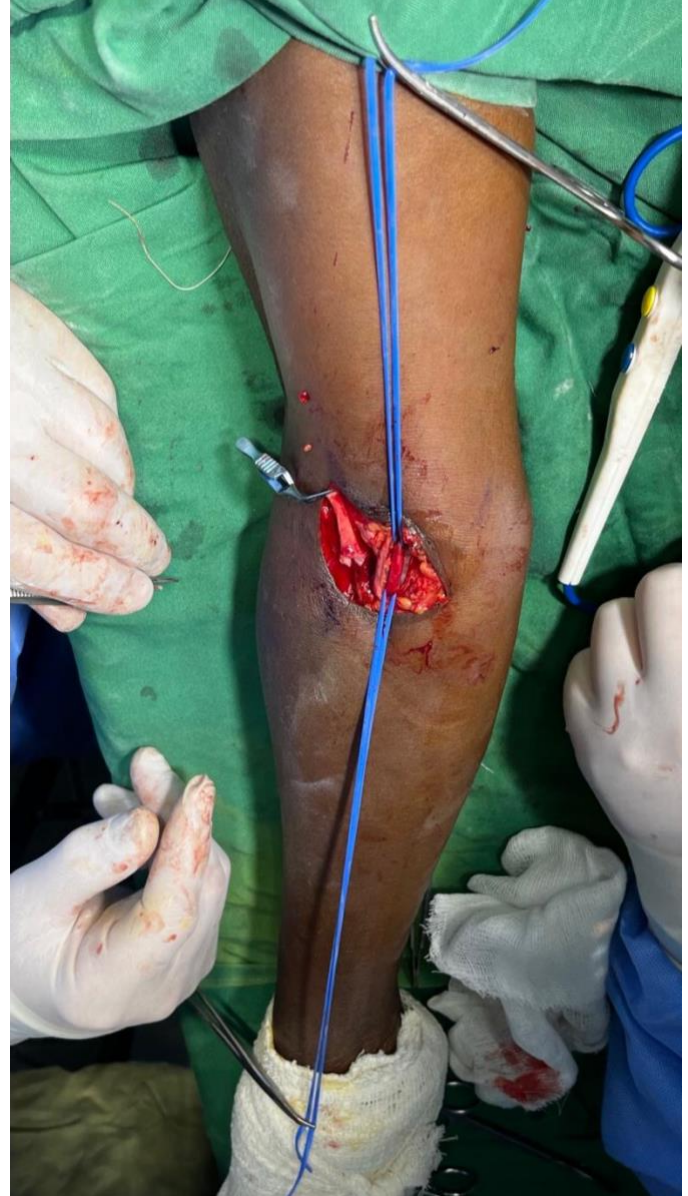each 1-2 seconds. If there is more resistance, check that the vein has not become twisted. Gently pass a 2mm dilator feeling for resistance proximal to your dissection. If, despite your best efforts, you cannot achieve smooth unrestricted flow, a fistula using this vein is unlikely to succeed. Search for another adjacent vein, consider dissecting and anastomosing the basilic vein, or abandon the procedure. If you use the basilic vein, it must be made superficial, either concurrently using a vein tunneler, or later on as a separate operation after the vein becomes arterialized.



*The syringe of heparinized saline is cleared of air and the olive tip catheter is inserted into the vein. The end of the vein is pinched, and the heparinized saline is injected, to assess for resistance to flow. This maneuver can also be done with an 18G or 20G IV cannula, but it is possible to injure the intima of the vein if this is done carelessly.*

15. Administer 5000U of heparin IV and wait 2 minutes. Neglecting this step can endanger the arm!

16. The two vessel loops encircling the dissected brachial artery will be used to control arterial flow during the anastomosis. Put each under tension by clamping them to the drapes proximally and distally.



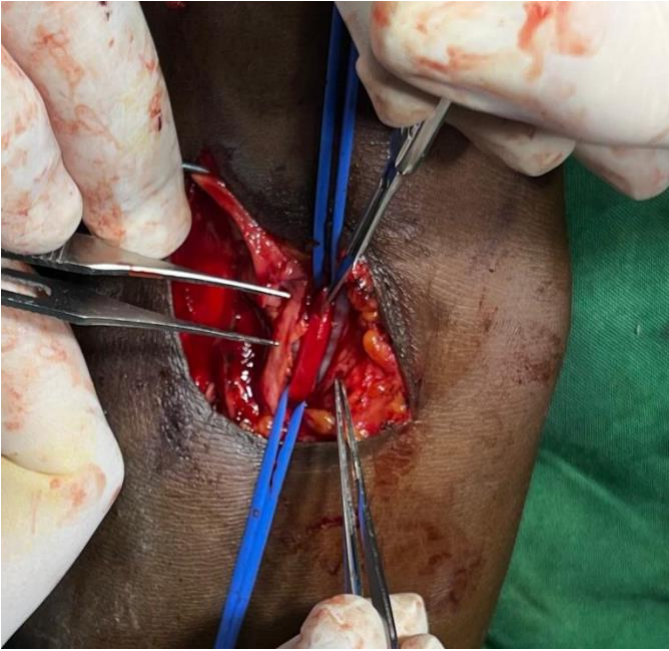
*The vessel loops encircling the brachial artery are put under proximal and distal tension, blocking flow and raising the artery up in the operative site for the anastomosis.*

17. The anterior wall of the artery is cut with a #11 scalpel blade, with the blade edge facing anteriorly. This incision is made in an area that the end of the cephalic vein will easily reach without tension. Be very careful to use only the tip of the scalpel to avoid injuring the back wall of the artery.



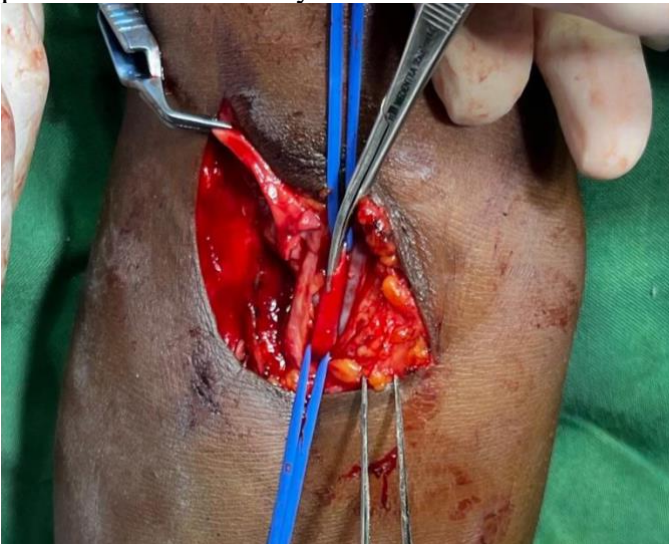# Brachial-Cephalic Arteriovenous Fistula Creation

Jerry Svoboda, Richard Davis

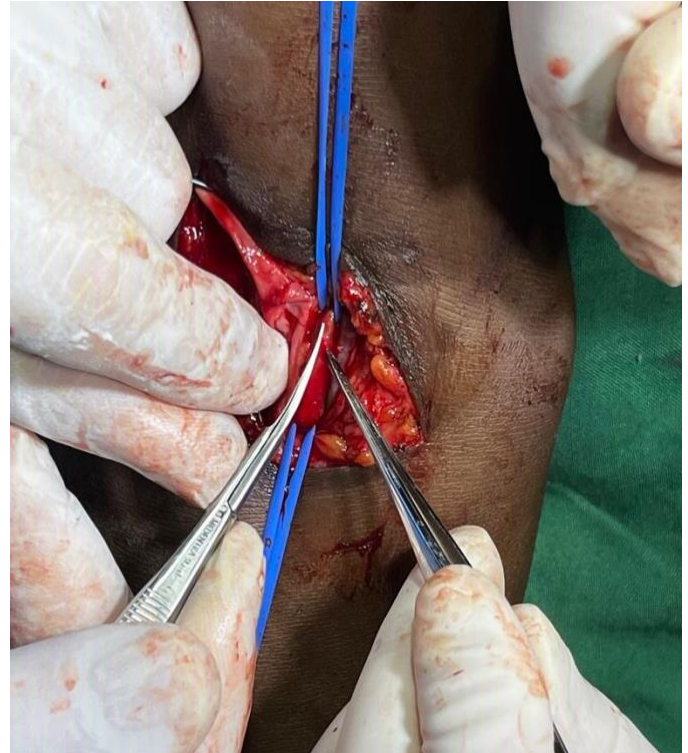

*The anterior wall (only!) of the artery is incised with a #11 scalpel blade with the sharp edge facing up. Insert only the tip of the scalpel and push the blade upwards to make an incision large enough to accommodate the tip of a fine scissors; no further incision is needed. Note also that the cut edge of the cephalic vein lies near the area the artery is incised and will easily reach here without tension.*

18. The incision is extended proximally and distally with fine Wescott or Pott's scissors, to a total length of no more than 6-7mm. A longer incision may divert enough flow from the forearm and hand to put the patient at risk of steal syndrome.

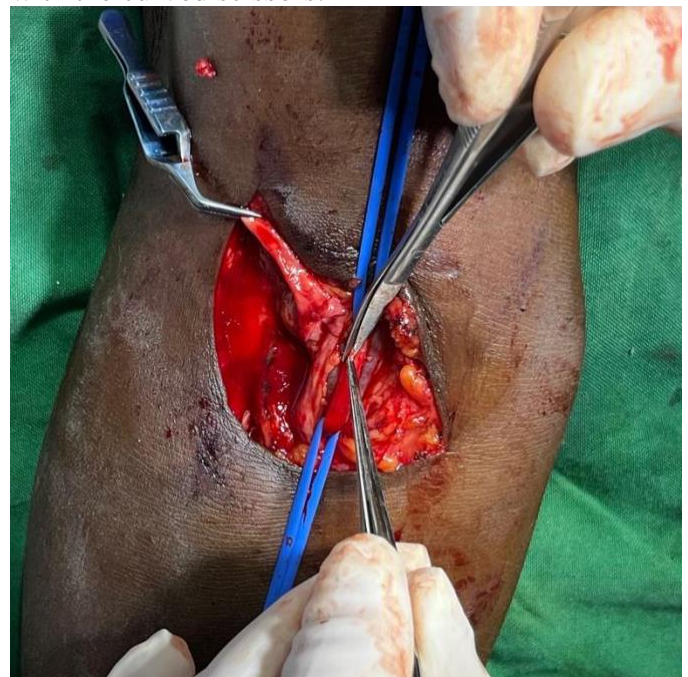


*The incision is extended distally with fine scissors.*



*The incision is extended proximally.*

19. The arteriotomy is converted from a linear one to an ellipse by trimming the edges. This avoids the need for stay sutures. Grasp a minute amount of each edge with the fine forceps, separately excising a tiny curved part of edge of the arteriotomy on each side with the curved scissors.



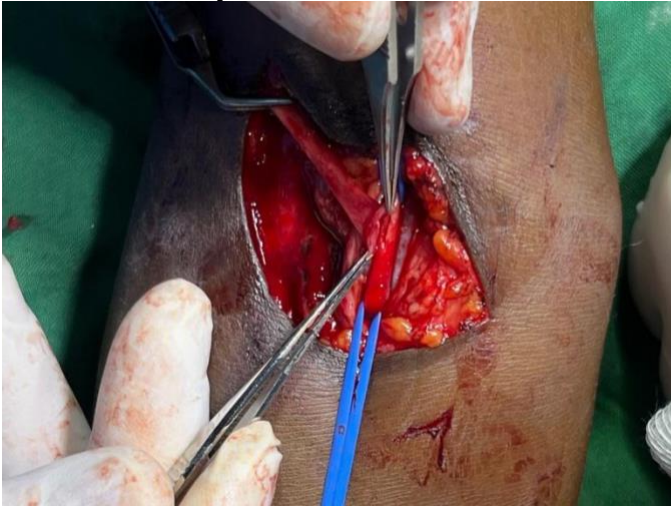

## Brachial-Cephalic Arteriovenous Fistula Creation

Jerry Svoboda, Richard Davis

*The edges of the arteriotomy are cut. Grasp and elevate a tiny amount of each side with the fine forceps and cut just underneath the forceps with fine scissors. Performed on both sides, this maneuver converts a linear incision to an elliptical one.*

20. Freshen the end of the cephalic vein so that the cut angle matches the angle at which it meets the artery. The width of the vein should match the length of the arteriotomy.

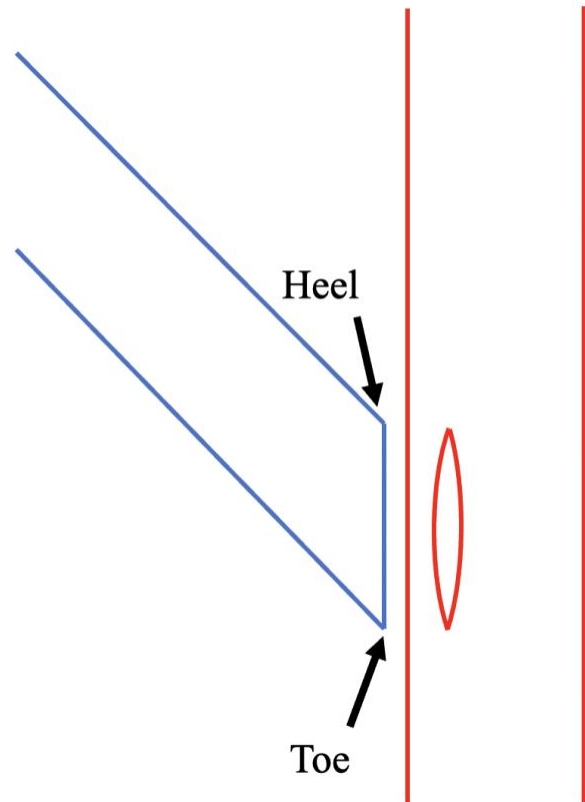


*The vein reaches the arteriotomy without tension. It is cut at an angle so that the length of the cut end matches the length of the arteriotomy. Care is taken to make sure that it is not twisted before it is cut.*

21. The anastomosis will now be made with 7-0 monofilament polypropylene (Prolene©) using double-armed suture with tapered needles. If you are using a magnifying device such as optical loupes or a magnifying headset, put it on now. The first step will be to pass the suture through the heel of the vein and the adjacent apex of the arteriotomy. Both will be done from the inside of the vessel outward.



*The headband magnifier with 2x strength is an affordable alternative to operating loupes. Once the vein and artery have been completely prepared, the headband is placed on the surgeon's and assistant's heads. Each can then put on sterile gloves, adjust their headset, and discard the gloves.*



*Schematic representing the artery (Red) and the vein (Blue.) The elliptical arteriotomy has been made in the side that is facing the vein. The vein has been cut transversely to match the angle at which it meets the artery. The length of available vein*

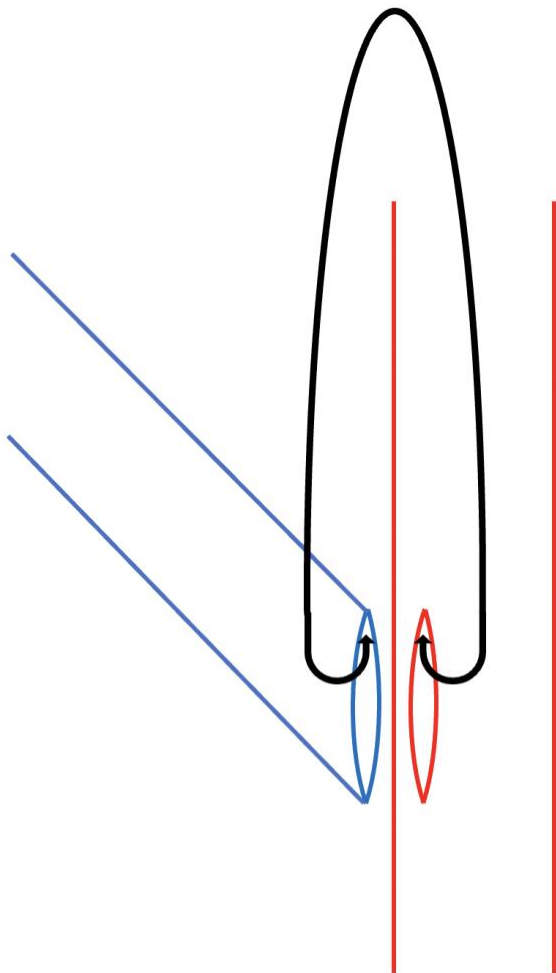


# Brachial-Cephalic Arteriovenous Fistula Creation

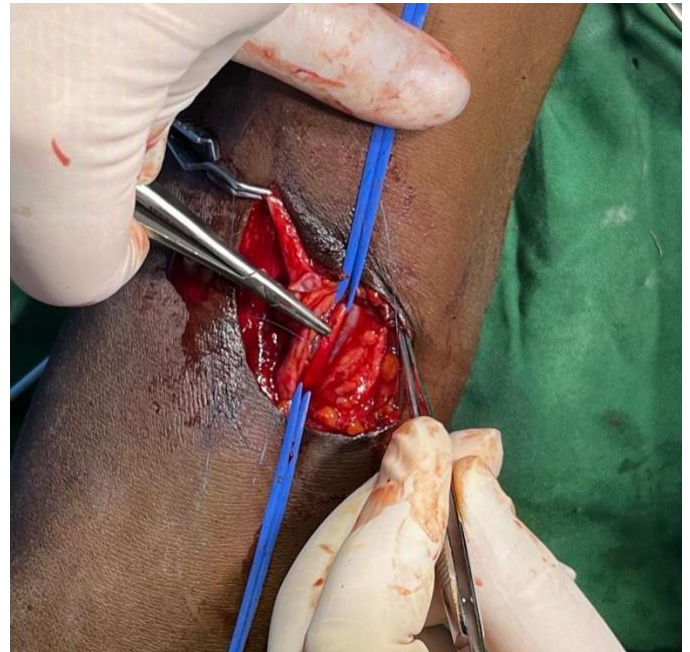Jerry Svoboda, Richard Davis

edge is tailored for the arteriotomy site and trimmed to avoid a kink in the vein when complete. The parts of the vein referred to as the Heel and the Toe are shown in the diagram.

One of the needles is passed through the vein, from inside out, at the heel.

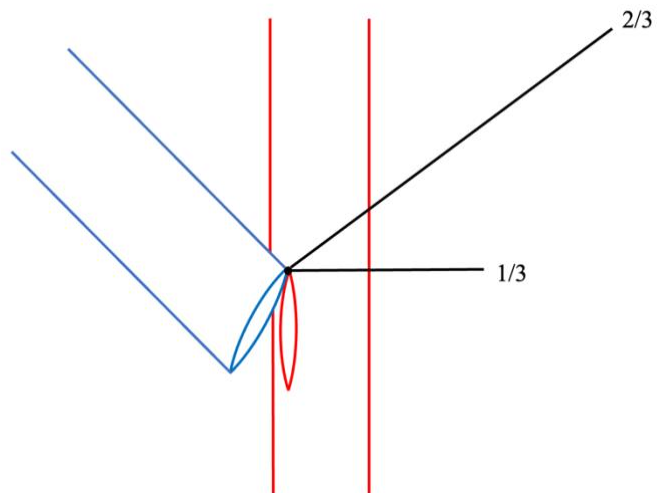


Both needles of the double-armed suture are initially passed from inside to outside of each vessel, at the heel of the vein.



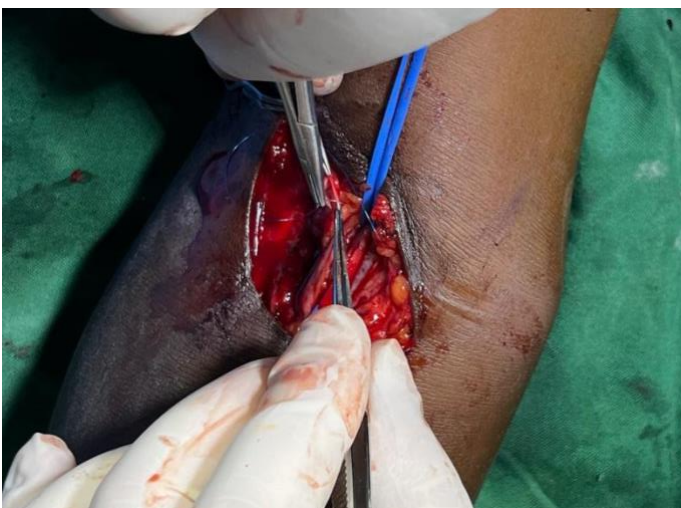The other needle is passed through the apex of the arteriotomy, from inside out, on the side adjacent to the heel of the vein.

22. The suture, still with a needle on each end, is pulled through the vessels so that one side of it is  $\frac{2}{3}$  of the total length and the other is  $\frac{1}{3}$ . The suture is then tied 3-4 times in this position, bringing the heel of the vein down to the apex of the arteriotomy.



The suture is pulled through the vessels until  $\frac{2}{3}$  of its length is on one side and  $\frac{1}{3}$  on the other. It is then tied with 3 or 4 knots.

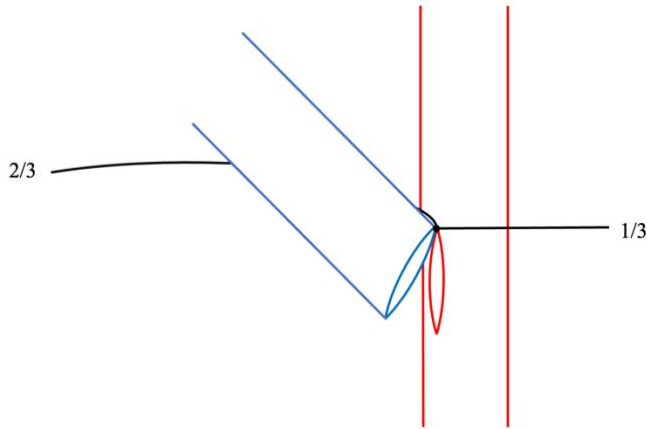
23. The longer suture is then passed under the vein. It will be used to sew the vein to the artery on this side.



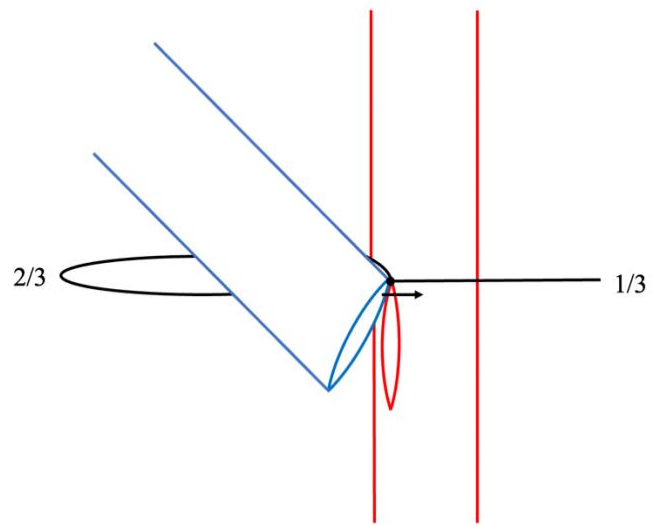


# Brachial-Cephalic Arteriovenous Fistula Creation

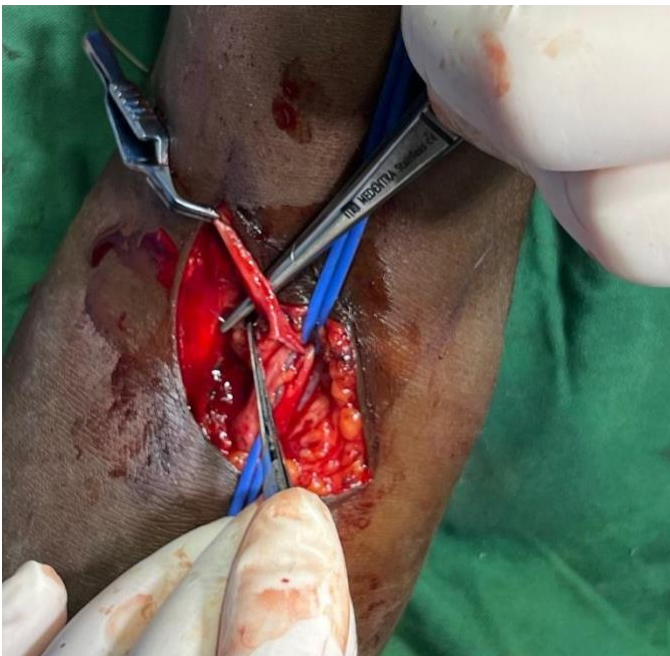
Jerry Svoboda, Richard Davis



The suture is passed under the vein to the other side. Now, there is a needle on either side of the anastomosis. We will call the side with the 2/3 length suture the “back wall,” as it is usually opposite the surgeon.

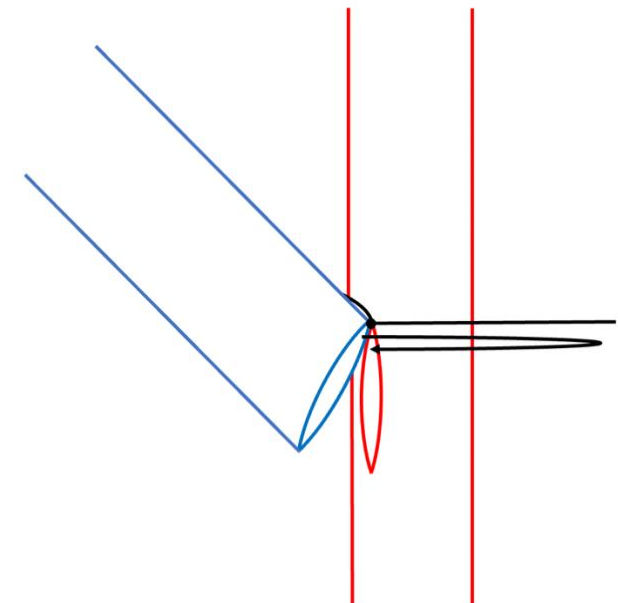


The suture is passed through the back wall vein, from outside in. Now the surgeon is ready to begin suturing the back wall of the anastomosis.



The needle, loaded in the needle holder with the tip protected, is passed under the vein to the back wall of the anastomosis.

24. The same needle is passed through the vein wall, from outside in, adjacent to the heel stitch.

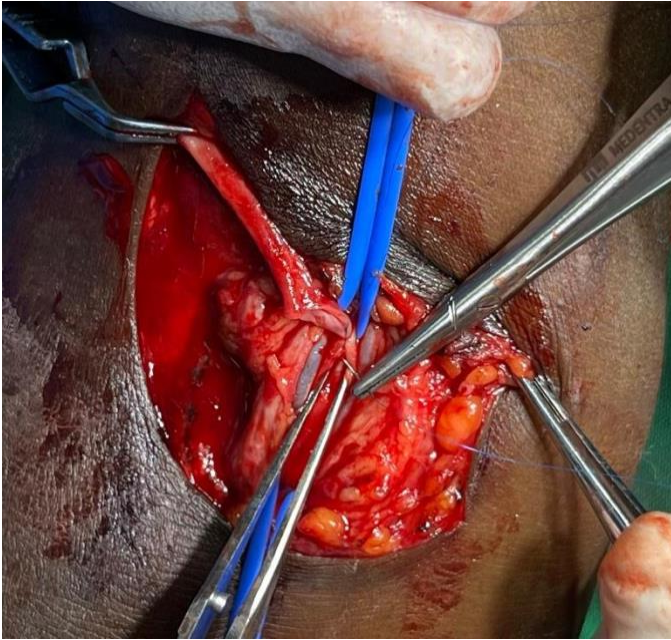


The back wall of the anastomosis is sewn, with the needle passing inside-out on the artery and outside-in on the vein.

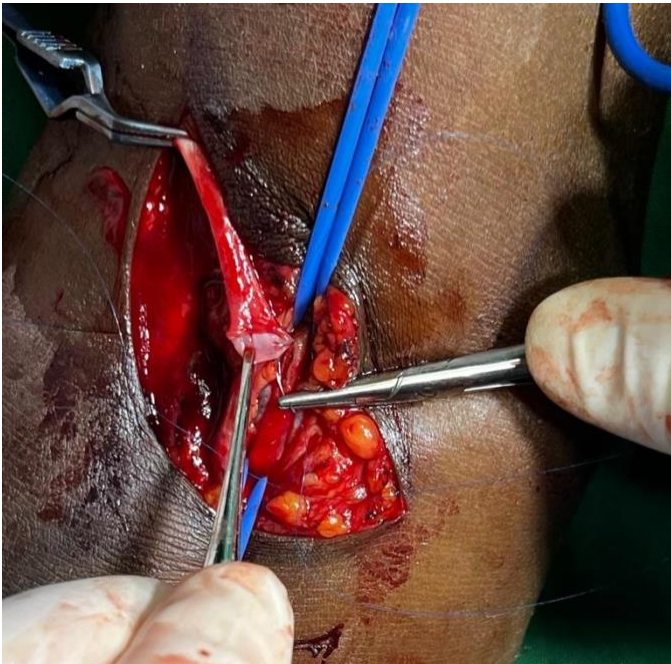

## Brachial-Cephalic Arteriovenous Fistula Creation

Jerry Svoboda, Richard Davis



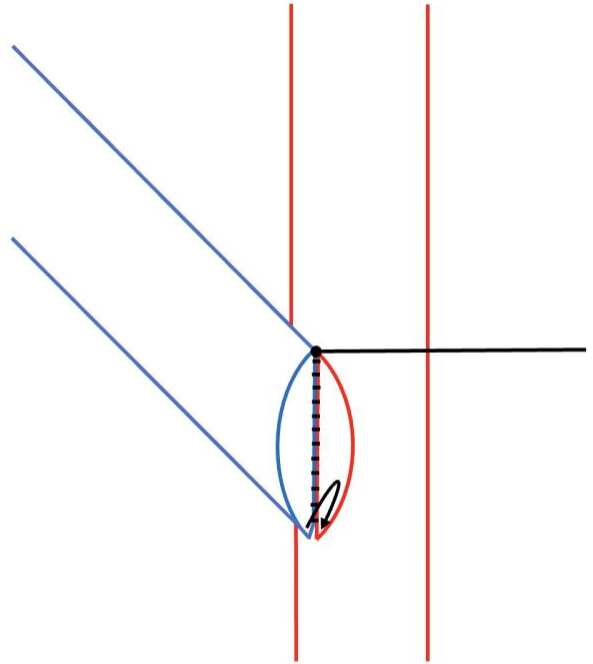
*The first stitch on the back wall anastomosis is taken, inside-out on the artery. The vein is not yet aligned, so the needle will be reloaded and then passed through the vein separately rather than trying to take it all in "one bite."*



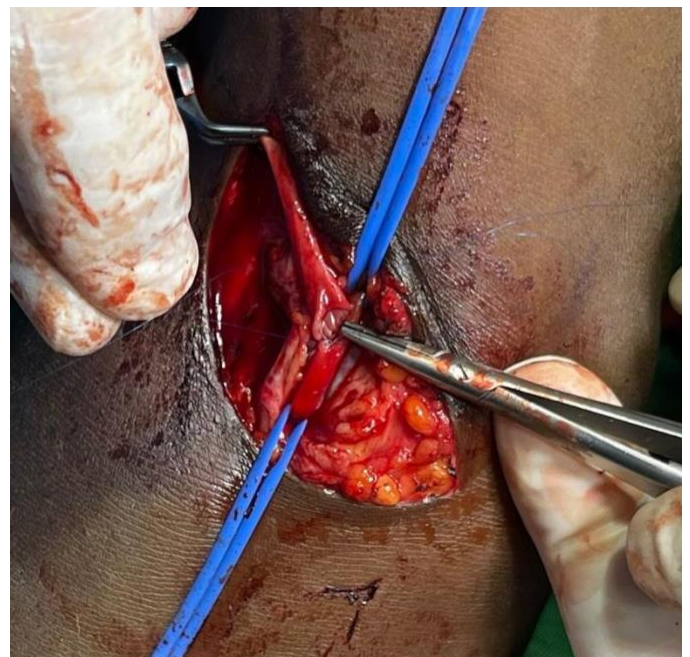
*Placing the stitch on the vein of the back wall of the anastomosis, outside-in.*

26. Continue sewing the back wall of the anastomosis until you reach the apex of the arteriotomy and the toe of the vein. Continue sewing around the toe. As you come around this corner, prompt the assistant to relax the tension without

completely letting go of the suture. This results in a better view and avoids taking oversized bites or catching the opposite intima of the artery. At this point the surgeon transitions from suturing the back wall to suturing the front wall. This is a crucial step that deserves special attention.



*The back wall suturing is complete and the toe of the vein aligns with the apex of the arteriotomy. The suture passes outside in on the toe of the vein, then inside out again at the apex of the artery.*



**OPEN MANUAL OF SURGERY IN RESOURCE-LIMITED SETTINGS**

[www.vumc.org/global-surgical-atlas](http://www.vumc.org/global-surgical-atlas)

This work is licensed under a [Creative Commons Attribution-ShareAlike 3.0 Unported License](https://creativecommons.org/licenses/by-sa/3.0/)

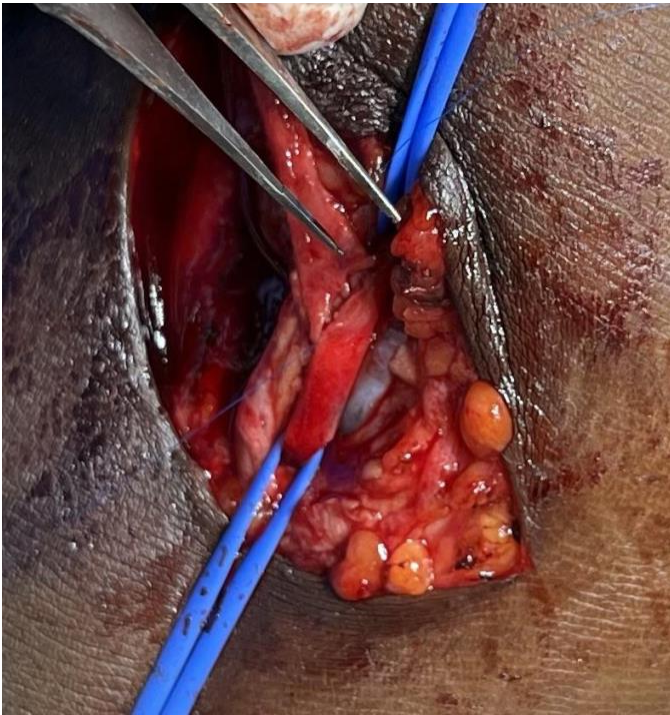




## Brachial-Cephalic Arteriovenous Fistula Creation

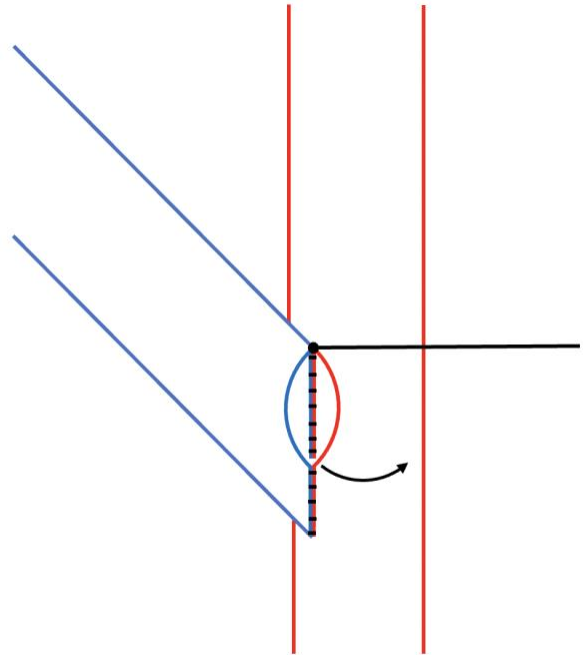
Jerry Svoboda, Richard Davis

*The suture is passed inside out at the apex of the arteriotomy, bringing the toe of the vein down to the apex.*



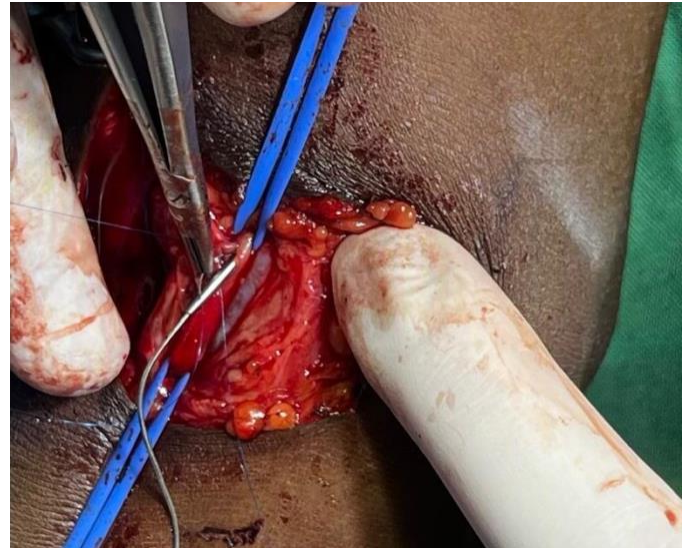
*The “back wall” anastomosis completed. The vein and arteriotomy line up perfectly and the surgeon is now ready to suture the front wall. Both needles will be sewing towards each other to meet in the middle of the “front wall.”*

27. The surgeon continues with the same needle, suturing now away from the toe heading towards the heel, continuing inside-out on the artery and outside-in on the vein. In this way about 1/3 of the front side is closed.



*Using the same needle, the surgeon now sews away from the toe, towards the heel, until 1/3 of the front wall is complete.*

28. The other suture is now loaded into the needle holder and the front wall closure is continued, starting from the heel. Continue outside-in on the vein, and inside out on the artery. The surgeon must take care not to catch the “back wall” with these sutures, as this would occlude the lumen of the anastomosis.



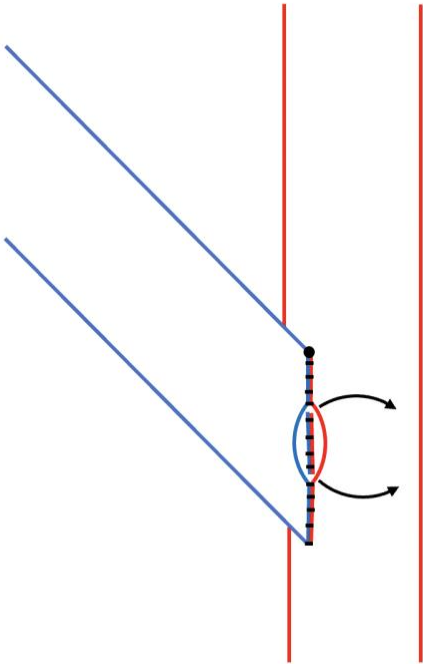
*Suturing the front wall anastomosis from the heel side of the vein. The vein stitch (outside-in) has been placed and now the arterial stitch (inside-out) is being placed. A small vascular dilator is placed in the lumen of the artery to make sure the*



## Brachial-Cephalic Arteriovenous Fistula Creation

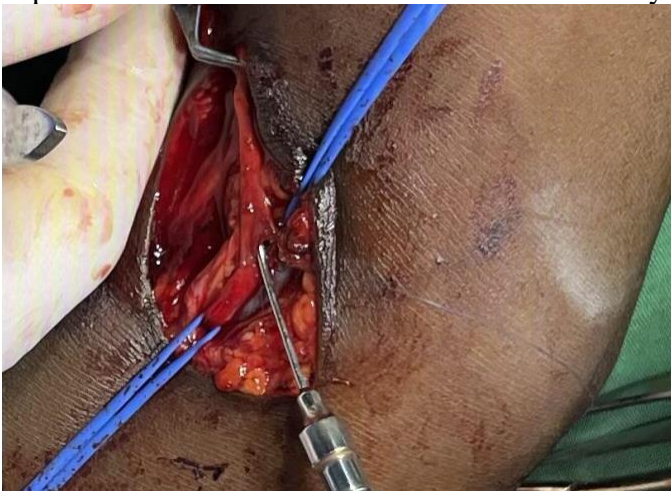Jerry Svoboda, Richard Davis

*posterior wall of the artery is not inadvertently included in the suture.*



*The 1/3 of the front wall anastomosis adjacent to the heel is now completed, leaving only a few sutures remaining to complete the anastomosis in the middle of the front wall.*

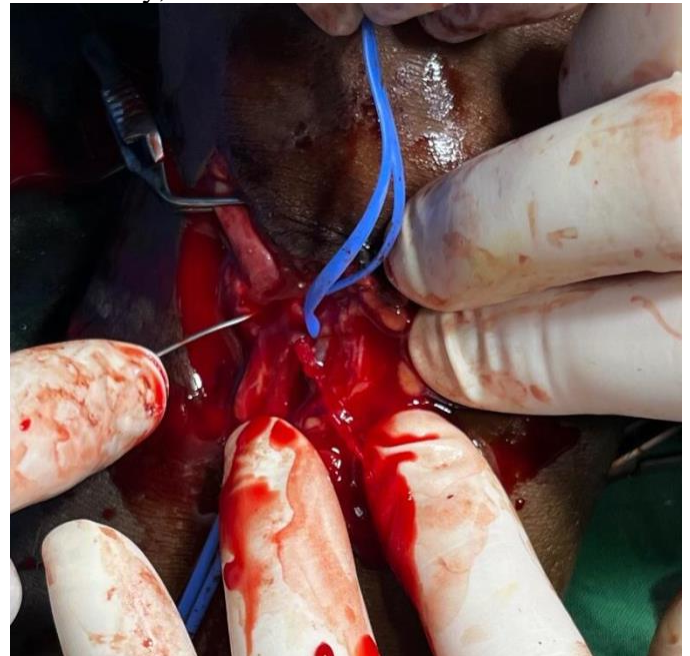29. Remove the small clamp and flush the vein with heparinized saline to confirm that it still flows freely.



*The anastomosis is almost complete. The olive tip catheter is inserted into the vein, the Diethrich clamp is opened, and the vein is flushed to assure flow is still good.*

30. The vessel loops on the artery are loosened, first distally and then proximally, to “flush” the anastomosis through the remaining open 1/3, to

remove any air, clot, or debris. Heparinized saline is again injected into the vein with the olive-tip catheter to make sure that it is still patent. If pulsatile bleeding or backflow does not immediately appear, careful insertion of the dilator a short distance into the artery will usually solve the problem. If this is needed, take care not to perforate the side of the artery with the dilator. The artery, when lifted by the vessel loops, assumes a curved configuration and can be perforated away from where you can see it. Once flow is confirmed from the artery both proximally and distally, the final stitches are taken.



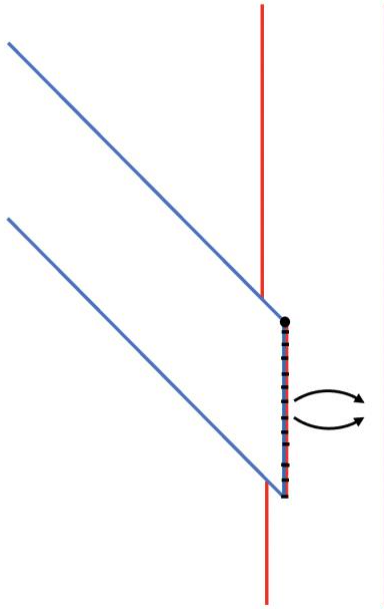
*First the distal and then the proximal (shown) vessel loop is loosened, both to assure continued arterial bloodflow and to remove any clot or debris that might have accumulated while the artery was clamped.*

31. Apply gentle traction to both vessel loops again to control bleeding. Finish the anastomosis with either needle, using whichever is more comfortable to sew with.

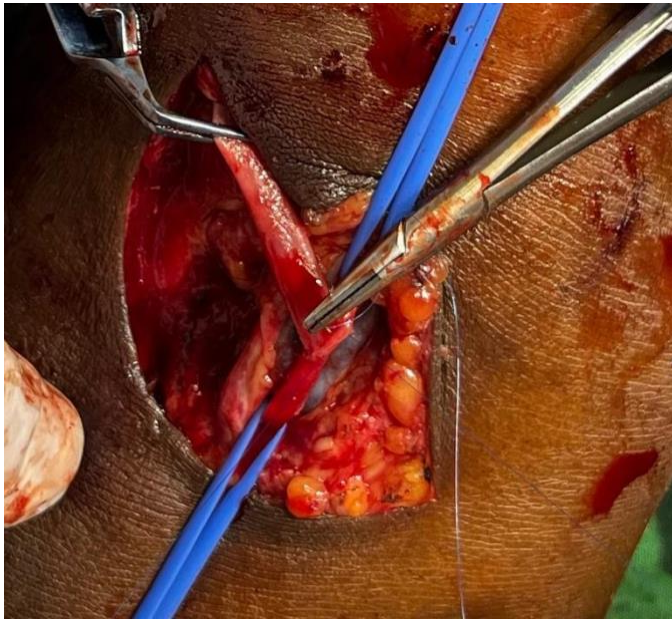


## Brachial-Cephalic Arteriovenous Fistula Creation

Jerry Svoboda, Richard Davis



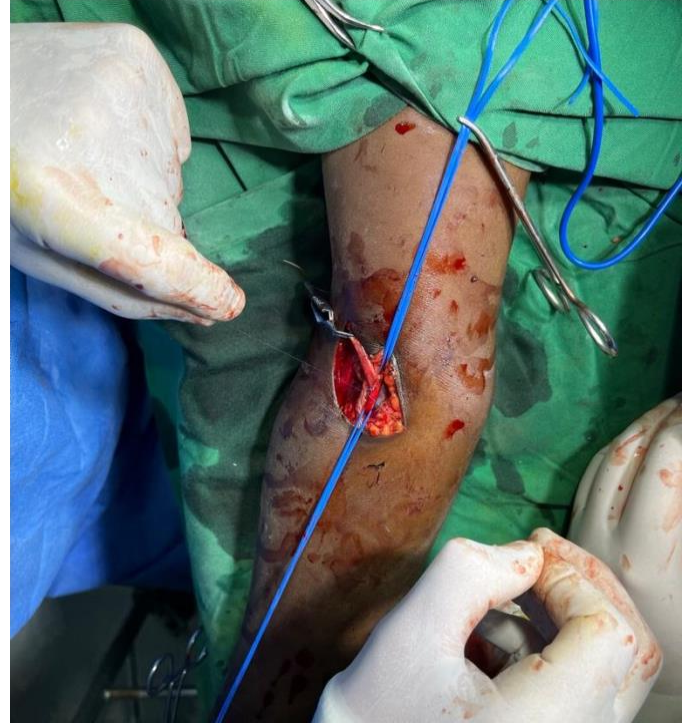
*Continued awareness of the “inside-out on the artery” rule will result in two sutures on the same side of the anastomosis.*



*The final stitch is taken, through only the edges of the vessels, to complete the anastomosis.*

32. Tie the suture with great care, it must be tight but it must not break (the beginning vascular surgeon would be wise to practice with the same suture before attempting this operation.) Save the leftover sutures for repairing any bleeding points if needed. If the suture breaks, undo stitches from both ends of the front wall anastomosis until there is enough “stub” of suture to perform an instrument tie at each end. Take a single armed 7-0 suture, pass it through the vessels

adjacent to this stub, tie the suture you have passed, then instrument tie it to the stub. Repeat with the other stub then resume suturing with both needles to meet in the middle of the anastomosis. Tie the sutures together again.



*The fine 7-0 polypropylene suture is tied with great care. The clamp on the vein is still in place, but it can be removed at this point.*

33. Release the clamps. If there is a diffuse ooze, hold gentle (non-occlusive) pressure. If there is a discrete bleeding point, repair it using the leftover 7-0 suture, using a simple, figure 8, or horizontal mattress configuration to close the bleeding point. Take care not to pass the needle deep, to avoid catching the posterior wall of the artery or vein.

34. Palpate the vein. You may feel a buzzing sensation (known as a “thrill”) or only a pulse. If you feel a pulse only, palpate the skin over the vein proximally and you may feel the thrill there. If you feel nothing, assess the anastomosis. Are all the clamps and vessel loops off tension or removed? Does the vein look full but has a pulse only and no thrill? Likely there is a distal occlusion or the vein is twisted more proximally under the skin flap where it cannot be seen. Does the vein look flat? Likely there is a technical error at the anastomosis, some of your

**OPEN MANUAL OF SURGERY IN RESOURCE-LIMITED SETTINGS**

[www.vumc.org/global-surgical-atlas](http://www.vumc.org/global-surgical-atlas)

This work is licensed under a [Creative Commons Attribution-ShareAlike 3.0 Unported License](https://creativecommons.org/licenses/by-sa/3.0/)

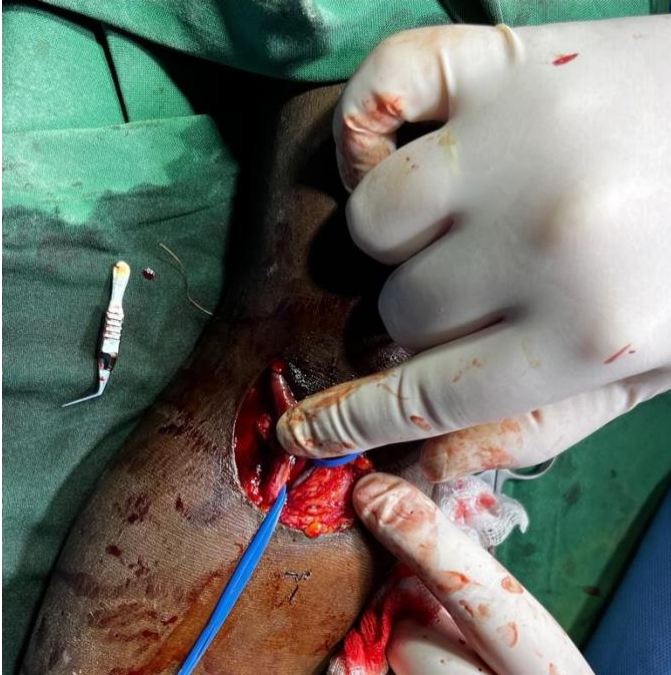



## Brachial-Cephalic Arteriovenous Fistula Creation

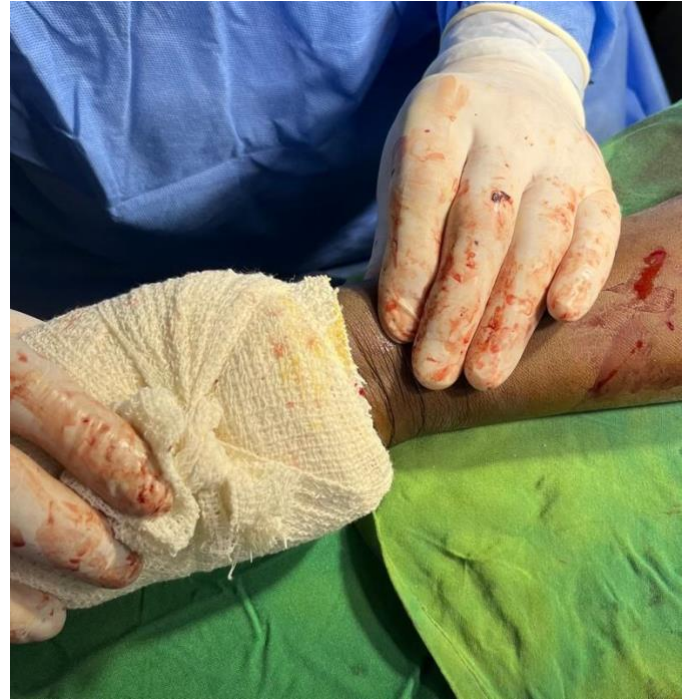Jerry Svoboda, Richard Davis

“front wall” stitches caught the “back wall” and closed off the anastomosis.



*The vein is palpated with all clamps removed. There should be a palpable thrill or a pulse in the vein.*

35. Palpate the radial pulse. It may be diminished compared to the preoperative state but you should be able to palpate either the radial or ulnar artery pulse. If not, reassess your anastomosis, as possibly one of your apex stitches caught the posterior wall of the artery and occluded it. At this point, returning flow to the arm is a higher priority than maintaining the fistula, though obviously if both can be preserved this is ideal.



*Palpate the radial artery. If it is diminished, assess the patient for steal symptoms such as hand or arm pain or tingling. If any of these are present, the fistula must be occluded and another attempt must be made at another time. Tingling in the fingers may be tolerated and will usually resolve. Anesthesia, pain in a digit, or spasm of forearm musculature will generally not resolve. The fistula must be carefully examined, explored if necessary, and possibly ligated if these danger signs do not resolve.*

36. Assure hemostasis. Close the wound in 2 layers with interrupted absorbable subcutaneous followed by nonabsorbable sutures in the skin. Check the thrill and the distal pulses again after wound closure. Place a very loose dressing: a non-elastic bandage can be wrapped around the arm but the tape that secures it should not go around the arm. Listen with a stethoscope and mark the area where the bruit can be heard. Surprisingly, this will often be quite loud even when the thrill is difficult to palpate.



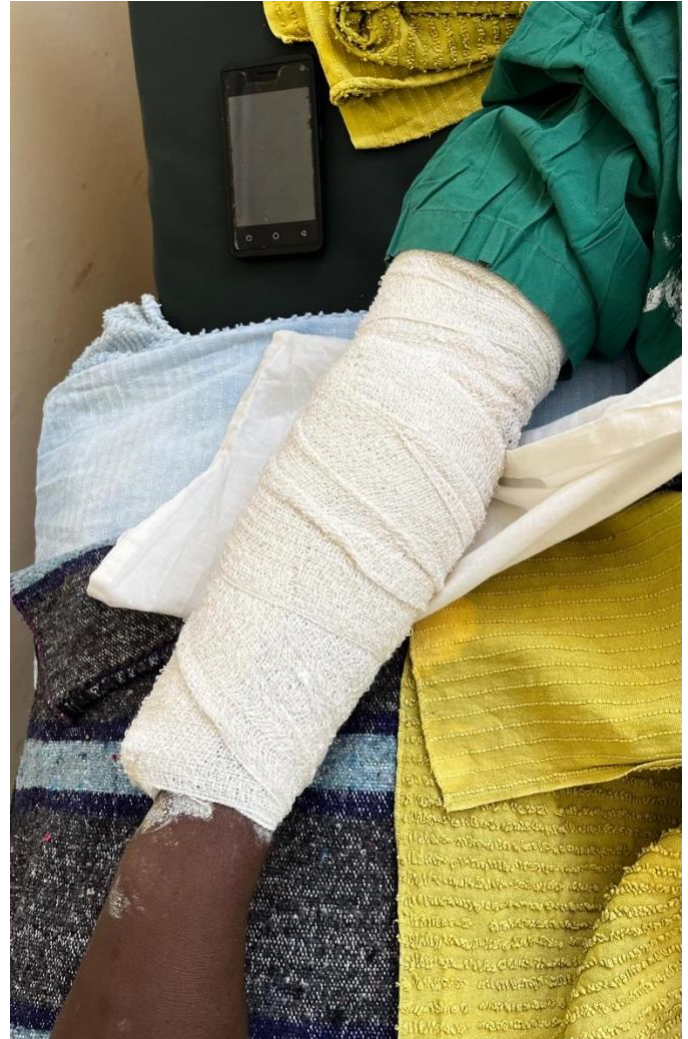## Brachial-Cephalic Arteriovenous Fistula Creation

Jerry Svoboda, Richard Davis



*Non-elastic bandage can be placed circumferentially, loosely. Do not wrap the bandage tightly and do not place tape circumferentially. The wound will swell a bit and the tape, which will not expand, may cause occlusion. The location where the bruit is best heard is marked.*

37. Place a posterior plaster splint (“backslab”) to keep the arm in extension overnight. Wrap the splint loosely with non-elastic bandage, as above.



*A posterior splint of plaster, wrapped very loosely with non-elastic bandage, to keep the arm in extension for 12-24 hours after surgery.*

### Pitfalls

- Fistula failure, either early or late, is a constant risk that the patient should be advised of. As long as this fistula is working, they should avoid phlebotomy, IV placement, and blood pressure measurement on this arm. For the first two weeks they should keep it elevated as much as possible and use the arm only to eat and drink. Circumferential bandages of any type should also be avoided, at all times but especially in the first two weeks.
- Injury to the brachial artery and arm ischemia is a risk, as the brachial artery is the unique blood supply to the forearm. The techniques above must be meticulously followed, especially taking



## Brachial-Cephalic Arteriovenous Fistula Creation

Jerry Svoboda, Richard Davis

care to avoid catching the posterior wall of the artery during the anastomosis. This is most possible when suturing at either apex of the arteriotomy. A small vessel dilator can be inserted into the artery as this stitch is placed to push the posterior wall away from the needle.

- Injury to the median nerve, which runs just medial to the brachial artery in the antecubital fossa. Careful dissection and especially avoidance of diathermy when dissecting the brachial artery will help to avoid this complication.
- Elbow stiffness or contracture can occur if the patient avoids fully extending or flexing the arm during the postoperative period. Initially, they may be unable to flex completely. After the first overnight with the splint, they should be instructed to cautiously flex and extend the arm every day until full range of motion is achieved.
- Operating with the elbow flexed could lead to excessive tension and even tearing of the anastomosis when the arm is straightened. Be sure the arm is fully extended on the armboard.
- Failure to administer systemic heparin before occluding the brachial artery is a novice's error and could be catastrophic. This could result in thrombosis of the arteries distal to the brachial artery, which may cause irreversible damage even if embolectomy is performed later.
- Steal syndrome is avoided by making a brachial artery incision no bigger than 6-7mm, smaller if the artery is very small. The patient may complain of constant numbness, tingling or pain. Alternatively, they may only feel these symptoms when using the hand excessively, or during dialysis. Feel the radial pulse after placement of the fistula; if it is strong and unchanged from preoperatively, steal syndrome is unlikely. Treatment consists of completely ligating the vein of the fistula: this should be done even immediately after the surgery if classic steal symptoms appear. The use of the DRIL (Distal Revascularization and Interval Ligation) procedure for steal syndrome is beyond the scope of this text.

Jerry Svoboda, MD FACS  
Rochester, New York  
USA

Richard Davis, MD FACS FCS(ECSA)  
AIC Kijabe Hospital  
Kenya

