

Approach to Penetrating Neck Trauma

Lillian Hsu, Pako Motlaleselo, Mike M. Mallah

Background:

Civilian penetrating neck trauma results in a mortality rate that ranges from 3-6% and constitutes approximately 5-10% of all trauma worldwide. Vessels are the most injured structures in the neck and vascular involvement increases the mortality rate to as high as 50%. Higher energy mechanisms (such as gunshot wounds) are more likely to be associated with significant vascular injury. Aerodigestive tract involvement must also be quickly assessed and treated promptly if present.

Neck trauma is often high acuity, complex, and challenging to treat. Management of these injuries is dependent on the location of the injury meaning which zone—described below—of the neck is wounded. In general, patients exhibiting any “hard signs” of injury will require operative management. The “hard signs” are:

- Pulsatile bleeding from a wound
- Expanding hematoma
- Decreased pulses or evidence of distal ischemia (including mental status changes or altered neurologic examination)
- Audible bruit or palpable thrill
- Respiratory distress or inspiratory stridor
- Hoarseness
- Bubbling in wound
- Subcutaneous emphysema
- Difficult or painful swallowing
- Shock

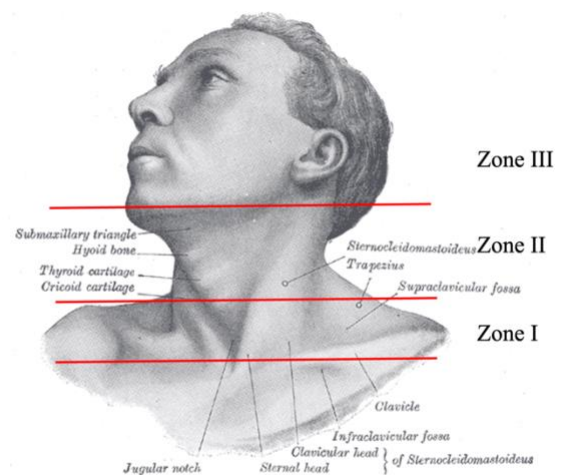
The treatment of penetrating neck injury for symptomatic or mildly symptomatic patients is less certain and constantly evolving, with sufficient evidence for both operative and nonoperative management strategies. In areas with limited resources, it is critical to have a thorough and accurate physical exam, as this will most likely determine the need for operative exploration. If available, in a hemodynamically stable patient, it is always helpful to have imaging adjuncts to determine precise location and extent of injury. The most helpful imaging modality to assess for vessel involvement is CT angiography of the neck. In a resource-limited environment, other options include duplex ultrasound, flexible or rigid esophagoscopy, or contrast x-rays, as described further below.

In areas where adjunctive imaging is not accessible and in patients who are not in immediate distress, surgeons should use serial physical exams to determine the need for operative intervention, as initially asymptomatic patients can quickly worsen.

Anatomy:

The neck is divided into 3 main zones:

- Zone I: From clavicle and suprasternal notch to the cricoid cartilage
- Zone II: From the cricoid cartilage to the angle of the mandible
- Zone III: From the angle of the mandible to the base of the skull



Zone I is the least commonly injured zone due to some protection by the thoracic skeleton. For this same reason, it is also the most difficult zone of the neck to obtain adequate exposure. It contains:

- Common carotid arteries
- Vertebral arteries
- Subclavian arteries
- Trachea
- Esophagus
- Thoracic duct
- Thymus gland
- Apex of pleura and lung

Zone II is the largest, and thus most frequently injured zone in the neck. It is also the easiest to access surgically. It contains:

- Internal and external carotid arteries
- Jugular veins
- Pharynx
- Larynx

Approach to Penetrating Neck Trauma

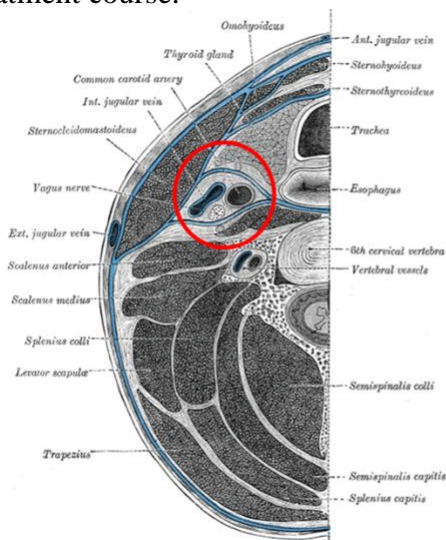
Lillian Hsu, Pako Motlaleselelo, Mike M. Mallah

- Esophagus
- Thyroid gland
- Parathyroid gland
- Recurrent laryngeal nerves
- Vagus nerves

Zone III is closest to the skull base, making it difficult to perform an adequate physical exam and obtain adequate surgical exposure. This area is also partly behind the ascending ramus of the mandible making exposure extremely difficult. It contains:

- Distal extracranial internal carotid artery
- Vertebral arteries
- Most proximal segments of the jugular veins
- Parotid gland and facial nerve branches

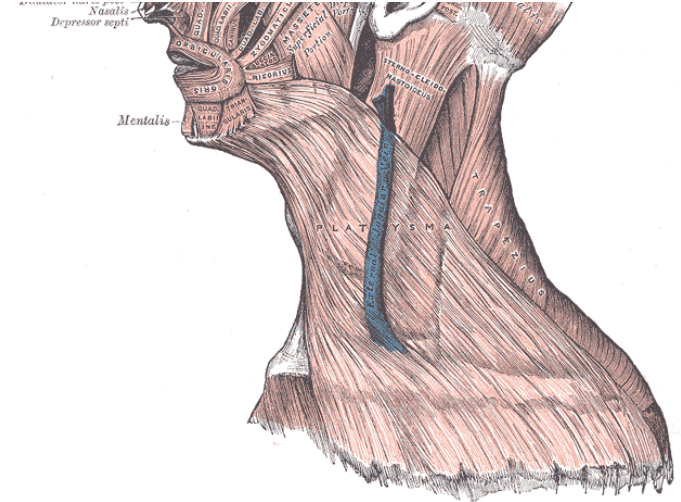
Structures in the neck are contained in tight fascial compartments that may limit external signs of hemorrhage, contributing to the ambiguity of physical examination. For this reason, serial physical examination by the same team is useful to determine treatment course.



The fascial planes of the neck, in Blue, seen in cross section at the level of the 6th vertebra. A penetrating injury to the carotid artery inside the carotid sheath (Red circle) may exert significant pressure on the adjacent trachea or larynx without much externally visible swelling.

Surgeons operating within the neck should be intimately familiar with its fascial planes and their effect on the spread of blood under pressure. The most superficial fascial plane is the one that contains the platysma. This is known as the superficial layer of the deep cervical fascia, or the investing fascia. Penetrating injuries that have failed to pass this layer

do not require further exploration, although this situation does not rule out blunt injury to the trachea or arterial structures.



The platysma is contained by the Investing fascia. Like the deep layers of cervical fascia, this layer can contain an expanding hematoma, transmitting pressure to the blood vessels or the airway

Principles:

As with any trauma evaluation, ABCs (airway, breathing, circulation) should first be evaluated in the usual order for penetrating neck trauma. Up to 10% of patients with penetrating neck trauma can present with respiratory distress and require immediate airway control, which can be a significant challenge. See [Airway Management in Trauma](#).

Selection of Operative Versus Nonoperative Management

There are very few strict guidelines regarding operative management of penetrating neck trauma. Foremost, if the patient exhibits any hard sign of injury as mentioned above, he or she should be taken for immediate operative exploration.

Conversely, if the patient is hemodynamically stable and imaging is available, the patient should undergo CT imaging (with or without angiography.)

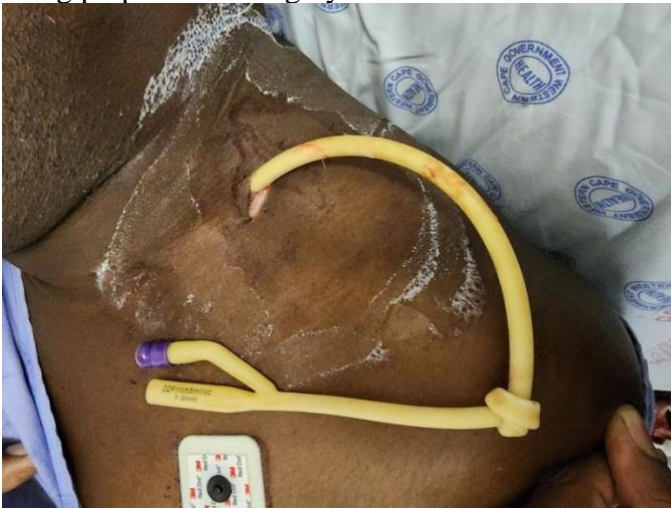If the wound does not penetrate the platysma, it is highly unlikely that the patient suffered a significant injury, and operative exploration is not necessary. Especially if advanced imaging is not available, it is reasonable to explore a small stab wound in a hemodynamically stable patient to confirm that the platysma was not violated.

Approach to Penetrating Neck Trauma

Lillian Hsu, Pako Motlaleselelo, Mike M. Mallah

Zone II is readily accessible to the surgeon, and symptomatic patients should undergo operative exploration immediately with any hard sign of injury.

It is important to highlight the utility of Foley catheter balloon tamponade in patients with life threatening or bleeding penetrating neck wounds, particularly in low resource settings. It has a 97% success rate at hemorrhage control, as minor arterial and venous injuries are definitively managed this way. A Foley catheter balloon can be inflated in the tract of the injury in casualty while the patient is being prepared for surgery.

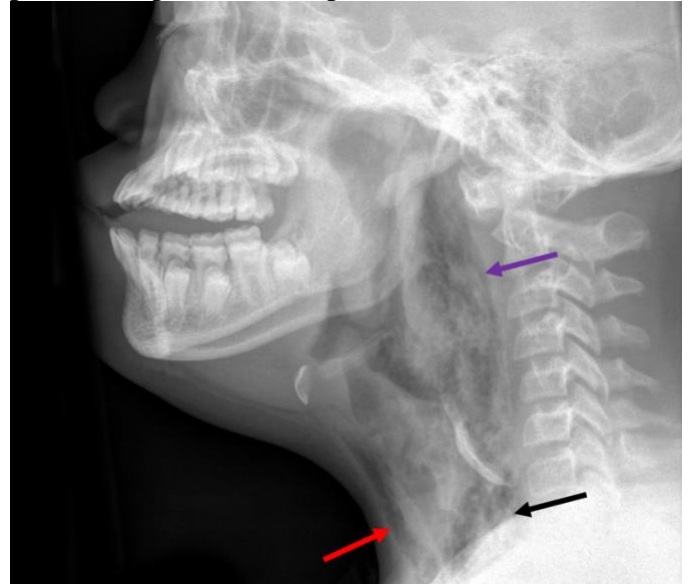


A Zone II injury to the left neck, patient's head is rotated to his right. A single foley catheter was applied to arrest bleeding in a secondary hospital, and the patient was transferred. CT angiogram showed injury to an unnamed branch of the left dorsal scapular artery. The catheter was removed in theater and no further bleeding was noticed. In a setting without a CT scanner, an appropriate strategy would be neck exploration with proximal and distal exposure of the carotid arteries and jugular vein, followed by exploration of the tract and removal of the catheter.

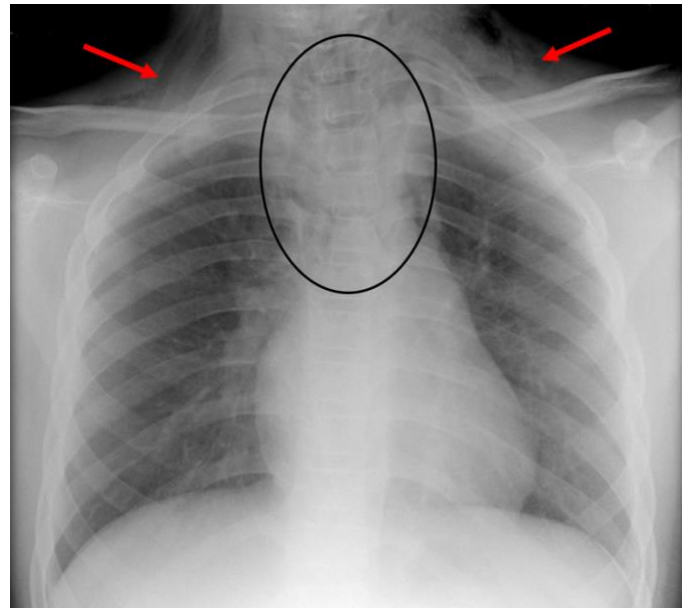
If possible, all patients managed with Foley balloon tamponade require CT angiography prior to removal of the catheter to determine whether the injury is amenable to observation or surgical intervention. If imaging is not available and a Foley balloon has been placed for tamponade, perform surgical exploration. Obtain proximal and distal control of vessels near the tract before opening the tract and exploring it.

A chest x-ray is important to obtain with suspected injuries in this area due to its proximity to the mediastinum and potential to cause breathing

issues from damage to the lungs. A lateral view should be obtained if the injury is in close proximity to the aerodigestive tract with particular attention paid to the prevertebral space.



Lateral neck x-ray in a patient with esophageal perforation, showing significant air in the subcutaneous (Red arrow) and mediastinal (Black arrow) spaces, tracking upwards underneath the prevertebral fascia (Purple arrow.)



Anteroposterior chest x-ray in the same patient, showing subcutaneous air (Red arrows) and mediastinal air (Black circle.) Both photos courtesy of Frank Gaillard, from the case <https://radiopaedia.org/cases/8282?lang=us>

Diagnosing Vascular Versus Other Major Structure Injury

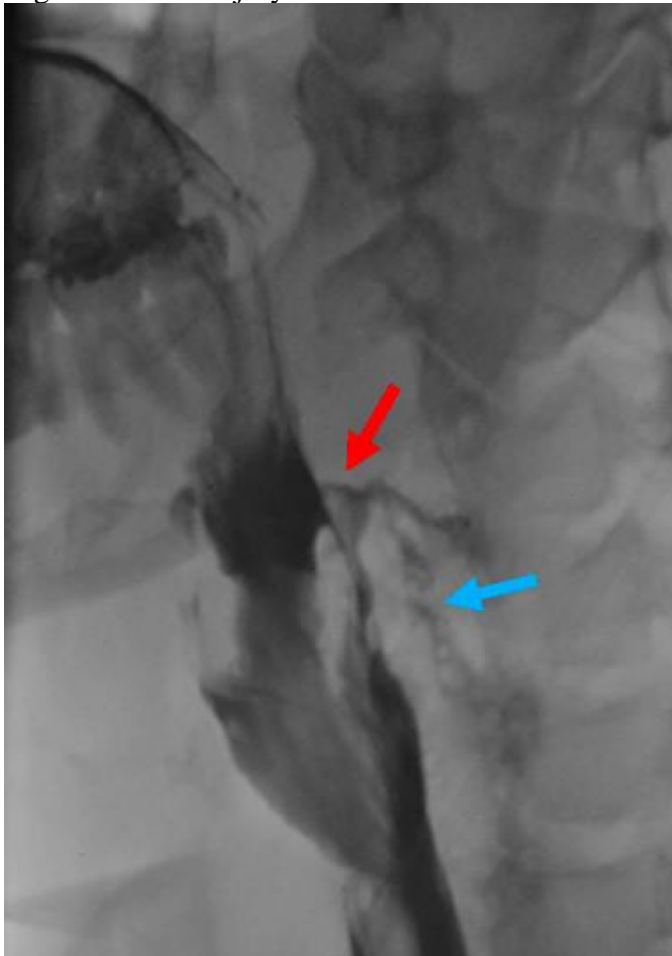
If there are no hard signs of injury, the physical exam in the immediate post-injury period is

Approach to Penetrating Neck Trauma

Lillian Hsu, Pako Motlaleselelo, Mike M. Mallah

not dependable for diagnosing vascular injury. Initially asymptomatic patients can develop delayed pseudoaneurysms and neurologic events. Serial physical exams, however, can be useful, especially in diagnosing vascular injury. Auscultating the carotid arteries for a bruit in the hours following injury can be diagnostic in the absence of additional imaging. CT angiography has been shown to have 100% sensitivity in diagnosing vascular injury. If unavailable, duplex ultrasound imaging (shown to have up to 92% sensitivity) can be performed.

Damage to other major neck structures, such as the esophagus, can be difficult to diagnose as there are often not immediate physical signs. If the patient presents with odynophagia, this should absolutely be explored further with esophagography followed by [rigid esophagoscopy](#), which has a higher sensitivity and less risk of increasing pneumomediastinum if an injury is present than flexible esophagoscopy. Using both imaging modalities greatly decreases the false negative rate of injury detection.

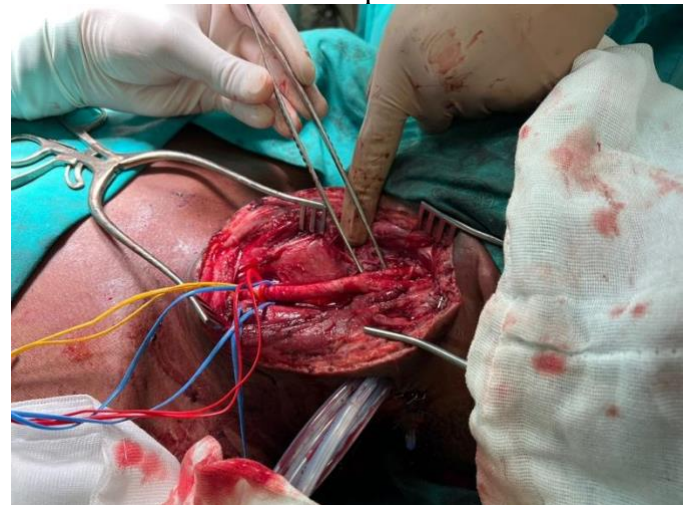

Lateral view Barium swallow study shows extravasation of contrast from the posterior hypopharynx area after a gunshot

wound to the neck. The Red Arrow shows the point of extravasation, and the Blue Arrow shows passage of the contrast inferiorly into the mediastinum. This patient will require surgical exploration, debridement, and repair of the perforation. Case courtesy of RMH Core Conditions, from the case <https://radiopaedia.org/cases/26313?lang=us>

Carotid Artery Repair

There are three options regarding carotid artery repair – reconstruction, ligation, and non-operative management. Operative decision making is based mainly on patient presentation as well as injury location (Zone I, II, or III.) **Non-occlusive injuries to the carotid that are limited to the intimal layer** can be safely observed. Zone I injuries are often the most subtle and often require imaging for accurate diagnosis. Operative repair for zone II injuries (usually accompanied by at least one hard sign of vascular injury) are performed via oblique cervical incision. Patients presenting with neurologic deficits should have repair as opposed to ligation. Injury to the carotid artery in zone III should be focused on controlling hemorrhage and preserving cerebral perfusion. If available, angiographic imaging should be obtained first in a stable patient.



Patient with right Zone 2 stab wound. Five Foley catheters were used to arrest arterial hemorrhage before surgery. Common carotid artery laceration at the bifurcation was repaired with a bovine pericardium patch. The right internal jugular vein was ligated. Note that in a resource-limited setting, the ligated vein could have been used to patch the arterial repair.

Venous Injury Management

The focus in penetrating neck trauma is often airway management and arterial injury. Venous injuries can often be overlooked, especially if other existing injuries are managed nonoperatively.

Approach to Penetrating Neck Trauma

Lillian Hsu, Pako Motlaleselelo, Mike M. Mallah

Approximately 18% of penetrating neck trauma involving vasculature will result in an arteriovenous fistula. Where possible, angiography should be used to assess vascular injury. When a venous injury is diagnosed, ligation of great veins of the neck or thorax is a safe option with fairly limited long term effects provided the internal jugular veins are not both ligated simultaneously.

Esophageal Injury

Esophageal injury can be difficult to diagnose without imaging, especially immediately following neck trauma. Unfortunately, delayed diagnosis contributes significantly to morbidity and mortality. Some signs suggestive of esophageal injury include hemoptysis, odynophagia, hematemesis, and respiratory distress. If available, esophageal injury is best assessed by barium swallow. Barium has a higher sensitivity for small esophageal injuries than a water-soluble contrast, but also has the potential to cause more mediastinal damage in the setting of a perforation.

Tracheal Injury

Priority should always be given to stabilizing the airway in trauma situations. Signs of tracheal injury include bubbling from the wound, stridor, hemoptysis, and subcutaneous air, though several of these signs can also be seen with GI tract injury. If there is concern for airway compromise, and general anatomic relationships are preserved, rapid sequence intubation is appropriate. In situations with massive trauma and distortion of landmarks, the exposed trachea can be directly intubated or a provider can use a flexible endoscopic guided oral intubation if it is available. When possible, techniques without direct visualization should be avoided to prevent further injury. If tracheal intubation is unsuccessful, invasive airway management is the next step, most commonly via cricothyroidotomy as a last resort. Needle cricothyroidotomy with bag valve mask oxygenation is also an option, Blind nasotracheal intubation is not appropriate in this scenario.

The Role of Cervical Spine Collars

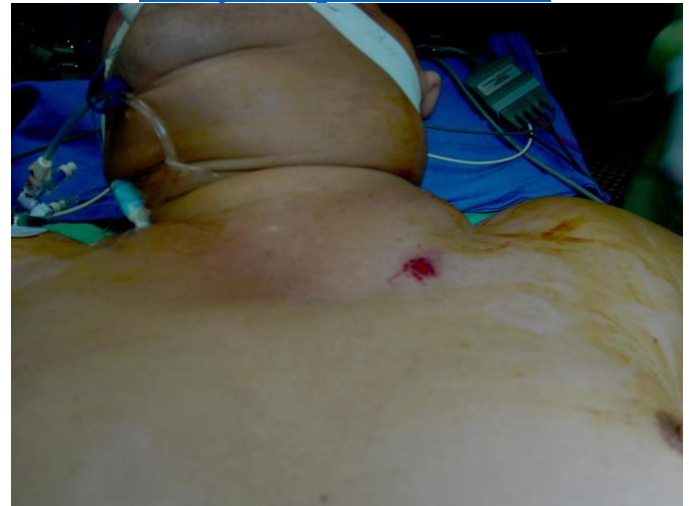Studies have shown that survivors of penetrating neck trauma are unlikely to have unstable cervical spines. The application of a cervical collar

may conceal serious injuries and further delay treatment. For these reasons, patients with penetrating neck trauma should not routinely be placed in cervical collars unless the patient exhibits focal neurologic deficits.

Outside of these guiding principles, the physical exam and clinical suspicion for major injury must be heavily relied upon. Given kinetic and thermal energy transfer, gunshot wounds are more likely than stab wounds to cause vascular injury.

Decision Making:

Airway management in these patients can be very difficult due to distortion or ongoing bleeding. Often patients with airway swelling will prefer to sit upright: there is no reason to “force” them to lie down in such circumstances. Expert assistance and video-assisted techniques are often necessary. Do not hesitate to perform a cricothyroidotomy or other surgical airway if necessary. This issue is discussed further in [Airway Management in Trauma](#).

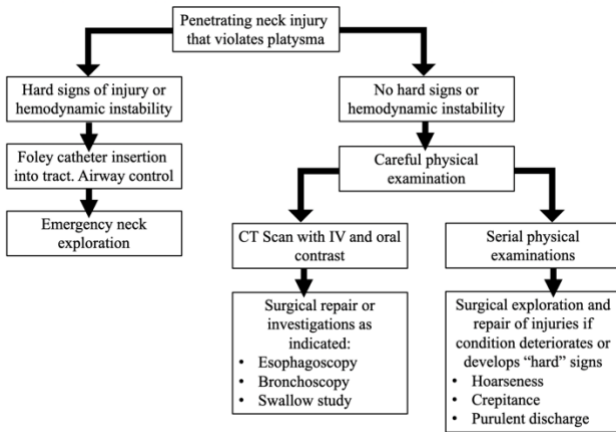


Left neck hematoma after stab wound. A hematoma like this has the potential to deviate the airway significantly and make safe orotracheal intubation difficult or impossible. Photo courtesy of Dr. Demetrios Demetriades.

We present one algorithm below, modified for low-resource settings, summarizing the considerations outlined in this chapter.

Approach to Penetrating Neck Trauma

Lillian Hsu, Pako Motlaleselelo, Mike M. Mallah



Lillian Hsu, MD
Medical University of South Carolina
USA

Pako Motlaleselelo, MBBS
University of Cape Town
South Africa

Mike M. Mallah, MD
Medical University of South Carolina
USA

Acknowledgment: Doug Norcross MD FACS

April 2023

An algorithm for management of penetrating neck injury, with different pathways on the right side depending on availability of CT scan in the same facility. Note that these patients should not be transported to another facility for CT scanning as they could deteriorate suddenly.

The stable patient

Preoperatively, it is the most helpful to obtain vascular imaging in the form of duplex ultrasonography or angiography if the patient is not exhibiting immediate signs of distress. As mentioned above, physical examination in the immediate aftermath of the injury is not always dependable, but surgeons can perform serial physical exams if initial presentation does not demand immediate exploration. Current data supports selective management based on physical exam and additional imaging, which is not always available. Patients may need to be observed for up to 48 hours, which can be resource consuming. Ultimately, when in doubt, the patient should undergo surgery, as a carefully performed negative neck exploration has less morbidity than a missed injury.

The unstable patient

Patients exhibiting one or more hard signs of vascular injury should be taken for immediate exploration. Neck exploration for trauma is performed through an oblique incision along the anterior border of the sternocleidomastoid, curving posteriorly near the angle of the mandible to avoid injury to the mandibular branch of the facial nerve. More details on neck exploration and repair of specific injuries are provided in another chapter in this Manual.

