

Approach to Maxillofacial Fractures Part 1: Midface

Richard Davis

Background:

The subject of Maxillofacial fractures is broad enough that it deserves its own chapter, as we have done here. However, fractures of the facial skeleton rarely exist without facial lacerations of some kind. These are addressed in a separate chapter; realistically you will be addressing both at the same time.

Patients with both mandibular and maxillary fractures are especially challenging- it can be difficult to restore dental occlusion, and the danger of palate fistula or other complications is higher. As you begin to care for patients with facial fractures, approach these “combined” fractures very carefully; refer them if you can until you have some experience with each type individually.

Remember that there is a frequent association between facial trauma, cervical spinal trauma, and head injury. It is common practice to empirically immobilize the patient’s cervical spine with a soft but rigid collar (“Philadelphia”) until cervical spine injury has been ruled out.

Here, we discuss the relevant anatomy and diagnostic maneuvers to classify a midface fracture. Each separate operation is then considered in its own chapter.

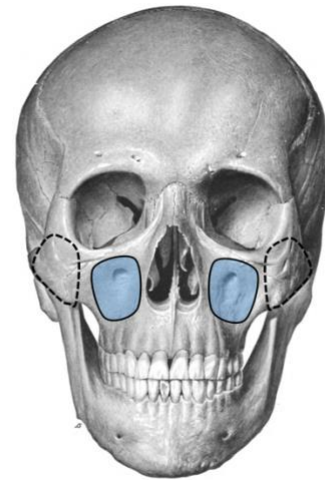
Anatomy:

The skin and nerves, lips, salivary glands and ducts are considered in the chapter on facial lacerations and injuries. Lacerations of the eyelids are considered in their own chapter. The globe and orbit are so inter-related that they will both be considered here.

When evaluating patients with facial injuries, it is crucial to understand the anatomy of the maxilla, zygoma, naso-orbito-ethmoid complex and the junction of these with the frontal bones.

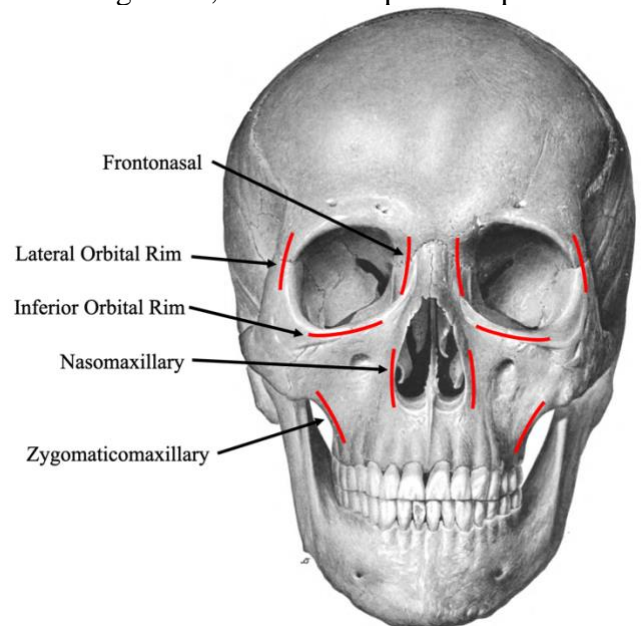
The midface can be conceptually pictured as a series of pillars, providing support and resisting injury, with very thin-walled spaces in between, filled with air or vital structures.

The largest air-filled space is the maxillary sinus. Its anterior and superior walls are paper-thin providing little structural support. The anterior aspects of its medial and lateral walls, on the other hand, are quite thick and serve to connect the hard palate and the upper teeth to the rest of the midface.



The maxillary sinuses (Light Blue) are air-filled spaces in the midface. Their anterior walls (including the foramina of the infraorbital nerves) and inferior walls (the orbital floors) are made of very thin bone which provides little structural support. The thickened portions of the zygoma (surrounded by dotted lines) are very thick: fractures rarely pass through these areas.

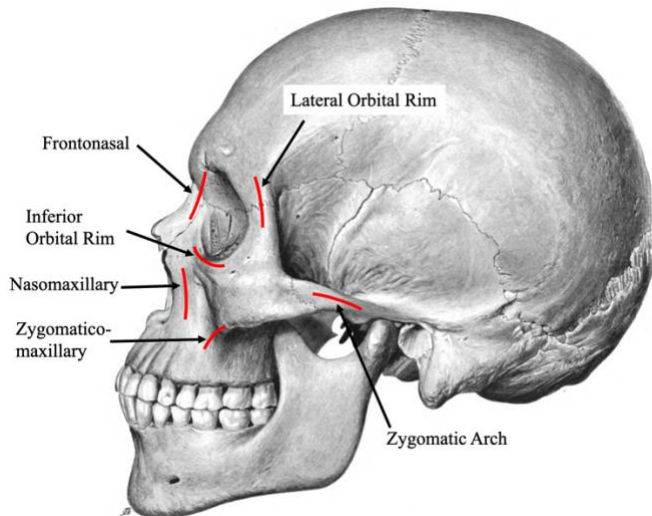
Keeping the maxillary sinuses in mind, we can think of a series of “pillars” in the intact midface where the structural support is strongest. Fractures commonly pass through these areas. They are also called “buttresses,” after the support structures of a building. Understanding where these buttresses are located allows us to communicate types of fractures, plan management, and to anticipate complications.



The buttresses of the midface, anterior view. These are the areas where fractures occur:

Approach to Maxillofacial Fractures Part 1: Midface

Richard Davis



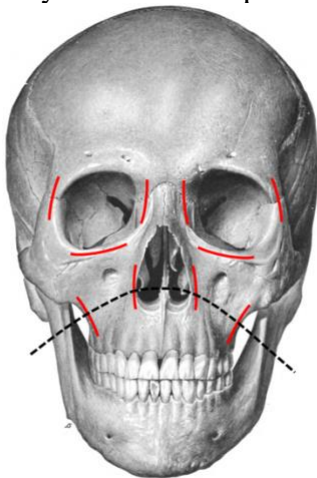
The buttresses of the midface, left lateral view. These are the areas where fractures occur

Fracture Patterns

With an understanding of the buttresses, we are well prepared to consider the typical fracture patterns and their classification.

A LeFort 1 fracture includes the Nasomaxillary and Zygomaticomaxillary buttresses. It can occur bilaterally or unilaterally; if unilateral there must also be a vertical fracture through the maxilla, extending into the hard palate.

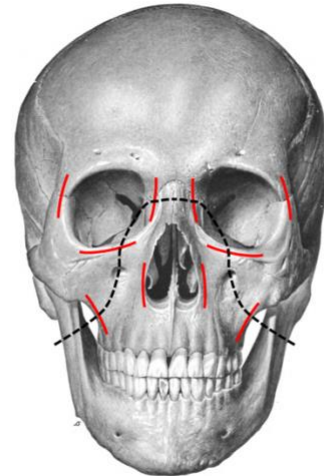
LeFort 1 fractures occurring alone are somewhat less usual than LeFort 2 and 3 fractures. This is because trauma to the midface will usually involve the zygoma as well, as it protrudes farther and is more easily struck and displaced.



LeFort 1 fracture (Dotted Line) passes through the Zygomaticomaxillary and Nasomaxillary buttresses. If the fracture is displaced, the patient will have malocclusion of the teeth.

A LeFort 2 fracture is a “pyramid” shaped fracture of the midface, passing through the Zygomaticomaxillary buttress, the Inferior Orbital Rim, and the Frontonasal Buttresses. It is common for the nasomaxillary buttress to be fractured as well when the midface sustains enough force to cause a LeFort 2 fracture.

A common complication with this type of fracture is orbital floor blowout and entrapment of the periorbital fat, with limitation of eye movement on the side of injury. Detection of this syndrome is described further below.

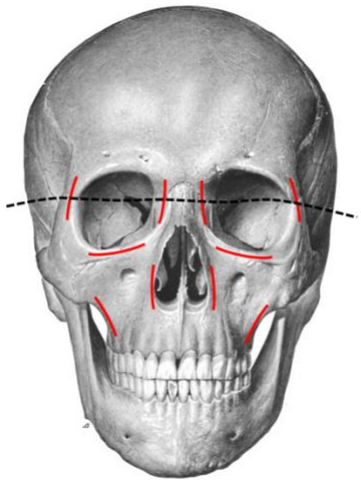


LeFort 2 fracture (Dotted Line) passes through the Zygomaticomaxillary buttress, the Inferior Orbital Rim, and the Frontonasal buttresses.

A LeFort 3 fracture is a complete dissociation of the midface from the skull. It would be extremely rare for a patient to have these fractures alone: usually this will exist concurrently with the LeFort 2 pattern. If the patient sustains a strong enough impact to the midface to detach it from the skull, it is not uncommon for most, or even all, of the other buttresses to be fractured as well.

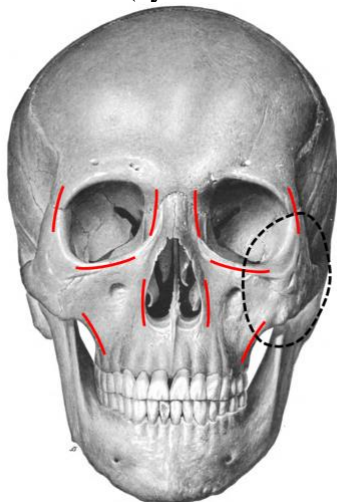
Approach to Maxillofacial Fractures Part 1: Midface

Richard Davis

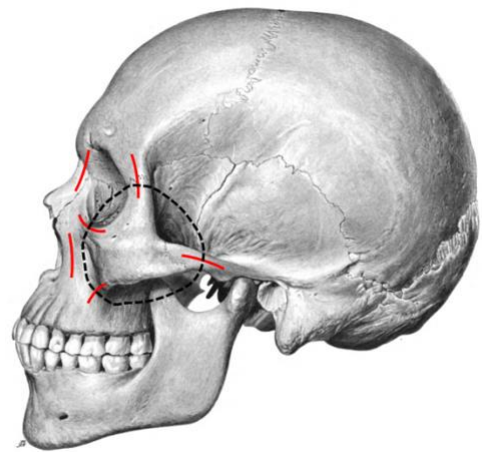


LeFort 3 fracture (Dotted Line) passes through the Lateral Orbital Rims and the Frontonasal Buttresses. Usually there will be other midface fractures as well.

A Zygomaticomaxillary complex fracture, sometimes called a “ZMC fracture,” is caused by a strong impact to the cheekbone. As above, the zygoma itself is very thick and strong, so the fractures are usually through its connections to the rest of the midface. A fracture of the orbital floor is always present with this fracture; sometimes the orbital floor contents will be entrapped and eye movement will be limited, as explained further below. The volume of the orbit itself will be changed, resulting in exophthalmos (outward protrusion of the eye) or enophthalmos (eye sunken inwards).

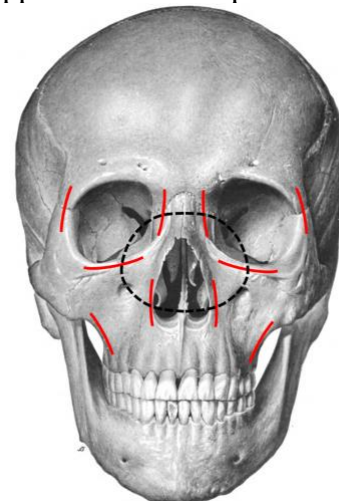


Left Zygomaticomaxillary Complex fracture, anterior view. Fractures are through the attachments of the zygoma to the midface: the Lateral Orbital Rim, the Inferior Orbital Rim, the Zygomaticomaxillary Buttress, and the Zygomatic Arch (not shown.)



Left Zygomaticomaxillary Complex fracture, lateral view. Fractures are through the attachments of the zygoma to the midface: the Lateral Orbital Rim, the Inferior Orbital Rim, the Zygomaticomaxillary Buttress, and the Zygomatic Arch.

A Naso-Orbital-Ethmoid Complex fracture, sometimes called a “NOE Fracture” is caused by a strong impact to the bridge of the nose. This fracture is relatively rare in isolation, but it is common for the NOE complex to be displaced separately in a patient with a LeFort 2 fracture. Reducing this fracture will be key to normal function of the nose (breathing and smell) and appearance of the space between the eyes.



Naso-Orbital-Ethmoid complex fracture, anterior view. Fractures are through the Frontonasal buttress, the inferior orbital rim, and the Nasomaxillary buttress. Note that there may also be a vertical fracture through the nasal bridge, which would lead to abnormal widening of the space between the eyes, also called “telecanthus.”

Approach to Maxillofacial Fractures Part 1: Midface

Richard Davis

Principles:

History

The mechanism of injury can be very helpful in determining the type of fracture. A single blow to the face, sustained during an assault, is usually not enough to cause a LeFort fracture, although a Zygomaticomaxillary Complex fracture could easily result. Similarly, if the patient was struck from behind and lost consciousness while standing, a ZMC or mandible fracture is usually the result rather than a more severe LeFort fracture.

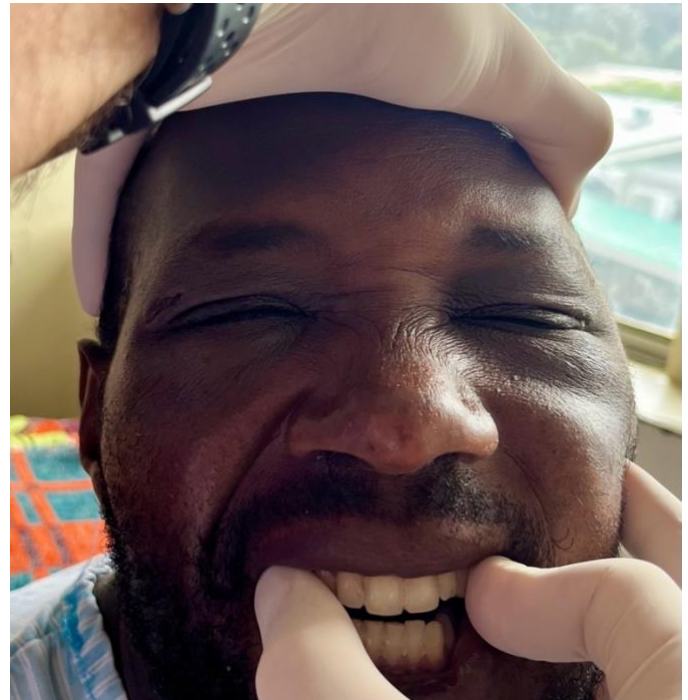Patients will complain of malocclusion if asked specifically, “Do you feel like your teeth fit together normally?” They may also complain of diplopia, sometimes after swelling has gone down enough for them to see again through both eyes.

Physical Examination

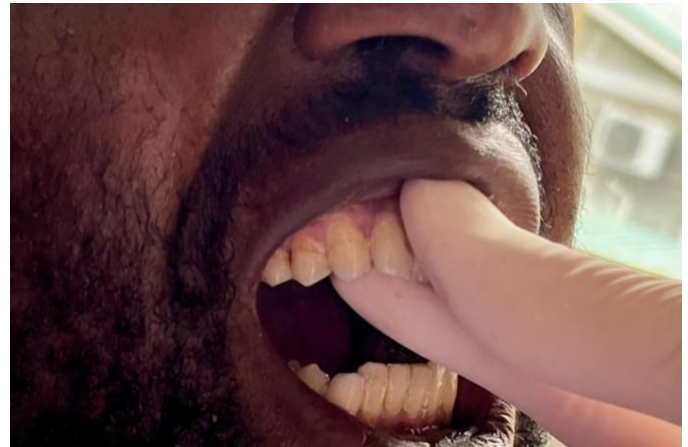As always, trauma patients must be examined systematically with attention to the airway, breathing and circulation first. Most patients with maxillofacial fractures will not have airway compromise, but if they do, do not hesitate to intubate them (see [Airway Management in Trauma](#).) Be prepared for a difficult airway, especially if the trauma occurred several hours previously. Do not attempt to nasally intubate anyone who has a mobile maxilla, as they may have a basilar skull fracture. (For similar reasons, do not insert a nasogastric tube.)

A careful physical examination, supplemented with well-performed plain x-rays, can help you determine which fracture patterns are present without a CT scan. The key is to understand the anatomy and fracture patterns described above, and then carefully detect fractures in their usual locations.

Start with one hand on the dome of the skull and the other grasping the maxillary teeth. Try to gently move them. If they move, try to determine whether they all move together, or whether the left and right maxilla move separately. Dental trauma can make this assessment confusing; try to assess the bone of the alveolar ridge, beneath the gingiva, rather than the teeth themselves.



Assess the maxilla for mobility by holding the skull firmly with one hand and attempting to move the maxillary teeth with the other.



Systematically assess all of the maxilla for mobility by grasping the bone of the alveolar ridge itself, rather than the teeth, which may move if injured even in the absence of a bony fracture.

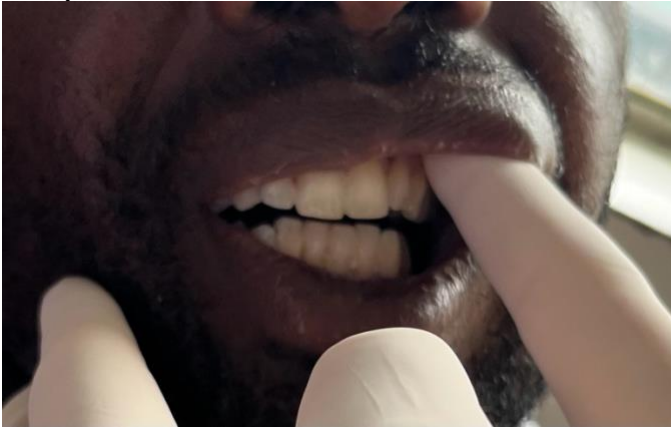Next, stick your finger inside the mouth on the upper gingivolabial sulcus, the recess between the upper lip and the gums. Feel the Zygomaticomaxillary and Nasomaxillary buttresses. You may feel a step-off here, or elicit tenderness when you palpate a fracture line.

If you have a mobile maxilla with tenderness in the gingivolabial sulcus, you have a LeFort fracture of some kind. If the maxilla is not mobile and the gingivolabial sulcus is tender on only one

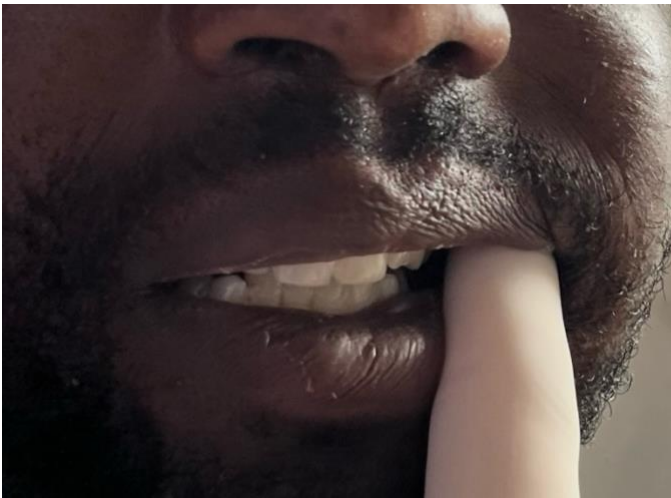Approach to Maxillofacial Fractures Part 1: Midface

Richard Davis

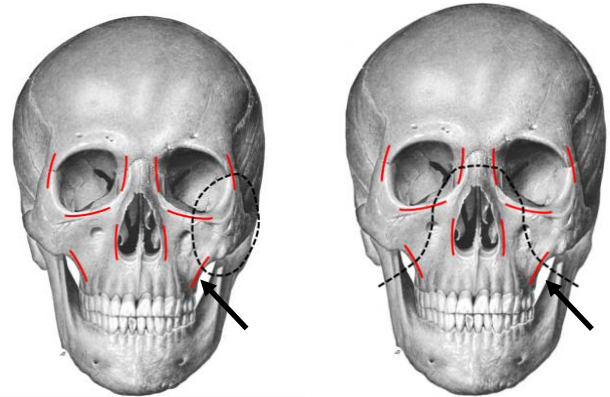
side, the patient probably has a Zygomaticomaxillary Complex fracture.



Assess the nasomaxillary buttress by inserting your finger into the gingivolabial sulcus, just lateral to the midline.

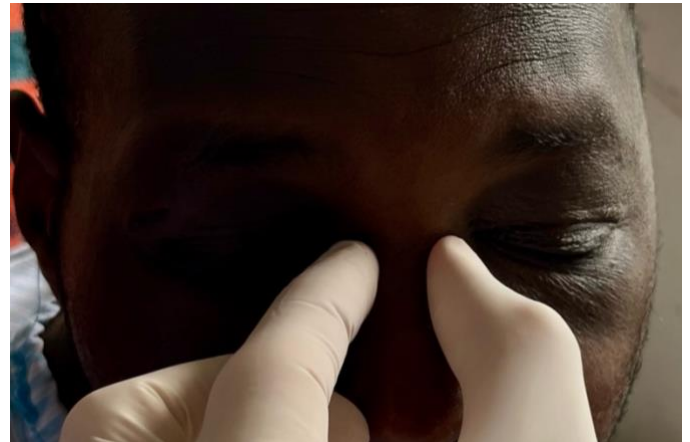

Assess the Zygomaticomaxillary buttress by sliding your finger laterally from the nasomaxillary buttress, to find the curve of the bone that unites the tooth-bearing maxilla and the cheekbone.



Palpate the Zygomaticomaxillary buttress, in the area shown by the Black arrow. If you feel tenderness or a deformity here and the maxilla is not mobile, the patient has a Zygomaticomaxillary complex (ZMC) fracture (Left). If you palpate tenderness or a deformity and the maxilla is mobile, likely the patient has a LeFort 1 or 2 fracture (LeFort 2 is shown on the Right.) In the latter case, you will feel tenderness or a stepoff on the right zygomaticomaxillary buttress as well.

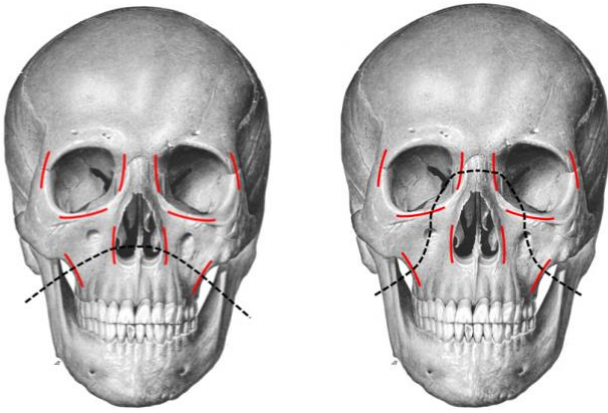
Now, go to the bridge of the nose. If it is tender, has crepittance, or has a deformity, and the patient has a mobile maxilla, they have a LeFort 2 or 3 fracture. If they have tenderness or deformity of the nose without a mobile maxilla, they have a nasal fracture or a Naso-Orbito-Ethmoid Complex fracture.



Once you have established whether the maxilla is mobile, palpating the bridge of the nose will allow you to determine whether the fracture involves this structure, as explained further below.

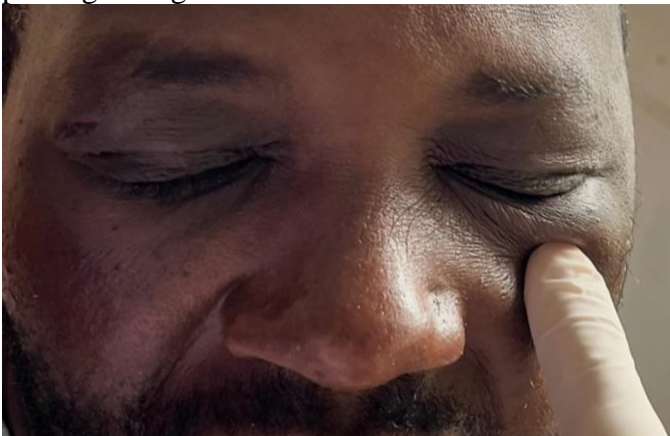Approach to Maxillofacial Fractures Part 1: Midface

Richard Davis



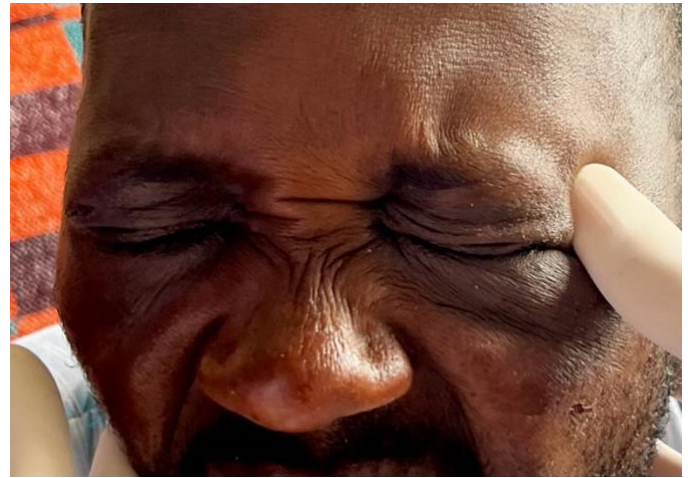In a patient with a mobile maxilla, you can tell the difference between a LeFort 1 fracture (Left) and a LeFort 2 fracture (Right) by whether the bridge of the nose is tender or deformed. If the bridge of the nose is deformed or tender without a mobile maxilla, they have a fracture of the nasal bone or naso-orbito-ethmoid complex.

Try to palpate the inferior orbital rim: you may feel a discontinuity, indicating either a LeFort 2 or a ZMC fracture. Numbness of the skin below the eye is a subtle sign of an inferior orbital rim fracture, passing through the foramen of the infraorbital nerve.

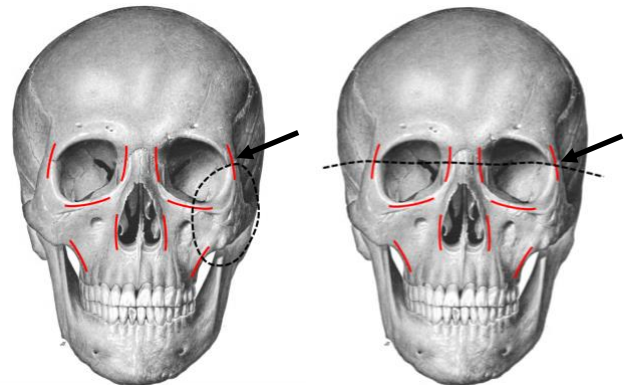


Palpate the central part of the inferior orbital rim, the part which is usually affected by fracture. You can feel a stepoff, a discontinuity in the bone, if there is a fracture. After palpating the bone, gently brush this area. If the patient is insensate here, it strongly suggests a fracture passing through the infraorbital foramen, pinching the nerve.

Now palpate the lateral orbital rim: crepitation, a deformity, or tenderness here indicates a lateral orbital rim fracture. If the maxilla is not mobile, a fracture here is likely part of a Zygomaticomaxillary Complex fracture. If the maxilla is mobile, the patient has a LeFort 3 fracture.



Palpate the lateral orbital rim, which is very close to the skin here. A fracture with displacement can be felt as a “step off.” If there is no displacement, tenderness here suggests a nondisplaced fracture. Note that this patient grimaces when pressure is applied here.



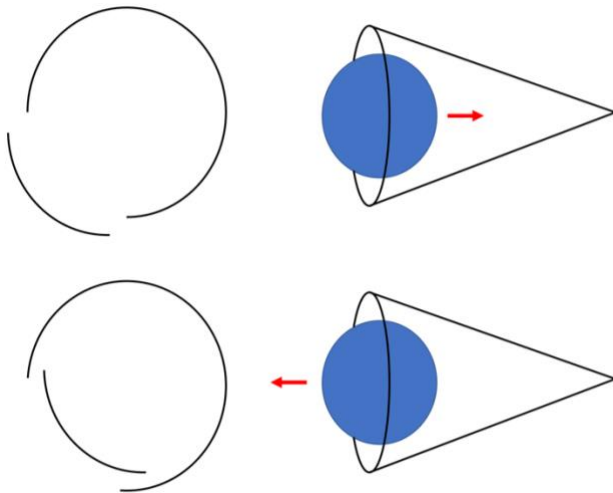
If you feel tenderness or deformity of the lateral orbital rim (Black arrow) the patient may have a Zygomaticomaxillary complex fracture (left) or a LeFort 3 fracture (right.) Note that a patient with a LeFort 3 fracture will almost always have other fractures of the maxilla or zygoma: the fracture will never be in only the straight dotted line shown here.

Palpate the Zygomatic arch, as it can be fractured alone, or as part of a Zygomaticomaxillary Complex fracture. On rare occasions, a depressed Zygomatic arch fracture will contact the coronoid process of the mandible and prevent the patient from closing their mouth (although inability to close the mouth can also indicate mandibular condyle fracture or dislocation.)

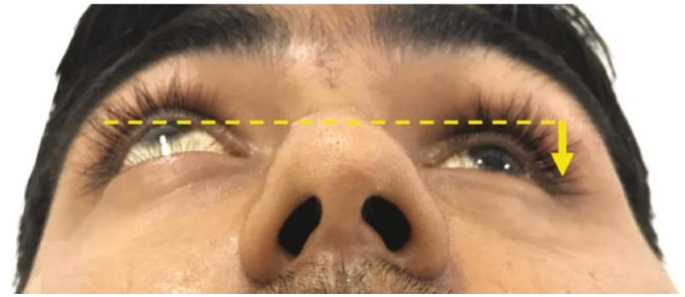
Inspect the eyes and the orbits, comparing them to each other. Bear in mind the effect that a fracture will have on the overall volume of the orbit, as shown here:

Approach to Maxillofacial Fractures Part 1: Midface

Richard Davis



The orbit is shaped like a cone, with the globe (eyeball) floating inside it. A fracture that causes an increase in the cone's volume (top images) will cause a "sunken eyeball" (enophthalmos) as the globe moves in the direction shown by the arrow. A fracture that causes a decrease in the cone's volume (bottom images) will cause protrusion of the globe, a "bulging eyeball" (exophthalmos) as the globe moves in the direction shown by the arrow.

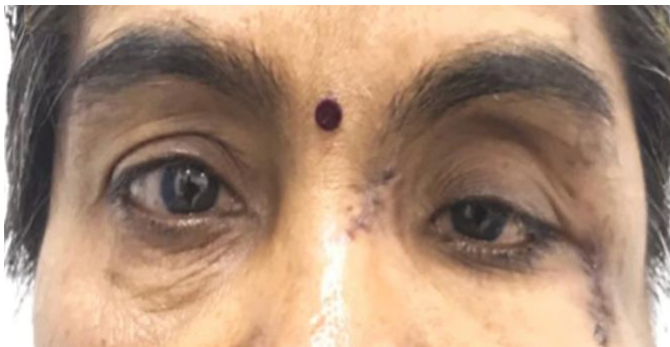

A more dramatic example seen using the same inspection technique as above. The left eye is sunken into its orbit (enophthalmos) likely due to a fracture involving the zygomaticomaxillary complex that has increased the orbit's volume. Note also that the patient is attempting to look upwards, but his left eye is unable to, likely due to periorbital fat entrapment by a fracture in the orbital floor. This is discussed further below. Source:

https://doi.org/10.1007/978-981-15-1346-6_56

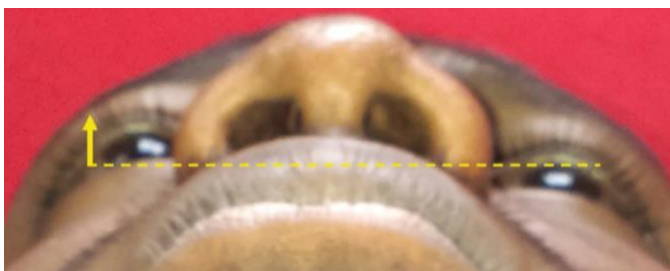Next, assess the eye movements. These maneuvers require a cooperative patient: in a comatose, or even a confused and combative patient, you may not be able to perform them. In the first few days after the operation, you may need to hold the affected eyelid open.

Ask the patient to follow your finger with their eyes and move your finger so that they look to the right and left, upwards and downwards. At the extremes, especially up and to the side, ask if they see one finger or two. In cases of mild entrapment, the patient's eyes will seem to move symmetrically but they will have diplopia when looking upwards or downwards to one or both sides. With severe entrapment, the affected eye will be unable to look either upwards or downwards at all. (Both mild and severe entrapment must be corrected surgically.)



Comparing both cheekbones and zygomatic arches, by inspection and palpation, will show deformity and asymmetry. In this case, the left cheekbone is depressed inferiorly and laterally, with resulting enophthalmos of the left eye and downward and lateral tension of the left eyelids. Source:

https://doi.org/10.1007/978-981-15-1346-6_56



Inspecting the face from inferiorly allows you to compare the eyes for degrees of protrusion, caused by loss or increase of volume in the orbit. In this case, the right eye protrudes (exophthalmos), likely due to a fracture involving the zygomaticomaxillary complex that has decreased the orbit's volume. Source:

https://doi.org/10.1007/978-981-15-1346-6_56

OPEN MANUAL OF SURGERY IN RESOURCE-LIMITED SETTINGS

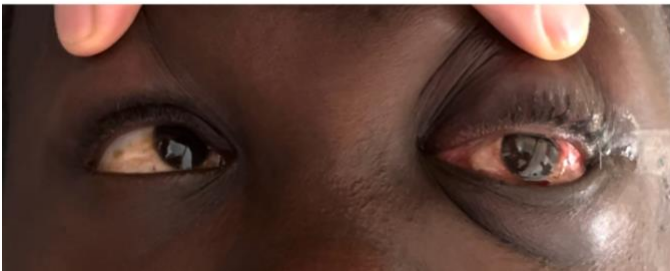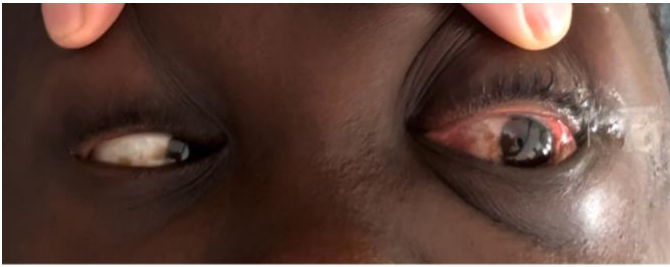www.vumc.org/global-surgical-atlas

This work is licensed under a [Creative Commons Attribution-ShareAlike 3.0 Unported License](https://creativecommons.org/licenses/by-sa/3.0/)

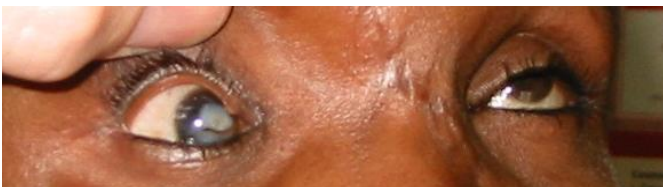

Approach to Maxillofacial Fractures Part 1: Midface

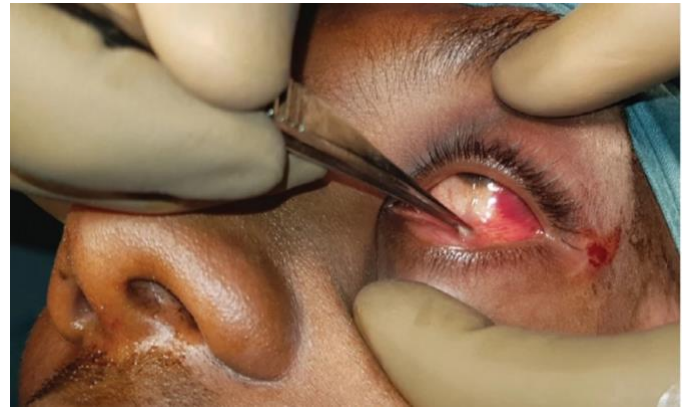Richard Davis



Patient with entrapment of the periorbital fat of the left eye within a fracture of the orbital floor. Top: The left eye is unable to look all the way to the left. Middle: The left eye is unable to look simultaneously down and to the left. Bottom: The left eye is unable to look upwards and to the left.



Long-term effects of untreated periorbital fat entrapment of the right eye, patient is attempting to look upwards. As seen here, the brain has started to ignore the input from that eye and the lid has closed- the examiner is holding it open. The patient also has a traumatic cataract of the right eye.



The forced duction test can be done in an awake and cooperative patient after administering topical anesthetic to the affected eye. It can also be done while the patient is under general anesthetic. Grasp the conjunctiva right where it meets the sclera and try to rotate the eye upwards; if there is entrapment of the periorbital fat, you will be unable to do this. Avoid causing an abrasion to the cornea while performing this maneuver. Source:

https://doi.org/10.1007/978-981-15-1346-6_56

In all of your examinations, try to determine whether the fracture is mobile, or whether there is associated deformity. If the fracture is completely nondisplaced, the patient will have tenderness at all of the fracture sites, and may have numbness in the distribution of the infraorbital nerve, but they will have no other malfunction. Their occlusion will be normal, their extraocular movements will be intact, and their cheekbones will be symmetrical. A non-displaced midface fracture with normal dental occlusion does not require surgical treatment. You should follow such patients closely for the next several weeks, however, as the action of the masseter muscle may pull the zygoma and zygomatic arch downwards over time.

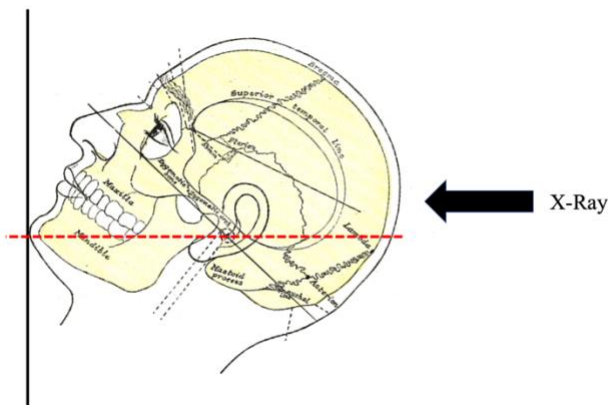
Imaging

After a careful examination of the midface, applying the knowledge and principles explained above, you should have a good idea of where the fractures are. Plain x-rays can supplement and confirm your suspicions and help you plan your surgical repair.

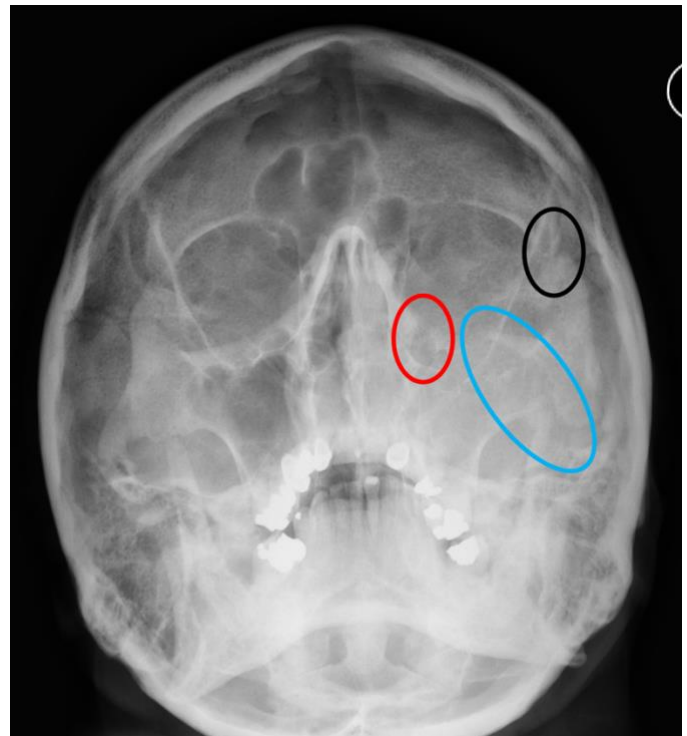
A plain anteroposterior x-ray of the skull does not help much. The occipital bone overlaps with the areas of interest. The Waters View x-ray frames the maxilla and zygoma inside of the skull, removing any other structures from the picture.

Approach to Maxillofacial Fractures Part 1: Midface

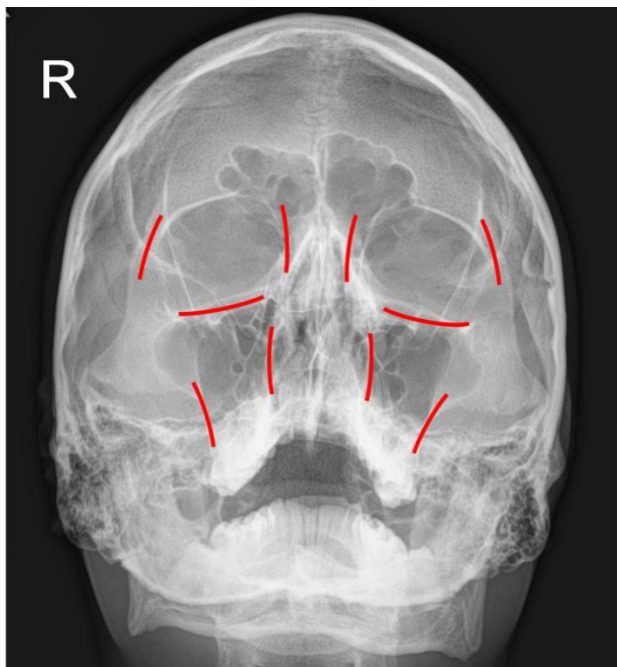
Richard Davis



In the Waters view of the skull, the x-ray beam passes through the midface but not through the bones of the skull itself, allowing these structures to be seen individually. The patient is positioned such that a line between the meatus of the ear and the chin (meato-mental line, dotted Red line) is perpendicular to the x-ray plate. In this position, the nose is about 3-4cm from the x-ray plate; if both the chin and the nose are touching the x-ray plate, the view will be inadequate.



Waters View x-ray shows a left Zygomaticomaxillary Complex fracture. A fracture is clearly seen involving both the inferior orbital rim and the zygomaticomaxillary buttress (Blue circle) with another fracture through the medial inferior orbital rim (Red circle.) Another fracture of the lateral orbital rim (Black circle) is also seen. The fluid-filled left maxillary sinus provides another clue that there is injury in this area- compare it with the clear, normal appearance of the right maxillary sinus. Case courtesy of Dr Derek Smith, From the case <https://radiopaedia.org/cases/35549?lang=us>



Normal Waters View x-ray with superimposed buttresses shown in Red. Case courtesy of Dr Bálint Botz, From the case <https://radiopaedia.org/cases/63083?lang=us>

Decision Making:

There are two major indications for surgery on a maxillofacial fracture: restoration of function and improvement of cosmesis. The following principles arise out of these indications:

- Retrobulbar hematoma is a surgical emergency that is usually diagnosed at CT scan. The treatment is lateral canthopexy and inferior canthotomy. As the operation is relatively minor, it should be done as soon as possible if you suspect this injury. The diagnosis and treatment are described in another chapter of this Manual.
- Fractures causing entrapment of the periorbital fat should be repaired as soon as possible, within 1-2 days. Extraocular muscles may also be entrapped and become damaged if not released.
- All fractures of the mandible should be treated, even if nondisplaced: forces exerted on the mandible by the masseter and pterygoid muscles

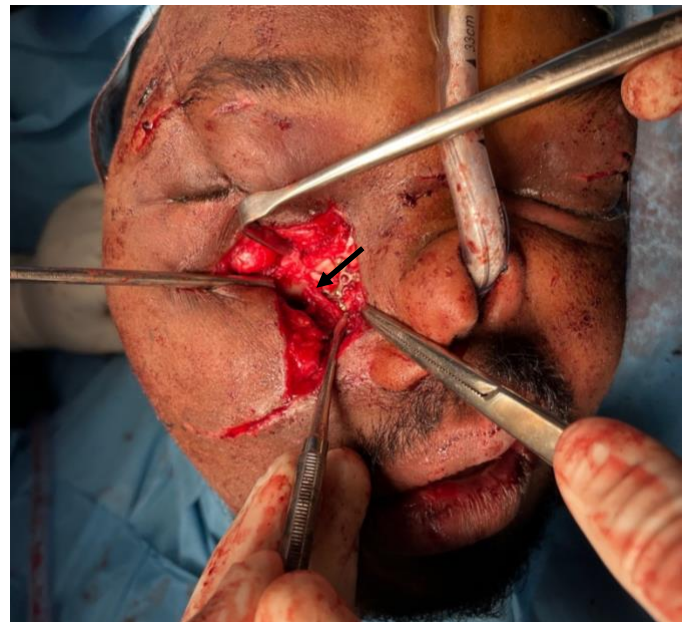Approach to Maxillofacial Fractures Part 1: Midface

Richard Davis

assure that all fractures will result in dental malocclusion.

- All fractures of the maxilla causing malocclusion should be treated: if there is no significant midface deformity, it may be enough to perform open reduction of the fractures and then place the patient in intermaxillary fixation.
- Patients in impoverished areas will often refuse surgery if they understand that it is only for “cosmetic” reasons. However, the deformities caused by LeFort 2, 3, and Zygomaticomaxillary Complex fractures are significant. These become apparent only after all the swelling has gone down and the resultant facial asymmetry and enophthalmos or exophthalmos are seen.

Repair of maxillofacial fractures is never an emergency, except in case of proven or suspected retrobulbar hematoma. If a fracture can easily be repaired during closure of the laceration, you may do so. We have seen this only a few times: usually the fracture is so extensive that the best approach is to wash out and close the laceration during initial management of the patient. Facial fracture repair can be done up to two weeks later; the usual timing is 3-5 days after trauma, to allow edema to subside. This interval also allows the patient to stabilize and other necessary investigations to be done.



An inferior orbital rim fracture after reduction and fixation through a facial laceration. The infraorbital nerve is shown by the Black arrow. The laceration had been closed poorly, so the surgeon was able to redo the closure at the same setting. This patient had both a LeFort2 and Zygomaticomaxillary complex fracture.

Not infrequently, a patient will have both maxillofacial fractures and severe head injury. When this occurs, it is reasonable to wait and see how much the patient will recover. Before two weeks have passed, it should be clearer whether the patient will recover- you can operate if they seem to be improving.

Facial lacerations that have been closed can be re-opened during open reduction and internal fixation of facial fractures, if doing so allows the surgeon to avoid making other incisions on the face to access the fractures. These incisions are described in depth in the specific chapters on fracture repair.

Richard Davis MD FACS FCS(ECSA)
AIC Kijabe Hospital
Kenya

November 2024

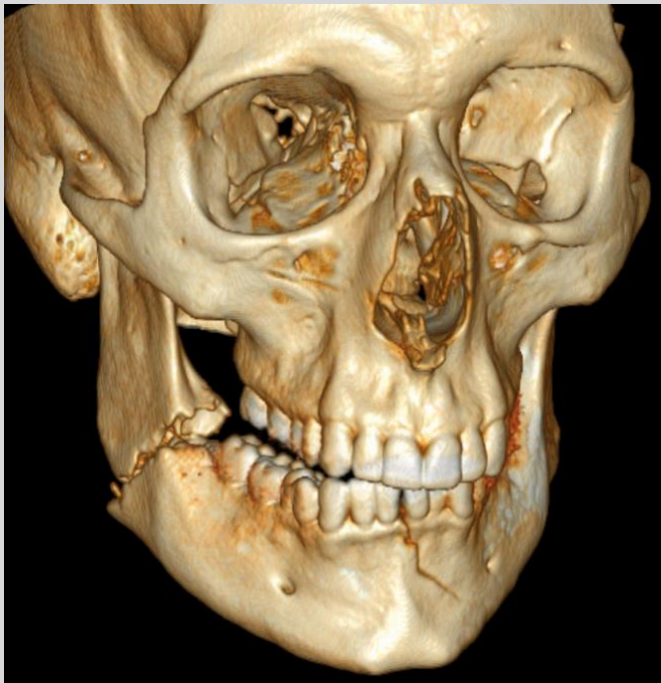Approach to Maxillofacial Fractures Part 1: Midface

Richard Davis

Resource-Rich Settings

Surgeons in resource-rich settings have a number of advantages, especially the ability to refer patients with facial fracture to specialists in this field. Other advantages include:

- CT scan with 3-dimensional reconstruction allows preoperative planning, including calculating the postoperative volume of the orbit to minimize postoperative exophthalmos or enophthalmos
- Titanium plates and miniplates, ultrathin titanium mesh, screws, and other material to assist in the reconstruction
- 3D printing of the skull as it will be after reconstruction, allowing preoperative cutting and bending of reconstructive plates to the exact dimensions needed.
- Specialist dentists and prosthodontists to create dentures or implants to be used during and after the healing process.



CT scanning with three-dimensional reconstruction makes it very easy to diagnose facial fractures. As a result, the diagnostic maneuvers described here are becoming a “lost art” in Resource-Rich settings. Source: Coronation Dental Specialty Group, CC BY 3.0 via Wikimedia Commons

Without these advantages, and especially if you are self-taught in this field, your outcomes will not be as good as they would be in the hands of a specialist. But if you do nothing at all, the patient will be much worse off, possibly unable to eat, see out of the affected eye, and with a very noticeable deformity.