

Anesthesia for Hepatic Resections

Dr Deidre Batty

Introduction:

Improved understanding of segmental anatomy of the liver has resulted in the evolution of liver resection over the last 25 years. Resultant improved perioperative outcome means that hepatic resection is now the most effective and potentially curative therapy for selected patients with benign and malignant hepatobiliary disease. The current approach to liver resection is aggressive because of modern advances such as:

- Enhanced knowledge of functional liver anatomy
- Appreciation of the functional reserve of the liver and capacity for regeneration
- Imaging modalities, including preoperative CT scan and intraoperative ultrasound
- Improved patient selection
- Improved surgical technique.
- Improved anesthetic management.

In this chapter we will focus on anesthetic management before, during, and after hepatic surgery. The following factors make hepatic surgery unique and challenging to the anesthetist:

- Surgery is of long duration predisposing to hypothermia, deep venous thrombosis, and drug accumulation.
- The large chevron (subcostal) incision causes substantial postoperative pain.
- Hemodynamic manipulation is required to reduce blood loss and gain adequate surgical access. An understanding of hemodynamic changes during resection is required.
- Warm ischemia time- understanding the limits for safe resection time. Large resections can predispose to hepatic insufficiency.
- Hemorrhage can be sudden and dramatic. Be prepared.
- All hepatic surgery patients are prone to developing coagulative impairment perioperatively (9% have delayed epidural removal if 3 or more segments are resected.) This is linked to the extent of the resection and length of operation.
- Patients may well have received chemotherapy. Some agents, particularly those used for

downstaging colorectal metastases, are associated with steatohepatitis. A chemotherapy-free interval of at least 6 weeks is recommended prior to resection.

Preoperative Assessment:

Your assessment must take into account:

- The primary pathology
- The site and volume of the planned resection.
- Co-morbidities such as pulmonary disease, renal dysfunction and cardiovascular system insufficiency
- The presence of co-existing liver disease
- The likelihood of blood transfusion. Bleeding is more likely with repeat surgery, porta hepatis (central) lesions, lesions close to large vessels, large extended resections and in patients with portal hypertension.

Work up usually involves:

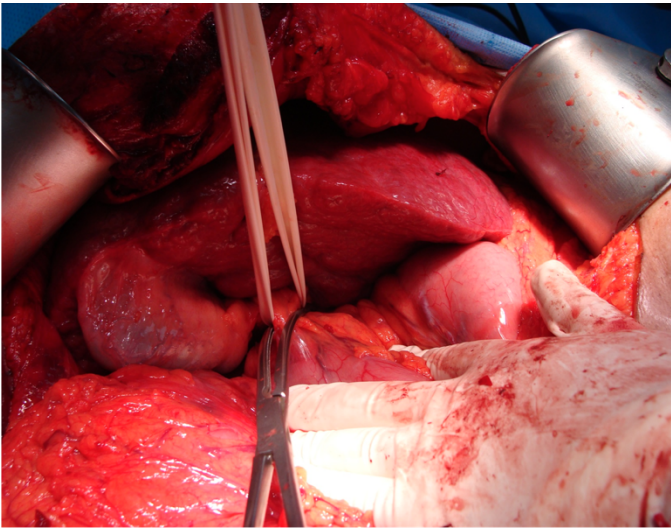
- Routine blood tests including complete blood count (hemogram), electrolytes and renal function, coagulation status and liver functions.
- Electrocardiogram, chest x-ray, lung function tests, liver imaging
- Hepatitis B and C serologies

A mainstay of hepatic surgery is the Pringle Maneuver, simultaneous occlusion of the hepatic artery and portal vein for up to 60 minutes. The Pringle Maneuver combined with low CVP technique constitutes a moderate hemodynamic challenge. If in doubt about the cardiovascular system status, a stress test or other assessment of cardiac function is recommended.



Anesthesia for Hepatic Resections

Dr Deidre Batty



The Pringle maneuver is occlusion of the hepatic artery, portal vein and common bile duct, performed here with both a latex drain and a vascular clamp. Source: DOI: 10.5772/51775

The large upper abdominal incision means that patients with respiratory co-morbidities such as Asthma or Chronic Obstructive Pulmonary Disease patients should be optimized preoperatively.

The following categories of patients are at high risk of morbidity and mortality:

- Patients with obstructive jaundice: Use preoperative stenting of the to decompress the biliary tract. Treat any infection that is present and give Vitamin K 10mg intramuscular for 3 days prior to surgery.
- Emergency surgery due to trauma or infection: Make sure these patients are adequately resuscitated and work closely with the surgeon.
- Cirrhotic patients. Childs A and B patients are eligible for surgery and tend to tolerate liver resections well, provided certain factors are heeded. Volume to be resected must be carefully assessed. Warm ischemia time limits must be adhered to and an increased incidence of bleeding, perioperative hepatic dysfunction and mortality must be understood and accepted by the clinicians, patient and family. However, patients with cirrhosis, impaired liver function and inadequate coagulation may well have altered cardiac function with hyperdynamic circulation, portal hypertension

and altered pulmonary reserve with hepatopulmonary syndrome. They are also at risk of developing hepatorenal syndrome.

Intraoperative Management

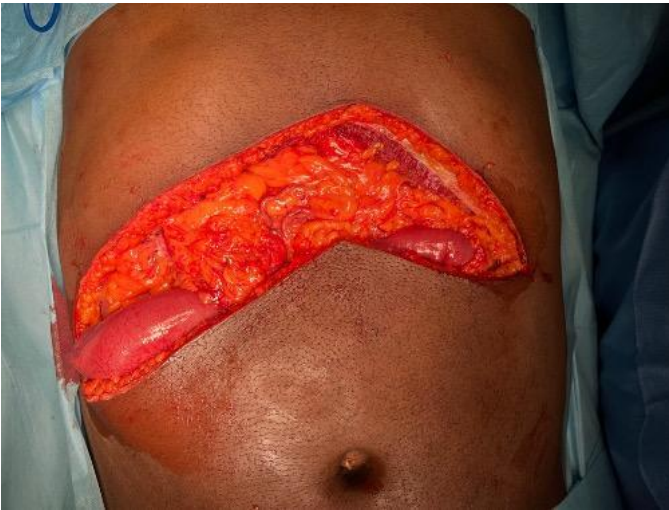No single anesthetic technique has been proven to be superior to others. Thoracic epidural analgesia is widely used for liver resection to minimize anesthetic requirements intra-operatively and to minimize pain postoperatively. Patients who are coagulopathic or who otherwise cause concern for epidural hematoma will be treated with general anesthesia alone with postoperative morphine or fentanyl, possibly delivered by Patient-Controlled Analgesia if this is available. The thoracic epidural anesthesia alternative (below) can also be utilized for these patients by substituting spinal morphine with low dose IV morphine.

Thoracic epidural for upper abdominal surgery has the following advantages:

- Optimal pain relief. It facilitates early extubation, mobilization and compliance with physiotherapy.
- Reduction in post operative pulmonary morbidity: It attenuates reflex spinal inhibition of diaphragmatic activity, decreases atelectasis, and decreases respiratory failure in high-risk patients.
- Reduction in the incidence of paralytic ileus. This benefit may be less when opiates are added to local anesthetics.
- A clinically significant reduction in cardiac morbidity. Decrease in myocardial infarction due to blockade of the T2 cardiac sympathetic outflow with coronary vasodilation.
- Improvement in patient-oriented outcomes such as patient satisfaction and health related quality of life.
- An attenuation of the surgical stress response.
- Earlier discharge due to all of the above advantages.

Anesthesia for Hepatic Resections

Dr Deidre Batty



Bilateral subcostal incision, typically used for major hepatic surgery.

Thoracic Epidural is preferred in our institution for:

- Major open liver resection
- Complex minor resection
i.e. with posterior or central position +/- redo surgery +/- portal hypertension +/- IVC involvement +/- biliary enteric anastomosis
- Comorbidities
i.e. coagulation disorder where epidural anesthesia is indicated for comorbidity management intra/ and or postoperatively.

Alternatives to thoracic epidural are preferred in our institution for:

- Minor liver resection (<3 segments)
- Minor open liver resection
- Laparoscopic liver resection
- Major or complex minor resection if thoracic epidural is not possible/feasible
- In scarce resource setting. (Thoracic epidurals should be continued for at least 48hrs and preferably 72 hours postoperatively for full benefit and must be monitored in a high care facility. Epidural alternative requires a minimum of 24-hour high care monitoring because of the risk of respiratory depression. It may be preferable in a high bed pressure situation.)

Alternatives to thoracic epidural consist of:

- Intrathecal morphine (ITM) at start of procedure
- IV lignocaine and IV dexmedetomidine infusions started prior to incision and continued into high care for up to 24 hours.
- Local bupivacaine at port sites for laparoscopic work (Consider intrathecal and other lignocaine dose given when calculating dose.)
- If the case proceeds to open surgery stop IV lignocaine half an hour prior to end of procedure and add wound infusion catheters placed at the end of surgery. 0.25% bupivacaine bolus plus 0.2 % infusion for up to 3 days postoperatively. Consider intrathecal and other lignocaine dose given when calculating dose.

These thoracic epidural alternatives emulate the stress response reducing effects of epidural analgesia, including sympatholytic effects (dexmedetomidine), cytokine reducing effects (lignocaine), and analgesic effects (spinal morphine, wound infusion catheter).

Strategies for Hepato-Pancreatico-Biliary Surgery

Monitoring and Induction

Continuous electrocardiography, oximetry, capnography, and urinary catheter are required. A 14- or 16-gauge IV access is required. Most authors recommend a second large peripheral line.

Arterial line and continuous venous pressure (CVP) monitoring are required in all but the most minor resections. Both are necessary if the low CVP technique is to be employed. In low resource settings, the anesthetist may have only one pressure transducer, so it is acceptable to monitor the arterial pressure continuously and the CVP intermittently using the same transducer.

Temperature monitoring and whole-body warming are required. Hypothermia contributes to coagulation abnormalities. Large heat loss can occur from the liver surface.

Anesthesia

Premedicate with low dose benzodiazepines such as midazolam, titrate to effect.

OPEN MANUAL OF SURGERY IN RESOURCE-LIMITED SETTINGS

www.vumc.org/global-surgical-atlas

This work is licensed under a [Creative Commons Attribution-ShareAlike 3.0 Unported License](https://creativecommons.org/licenses/by-sa/3.0/)



Anesthesia for Hepatic Resections

Dr Deidre Batty

Regarding the epidural catheter, we offer the following advice:

- Site the epidural at T9 – T10. Any higher than this can lead to perineal and urinary catheter discomfort without much benefit gained. Insertion is also easier at this level (horizontal).
- Bupivacaine is the usual medication for the epidural. However, adding lignocaine to the initial bupivacaine dose (3mls 2% lignocaine plus 7mls 0.5% Marcaine) enables quick establishment of levels. (It is advised to establish an adequate level prior to induction.)
- Most patients require 10-15 mL of 0.5% bupivacaine to establish a block at T4-T5. One can “paint the fence” after half an hour with half the initial volume and concentration (5 - 7.5, mL 0.25% bupivacaine) and then maintain the block with 3/4 of the original volume (7-12mL) hourly. This can be done with a 0.25% bupivacaine infusion but is best done with hourly boluses for maximal hemodynamic manipulation and effect on CVP for liver resection.

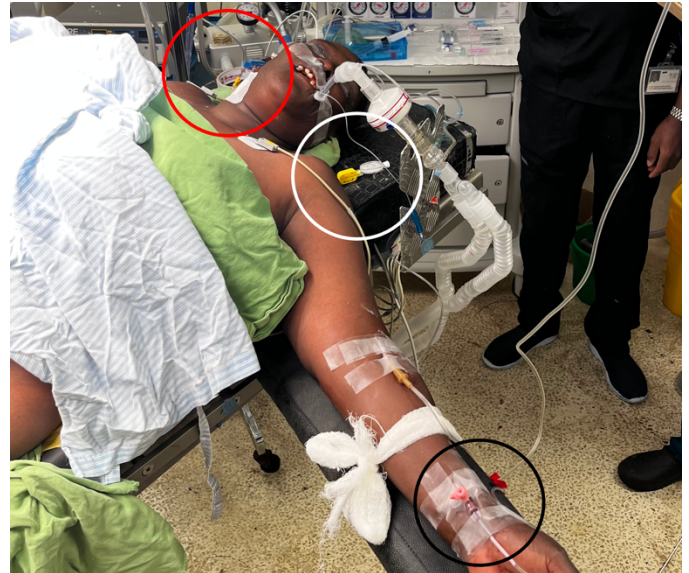The ideal anesthetic technique is to maintain a slow heart rate (60 -70 bpm) while vasodilating the patient, dropping systolic blood pressure by 30% and lowering the CVP towards 5 mm hg. Propofol induction aided by intravenous midazolam with rocuronium works very well. (Cisatracurium is used if there are concerns about renal function or delayed rocuronium metabolism due to jaundice.) Very little muscle relaxation is required due to the high epidural.

Lung protective ventilatory strategies are employed maintaining low peak pressures and normocapnia. Elevated CO₂ will lead to sympathetic stimulation and splanchnic vasoconstriction.

Isoflurane and sevoflurane dilate the hepatic artery and lower splanchnic vascular resistance-this is beneficial during cross clamping. They also maintain the hepatic artery/portal vein flow ratio of 70%:30%. Sevoflurane has the added advantage of rapid wake up. This expedites communication with the patient and early assessment of epidural levels and efficacy. Avoid intravenous opiates if possible

due to the risk of postoperative respiratory depression when combined with epidural opiates.

If narcotics are required in addition to an appropriately working epidural, preferably use fentanyl. Nitrous Oxide should be avoided if possible as it decreases liver blood flow.



Patient ready for liver resection: Right internal jugular central venous catheter (Red circle) allows measurement of central venous pressure, which should be kept in the range of 5mmHg. Thoracic epidural catheter (White circle) will allow for adequate analgesia with minimal narcotics after a large abdominal incision. Arterial line (Black circle) allows for continuous measurement of blood pressure and control with vasoactive medications, if necessary.

Hepatic surgery proceeds in the three steps, each of which requires special consideration from the anesthetist. These are: Exploration, Parenchymal Transection, and Hemostasis. We will consider each one separately:

Exploration: Mobilization with Vascular Control

The cornerstone of low CVP anesthesia is fluid restriction until the hepatic parenchyma has been transected. Fluid restriction combined with vasodilation from the epidural leads to a state of **relative hypovolaemia**. Use of a high epidural (T4) (sympathetic blockade occurs up to two segments higher than sensory blockade (T2) tends to suppress any tachycardiac response resulting in lowered Mean Arterial Pressure (up to 30% drop), stable

Anesthesia for Hepatic Resections

Dr Deidre Batty

heart rate and low CVP. This is ideal for the resection phase. During this initial phase, the anesthetist will gradually allow these conditions to be achieved.

The Exploration phase of the operation involves.

- Bilateral subcostal incision
- Placement of a self-retaining retractor (such as the Thompson retractor) for adequate exposure
- Intraoperative ultrasound
- Exclusion of extrahepatic disease.
- Mobilization of the liver
- Gaining vascular control

By the time the next phase will begin, the CVP has drifted down to around 5 mmHg. If the CVP does not drop appropriately one can use 0.25g/kg of Sodium Mannitol for diuresis.

If general anesthesia alone is used, nitroglycerine and furosemide can be employed to lower the CVP.

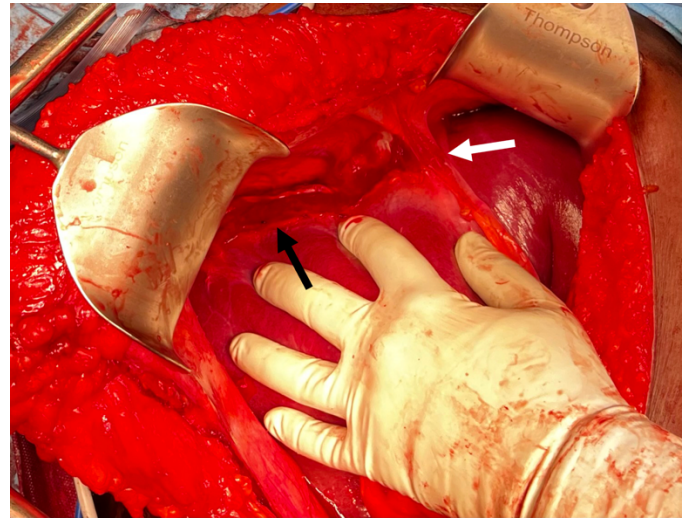In about 2% of patients an ongoing infusion of vasoconstrictor is required to maintain adequate Mean Arterial Pressure of 60mmHg and systolic blood pressure of 90mmHg. This is best achieved with a phenylephrine infusion titrated to effect. Very low doses are usually required.

Parenchymal Transection

Once the liver is mobilized off the inferior vena cava, vascular control is achieved, and intraoperative ultrasound has been used to confirm the position and number of tumors. Resection now begins. This is facilitated by intermittent clamping of the porta hepatis, the Pringle Maneuver. The patient should be 15 degrees Trendelenburg (head down) to minimize the risk of air embolus. (In reality surgeons generally prefer the patient slightly head up.) **Note** that uncontrolled bleeding can occur during this phase due to injury to the vasculature.

Liver mobilization can increase pressure on the inferior vena cava, reducing venous return and leading to hemodynamic instability. This can be dramatic because relative hypovolemia has been employed. Steps to correct this include asking the surgeon to release pressure on the IVC, fluid bolus

to improve preload, and temporizing with ephedrine boluses.



Mobilization of the liver by dividing its suspensory ligaments, such as the right triangular ligament (Black arrow) and the falciform / coronary ligament (White arrow) leaves the liver much more mobile. Excessive pressure or torsion of the liver after these ligaments have been released can lead to pressure on the inferior vena cava and impaired venous return to the heart.

Once transection is complete the surgeons must move on to the following step and achieve hemostasis.

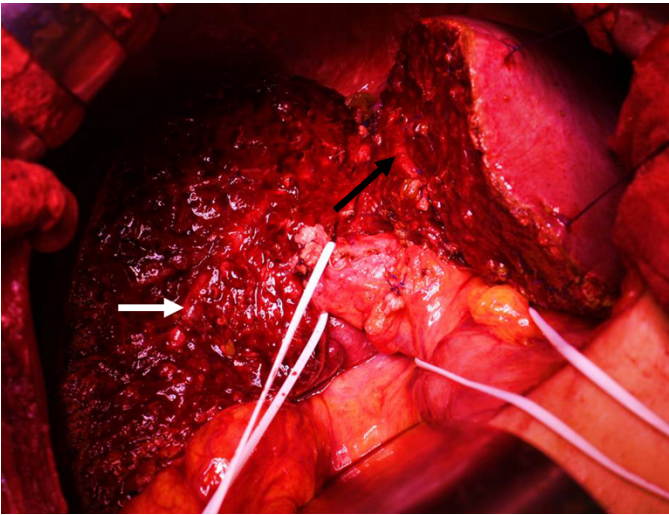
Hemostasis

At this point the patient is volume repleted with the appropriate fluid: crystalloid for maintenance and colloid, if available, for blood loss. Central venous pressure is normalized. The surgeons may request the Valsalva maneuver to increase the CVP and detect bleeding. Argon Laser or high-power diathermy is utilized to coagulate the liver surface. Procoagulant solutions, if available, are sprayed over the surface to reduce the chance of bleeding and bile leaks.

Once hemostasis is achieved, the patient is closed, anesthesia is reversed, the patient is extubated and transported to an intensive care unit for postoperative care and epidural monitoring.

Anesthesia for Hepatic Resections

Dr Deidre Batty



Completed hepatic resection (right anterior sectionectomy) with hemostasis achieved. The middle hepatic vein (Black arrow) and the right hepatic vein (White arrow) are adjacent to the resection margins, demonstrating the potential for rapid uncontrolled blood loss during hepatic surgery. Source: DOI: 10.5772/51029

Problems With The Low CVP Technique

The presence of a low central venous pressure and potential for wide open veins gives rise to the risk of pulmonary embolus (Incidence 0.1 %.)

This technique also allows very little reserve. Patients are volume depleted, maximally venodilated with a high epidural catheter. Potential problems are:

- The beta-blocked patient is relatively resistant to ephedrine. Phenylephrine is potentially dangerous as an increase in SVR may induce life threatening bradycardia.
- The jaundiced patient with or without elevated liver enzymes and the cardiovascular impaired patient should not be intensively fluid depleted because of the potential for worsening cholestasis or cardiovascular instability respectively.
- Patients can still bleed:
 - Due to hepatic vein backbleeding.
 - Due to injury to hepatic veins near the IVC during hepatic mobilization.
 - During parenchymal resection to gain vascular control.

Bleeding during hepatic surgery, especially from the venous system, is unpredictable and can be massive requiring rapid and judicious resuscitation. This may be difficult to do when there is little reserve present.

The low CVP technique for hepatic resection does not appear to predispose to an increase in renal failure. However transient asymptomatic increases in serum creatinine may occur.

Postoperative Care

After surgery, patients require high care monitoring with emphasis on epidural monitoring and hemodynamic stability. Hypoxia and hypotension will put the liver remnant at risk for further ischemic injury as will septicemia or drug toxicity. These patients tend to have a hyperdynamic circulation which resolves in 3-5 days. The increase in splanchnic blood flow aids in rapid regeneration of the liver. About half of all patients will develop ascites and require volume expansion initially.

Glycemic control with an insulin infusion is usually required. Hyperglycemia inhibits hepatic regeneration. Hypoglycemia is extremely rare and should raise concerns about ischemic liver damage.

Protection against stress ulceration is advised as gastrointestinal tract bleeding may precipitate encephalopathy in an already compromised liver.

Patients generally continue with their epidural infusions for 72 hours, maintaining a T4 -5 level with a 0.1 % bupivacaine /opiate infusion and 0.25% marcaine bolus as needed for “top-ups.”

For opiate infusion, morphine 0.05mg/mL or fentanyl 2-4 mcg/ml can be added. Morphine has the added advantage of providing analgesia for up to 24 hours after removal of the epidural. At low doses of morphine (0.05mg/mL) there is less incidence of nausea, pruritus and respiratory depression over 3 days than when higher concentrations are used. Addition of an opiate to the bupivacaine infusion is necessary to prevent tachyphylaxis, which will result in a need to progressively increase infusion rates to maintain the same sensory level.

Anesthesia for Hepatic Resections

Dr Deidre Batty

Coagulation is altered postoperatively with INR and platelets most commonly affected. In 9% of cases, epidural removal must be delayed to 5 days postoperatively, or fresh frozen plasma infused to drop INR to <1.5 prior to removal.

Hepatic and renal function are monitored daily. Liver enzymes tend to rise in the first few days starting to normalize by day 5. Expect rises in transaminases of up to 1000mg/dL. Levels higher than this again raise concerns of ischemic liver injury which is more likely to occur with fatty or cirrhotic livers, large resections and prolonged warm ischemic time.

It is probably best to avoid paracetamol (acetaminophen) initially. Remember that even in segmental resections, the liver has had some ischemic time. Non-steroidal anti-inflammatory medications may decrease regeneration and predispose to acute kidney injury particularly in the clinical setting of blood loss and cardiovascular instability. For standardized orders, an “opt-in” rather than “opt-out” policy with paracetamol and NSAIDS is advised with reduction in doses as appropriate.

Deep venous thrombosis prophylaxis should be implemented, with lower limb intermittent compression devices and low molecular weight heparin started 6 hours postoperatively.

Patients undergoing large resections without the benefit of epidural analgesia are more likely to require postoperative ventilation.

Postoperative Morbidity and Mortality

Independent predictors for postoperative complications are.

- ASA Classification
- The presence of steatosis
- The number of segments resected.
- Simultaneous extrahepatic resection.
- Perioperative blood transfusion lessens disease free survival with colo-rectal metastases and increases mortality to 11% if more than 2 units are transfused.

Complications occur in about 20% of cases and include pulmonary infection, intra-abdominal

abscess, bile leak, postoperative hemorrhage, hepatic failure (1-3%) and renal failure (1-3%.)

Postoperative mortality is most commonly due to myocardial infarction, cerebrovascular accident, sepsis with multiorgan failure, pulmonary embolism and duodenal perforation.

Conclusion:

Successful liver resection depends on:

- Adequate pre-operative counselling of the patient
- A good knowledge of liver pathophysiology
- A working team
- The ability to manage intraoperative hemodynamic challenges.
- Good post-operative analgesia and care

“In some series, outcomes in liver resection have been directly related to the ability of the anesthetist to provide rapid, warm resuscitation, to maintain perfusion & euthermia and to avoid acidosis.”

-The Society for Surgery of the Alimentary Tract 2006

Dr Deidre Batty, MBChB FCA(SA)

Department of Anaesthesia & Perioperative Medicine

University of Cape Town

South Africa

October 2023

See also:

[References](#)- Further Reading

[Guidelines](#)- Anesthesia for Hepatobiliary Surgery
University of Cape Town Department of Anesthesia and Perioperative Medicine

OPEN MANUAL OF SURGERY IN RESOURCE-LIMITED SETTINGS

www.vumc.org/global-surgical-atlas

This work is licensed under a [Creative Commons Attribution-ShareAlike 3.0 Unported License](https://creativecommons.org/licenses/by-sa/3.0/)

