



# Melanoma

Kaushik Mukherjee MD

A. Scott Pearson MD


# Disclosures

- You still have to study...
- Not all-inclusive
- No Western blots
- Extensive use of Google Image Search and Sabiston

# Melanoma Basics

- 8<sup>th</sup> most common cancer in US, 4-5% of all skin cancers
- 62,190 new cases per year, 7,910 deaths in 2006
- 20 times more frequent in Caucasians than African-Americans or Asians
- Risk factors
  - UV exposure
  - Congenital nevi, Dysplastic nevus syndrome, Spitz nevi
  - Xeroderma pigmentosum
  - Non-melanoma skin cancer
  - Family history of melanoma (5-10%)
    - Chr 1p—sporadic and familial melanoma
    - Chr 9p—sporadic melanoma alone
  - Somatic mutations in p16 tumor suppressor gene (not-so-sweet 16)

# Common Clinical Features

- Asymmetric outline
- Borders changing/irregular
- Color variation (not always)
- Diameter > 6mm
- e l e  a t i o n

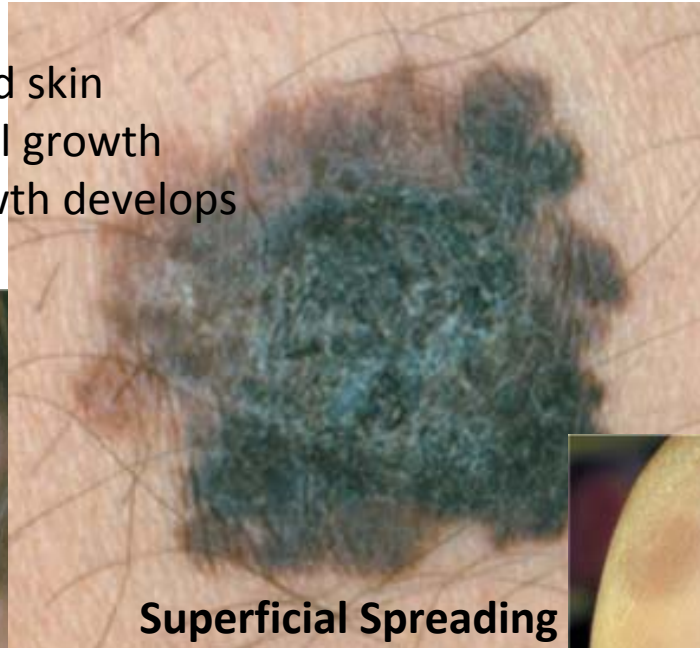- Also: unknown primary melanoma and noncutaneous melanoma



# Types of Melanoma

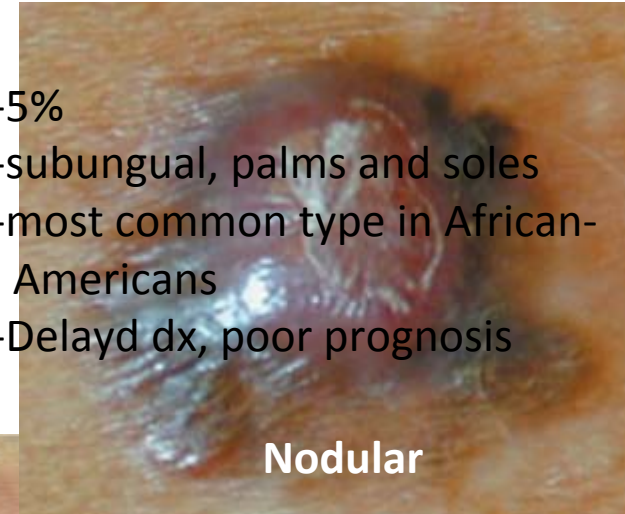- 15%
- early vertical growth
- worst prognosis

- 70%
- not always sun-damaged skin
- flat, dark pigment, radial growth
- thickens as vertical growth develops

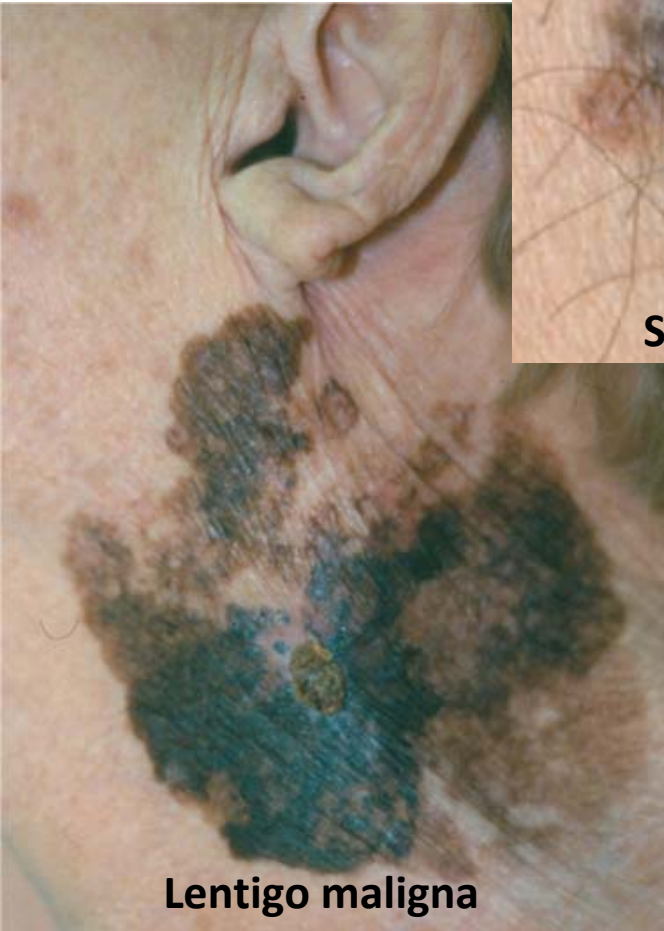

**Superficial Spreading**

- 5%
- subungual, palms and soles
- most common type in African-Americans
- Delayed dx, poor prognosis

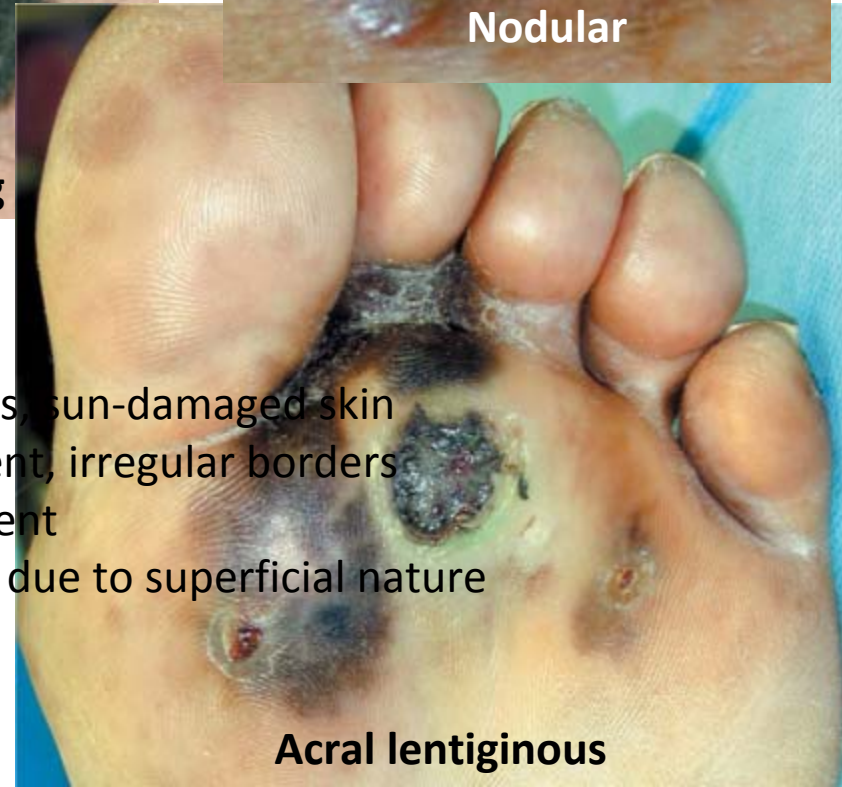

**Nodular**



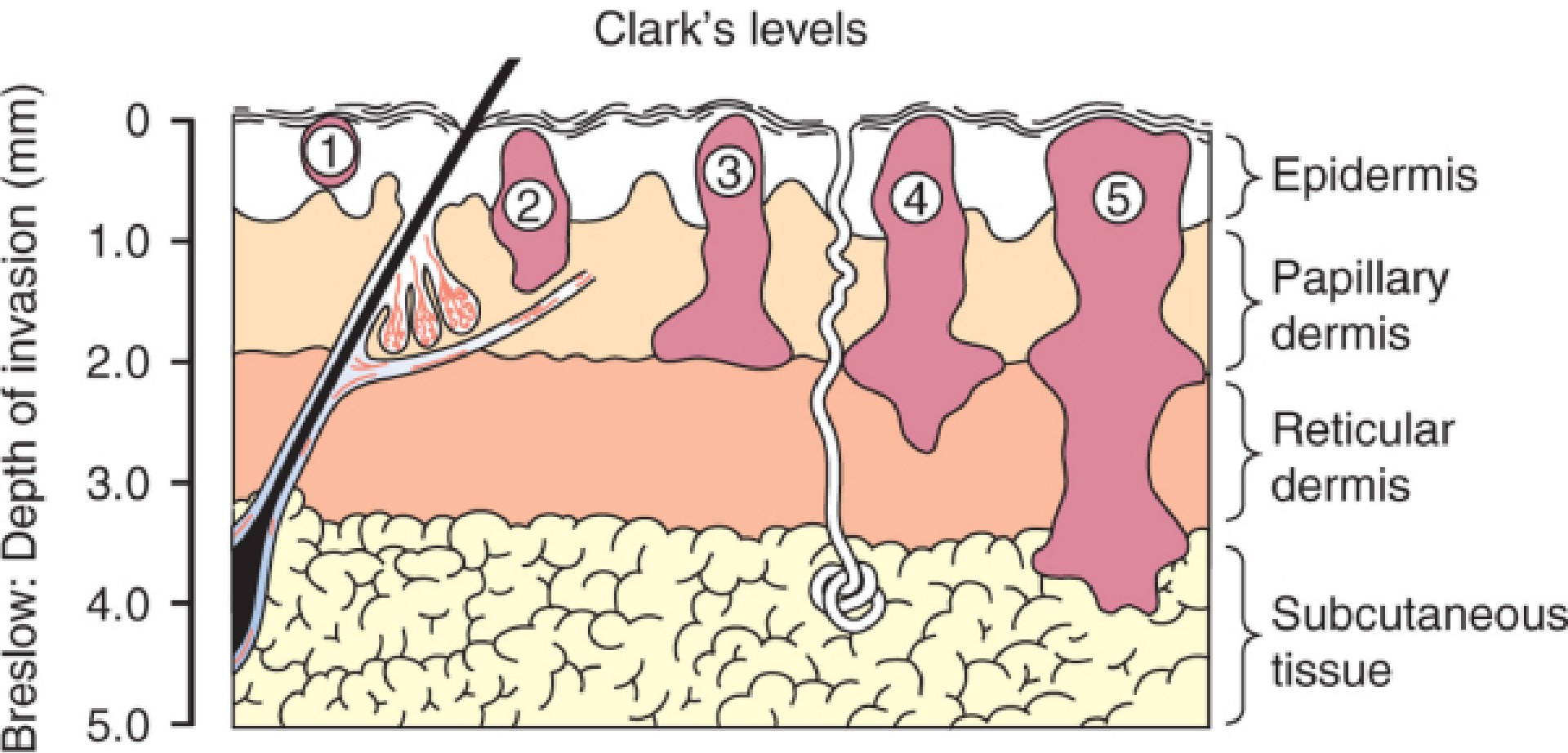
**Lentigo maligna**

- 10%
- older individuals, sun-damaged skin
- flat, dark pigment, irregular borders
- slow development
- good prognosis due to superficial nature



**Acral lentiginous**

# Hope that the Cancer is only Skin Deep



# How to Interpret Melanoma Staging

T N M

1:  $\leq 1\text{mm}$

2:  $1 < x \leq 2\text{mm}$

3:  $2 < x \leq 4\text{mm}$

4:  $> 4\text{mm}$

a = no  
ulceration  
b = ulceration

0: no nodes

1: 1 node

2: 2-3 nodes OR  
in-transit with  
no nodes

3: 4+ nodes,  
Matted,  
In-transit, or  
Satellites with  
nodes

a = micro-mets  
b = clinically  
apparent mets

0: none

1: metastasis

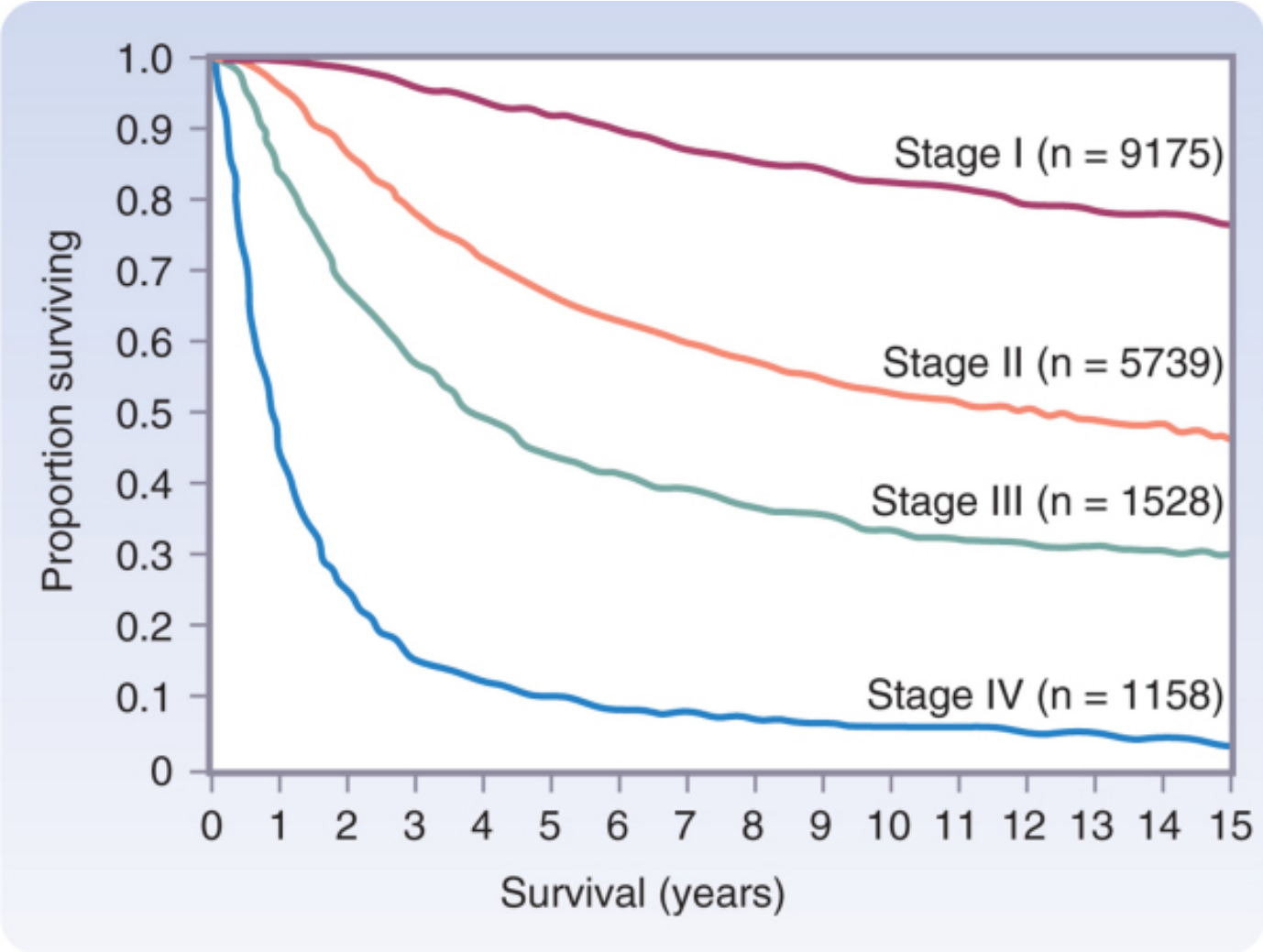
a = skin, subq,  
or distant LN

b = lung

C = any other  
met or met +  
increased LDH

	GROUPING		
PATHOLOGIC STAGE	Tumor	Node	Metastasis
0	Tis	N0	M0
IA	T1a	N0	M0
IB	T1b	N0	M0
	T2a	N0	M0
IIA	T2b	N0	M0
	T3a	N0	M0
IIB	T3b	N0	M0
	T4a	N0	M0
IIC	T4b	N0	M0
IIIA	T1-4a	N1a	M0
	T1-4a	N2a	M0
IIIB	T1-4b	N1a	M0
	T1-4b	N2a	M0
	T1-4a	N1b	M0
	T1-4a	N2b	M0
	T1-4a/b	N2c	M0
IIIC	T1-4b	N1b	M0
	T1-4b	N2b	M0
	Any T	N3	M0
IV	Any T	Any N	M1

# Survival by Stage in Melanoma



# Effect of Ulceration on Survival

STAGE	TUMOR ULCERATION	T STAGE	APPROXIMATE 10-YEAR SURVIVAL (%)
IA	No	T1a	90
IB	Yes	T1b	80
	No	T2a	80
IIA	Yes	T2b	65
	No	T3a	65
IIB	Yes	T3b	50
	No	T4a	55
IIC	Yes	T4b	35
IIIA	No	N1a	70
	No	N2a	60
IIIB	Yes	N1a	55
	Yes	N2a	50
	No	N1b	55
	No	N2b	45
IIIC	Yes	N1b	30
	Yes	N2b	25
	Yes or No	N3	30

# Survival by Thickness in Localized Melanoma

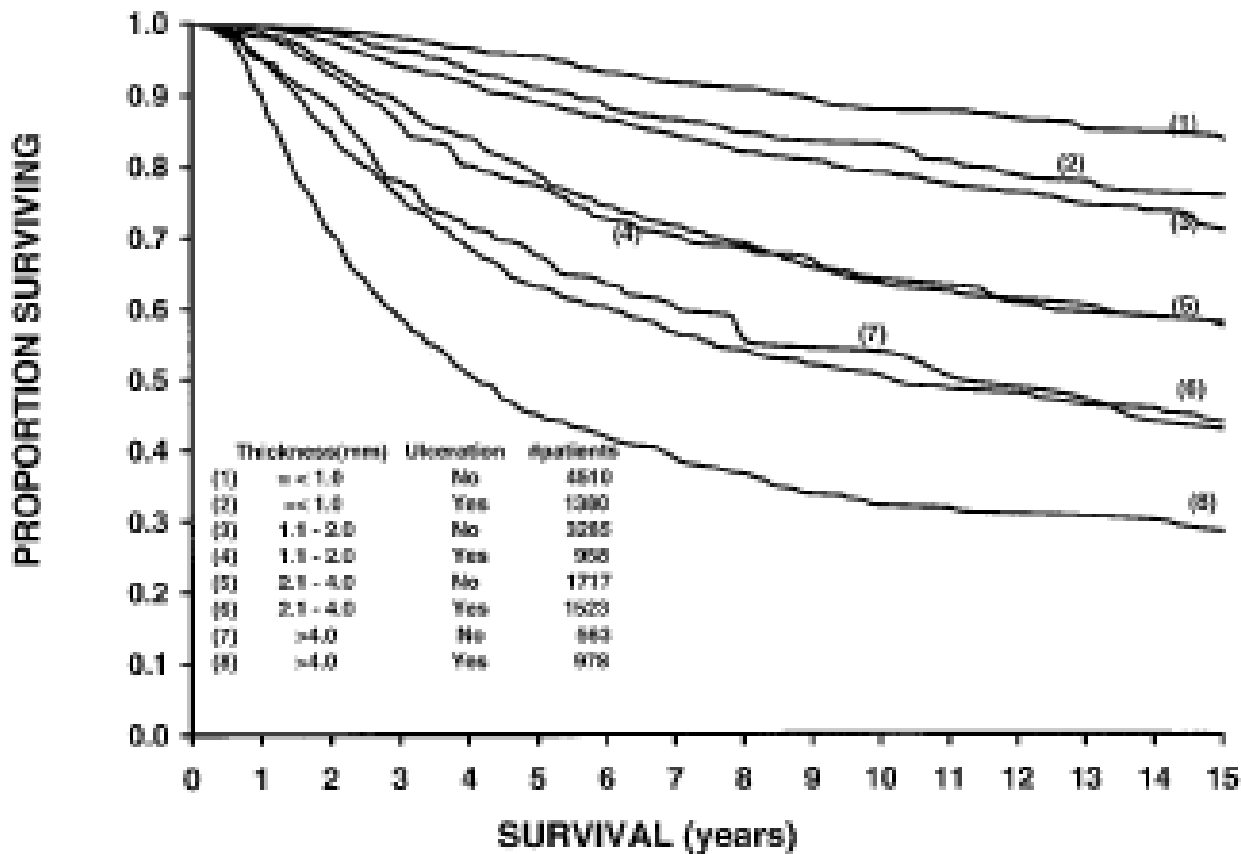


Fig 4. Survival curves of 14,914 patients with localized melanoma stratified by melanoma thickness and presence or absence of ulceration. The correlation of the subgroups used for defining melanoma TNM staging with melanoma-specific survival is significant ( $P < .0001$ ).

# Survival by Number of Positive Nodes in Node Positive Melanoma

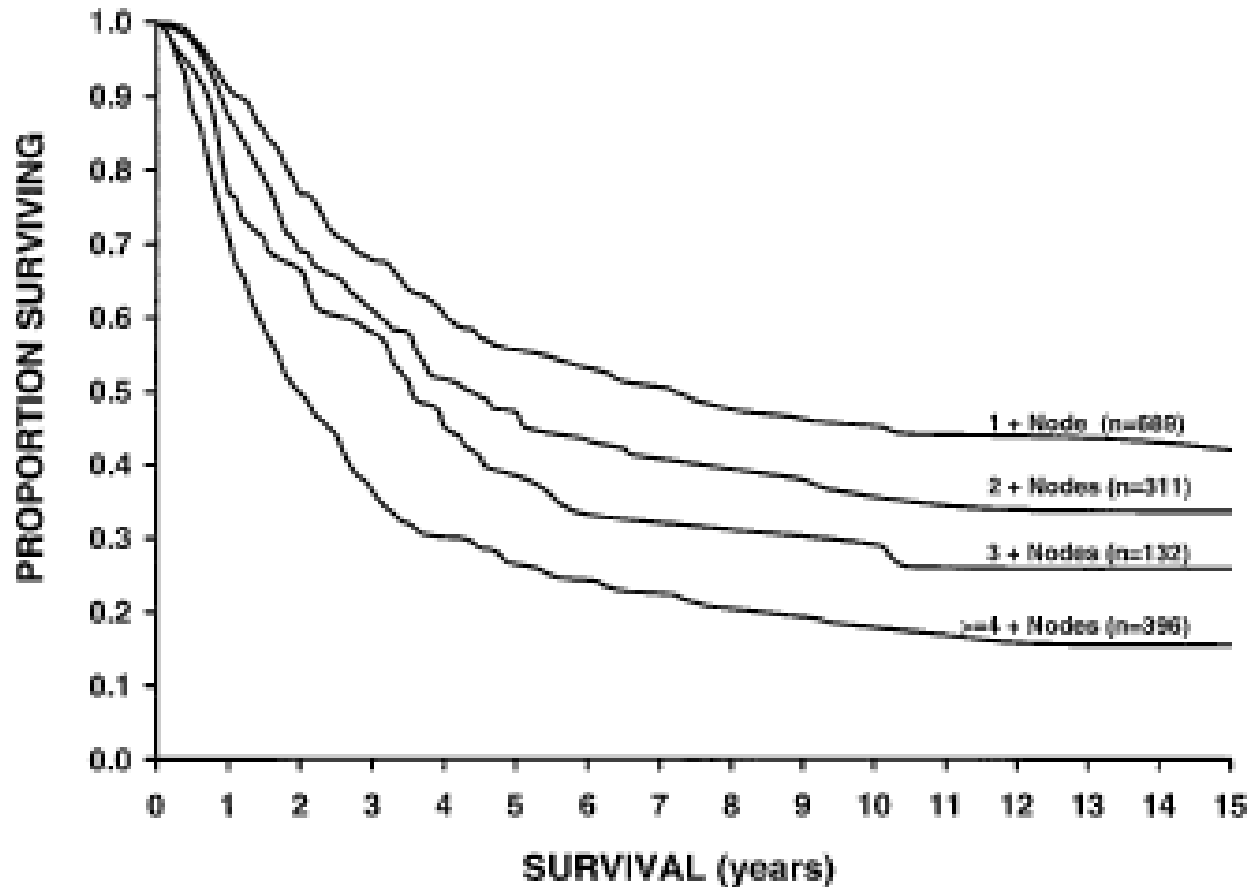


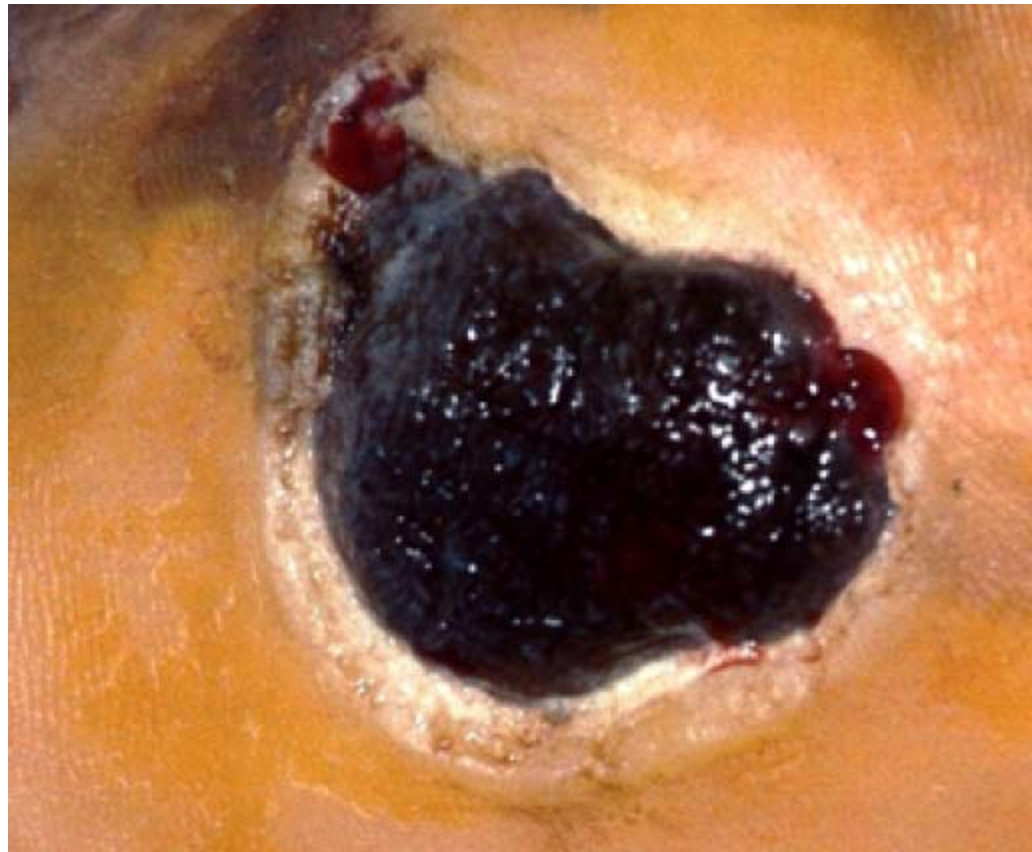Fig 5. Survival curves of 1,528 melanoma patients with lymph node metastases subgrouped by the actual number of metastatic nodes. The correlation is significant ( $P < .0001$ ).

Category 14 Item 19

A 62-year-old man presents with the lesion on his left heel, as shown. It has been present for “many years,” but recently has become ulcerated and weeping. Surprisingly, it is otherwise asymptomatic and produces no discomfort. Histopathologic examination of the lesion demonstrates melanoma. The popliteal and inguinal nodal basins are free of palpable adenopathy. Likewise, there is nothing to suggest metastasis in transit

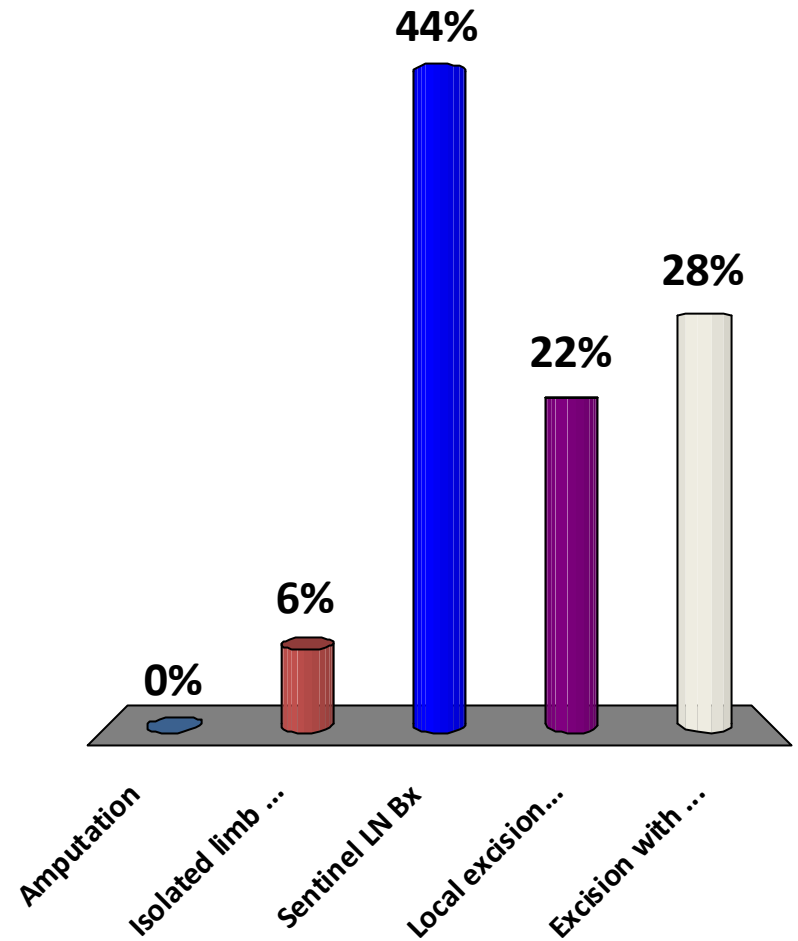
The next step should be

- (A) amputation
- (B) isolated limb perfusion
- (C) sentinel lymph node biopsy
- (D) local excision and skin grafting
- (E) excision with regional lymph node dissection



# The next step should be...

1. Amputation
2. Isolated limb perfusion
3. Sentinel LN Bx
4. Local excision and skin grafting
5. Excision with regional LN dissection



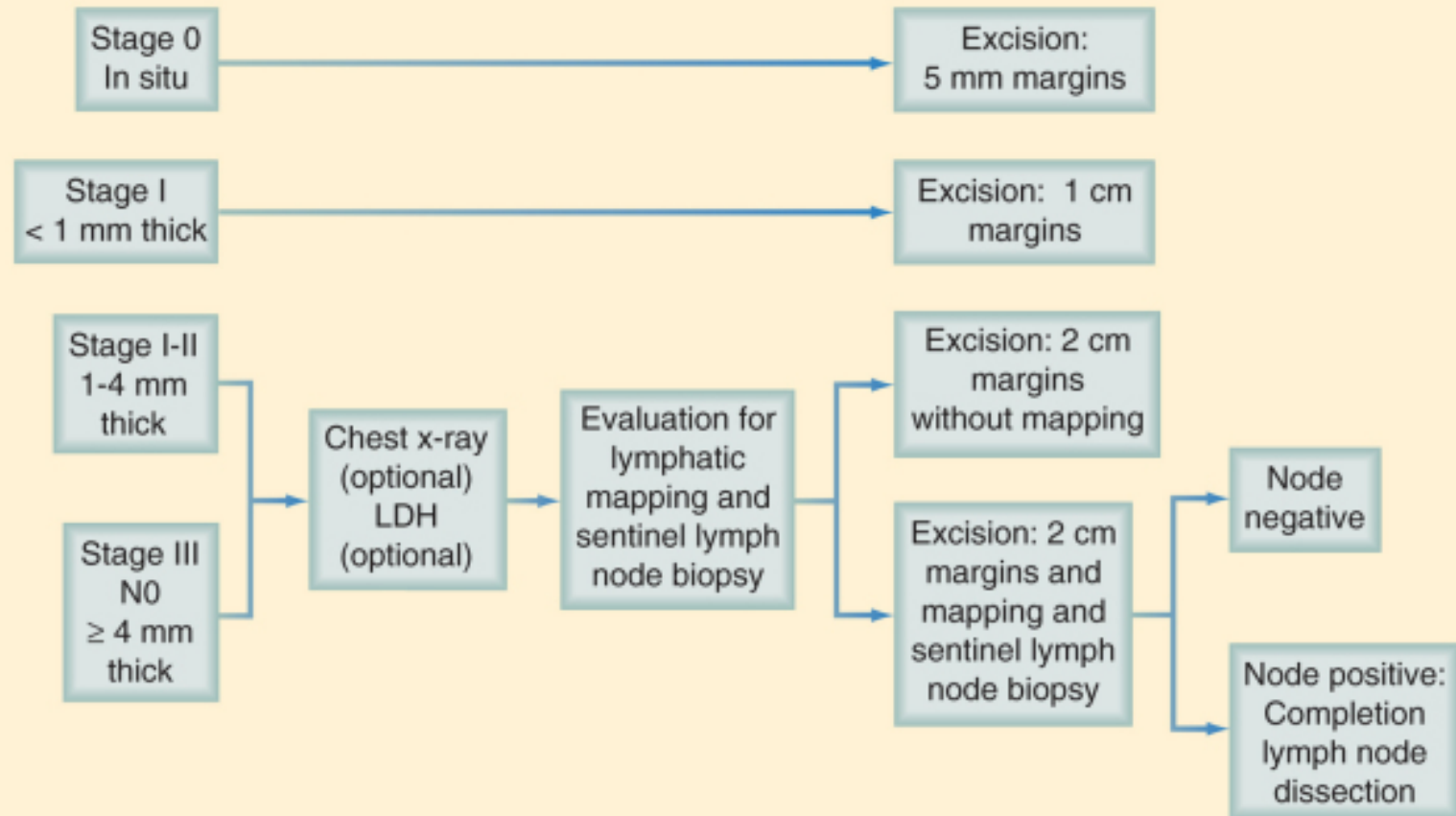
# The SESAP Answer

- Foot melanoma has a worse prognosis than more proximal disease.
- Women and Celtic people are more likely to have this problem.
- Surgical resection is the mainstay of treatment
  - Amputation is relevant for subungual melanoma and in-transit mets developing after excision of the primary lesion
- **Sentinel Lymph Node Biopsy is the first step in evaluating this patient**
  - If positive, no amputation as no chance for cure
  - If positive, local control with excision and wound coverage
- Limb perfusion +/- hyperthermia is for
  - Recurrence
  - Bulky disease



# Management Algorithm

## SURGICAL MANAGEMENT OF PRIMARY CUTANEOUS MELANOMA



See NCCN guidelines at [www.nccn.org](http://www.nccn.org)

Category 14 Item 26

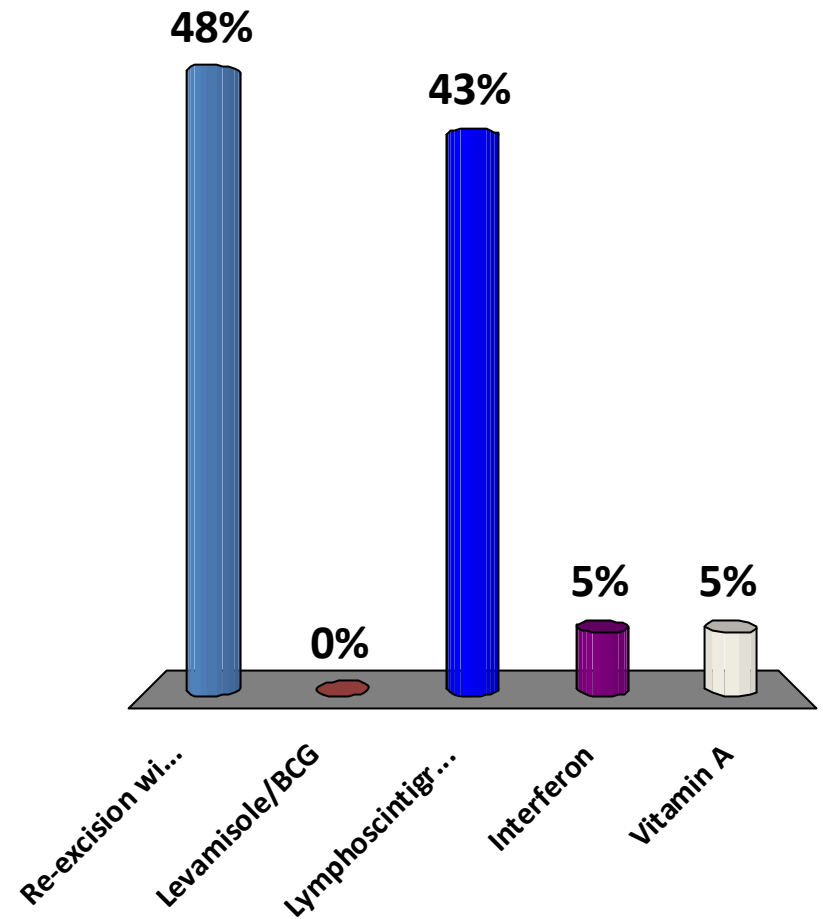
A 55-year-old man presents with a pigmented lesion in the upper midline of his back. Excision reveals a 0.9-mm thick ulcerated melanoma with 1-cm clear margins. Physical examination is otherwise unremarkable.

The next step in management should include

- (A) re-excision with 2-cm margins
- (B) levamisole and BCG
- (C) lymphoscintigraphy
- (D) adjuvant interferon therapy
- (E) vitamin A administration

# The next step should be...

1. Re-excision with 2 cm margins
2. Levamisole/BCG
3. Lymphoscintigraphy
4. Interferon
5. Vitamin A



# The SESAP Answer

- This lesion is less than 1 mm thick but **ULCERATED** (Stage T1b)
- Ulceration increases risk of LN mets → **SLN Bx**
- This lesion is on the trunk → 30% risk of non-anatomic lymphatic drainage, so **LYMPHISCINTIGRAPHY** is necessary
- Other options
  - 1 cm margin is adequate for a T1 lesion
  - Interferon therapy **ONLY IF NODE POSITIVE**
  - Vitamin A could improve your eyesight to allow you to detect recurrence earlier but is otherwise useless



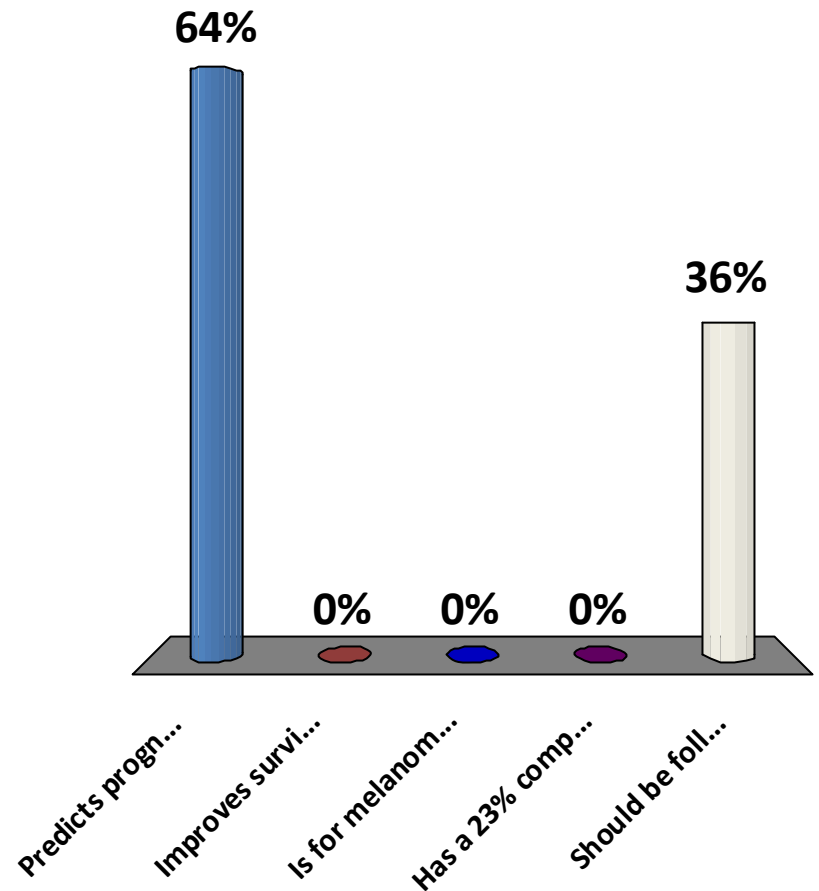
Category 15 Item 11

Sentinel lymph node biopsy for melanoma

- (A) predicts prognosis
- (B) improves survival
- (C) is indicated for melanomas < 1 mm thick
- (D) is associated with a complication rate of 23%
- (E) should be followed by completion lymph node dissection in patients who have positive results

# SLN Bx for melanoma

1. Predicts prognosis
2. Improves survival
3. Is for melanomas < 1mm thick
4. Has a 23% complication rate
5. Should be followed with LN dissection if positive



# The SESAP Answer

Tumor Thickness	Probability of Positive Node
< 0.8mm	1%
$0.8\text{mm} \leq x < 1.5\text{mm}$	8%
$1.5\text{mm} \leq x < 4.0\text{mm}$	23%
$\geq 4.0\text{mm}$	36%

- SLN Bx is a powerful **PROGNOSTIC** tool.
- Complication rates:
  - 4% SLN Bx
  - 23 % SLN Bx + completion LN dissection
- Perform in thin (< 1mm) melanomas if ulcerated or Clark level IV-V invasion
- Need more study to determine benefit of completion LN dissection if a positive SLN Bx

# Sentinel Lymph Node Bx

- By using isotope lymphatic mapping, an intraop gamma probe, and intraop injection of blue dye, the SLN can be identified
  - in more than 95% of cases in the groin and axilla
  - in 85% of cases in the head/neck region
- Resect all nodes that are
  - BLUE
  - HOT (>10% of max gamma count)

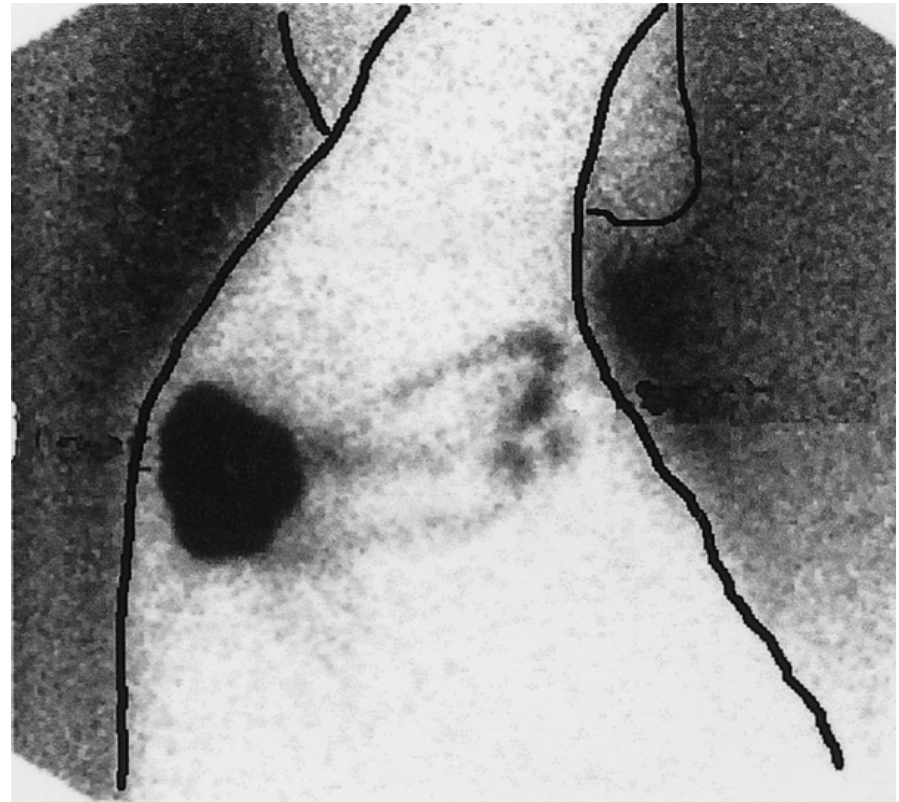
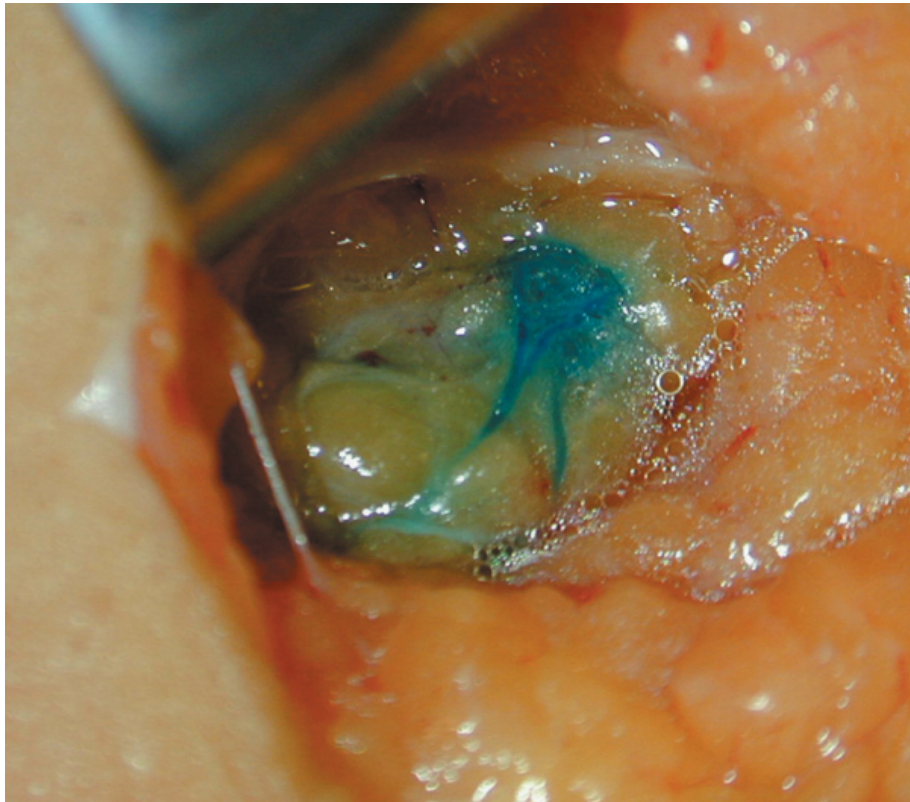
# Sentinel Lymph Node Bx—Indications

- All melanomas greater than 1mm thickness
- If clinically positive nodes without distant mets → LYMPH NODE DISSECTION
  
- If POSITIVE SLN Bx → LYMPH NODE DISSECTION although benefit not completely clear

# Sentinel Lymph Node Bx—How to Do It

- Intradermally inject Tc99 sulfur colloid into perimeter of biopsy scar approx 90-180 min preop
- Perform lymphoscintigraphy and label areas of uptake
- Intradermally inject isosulfan blue into perimeter of biopsy scar in OR
- Use gamma probe to localize “hottest” area
- Make 2-4 cm incision
- Dissect bluntly until you find a blue lymphatic and follow to a blue node
- Use gamma probe and identify/resect all blue or hot nodes

# Sentinel Lymph Node Mapping



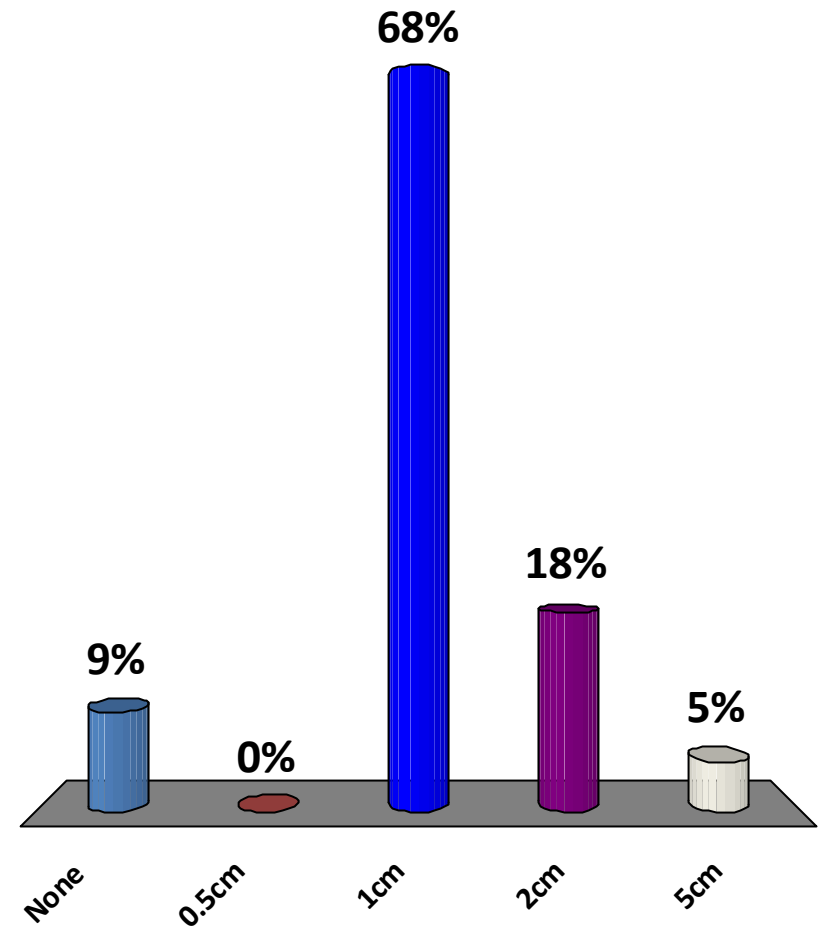
## Category 14 Item 4

Initial biopsy of a 0.7-mm thick mole on the thigh reveals melanoma with positive margins. Which of the following is the recommended margin for re-excision?

- (A) No re-excision is necessary if margins are negative
- (B) 0.5 cm
- (C) 1.0 cm
- (D) 2.0 cm
- (E) 5.0 cm

# Margin for re-excision?

1. None
2. 0.5cm
3. 1cm
4. 2cm
5. 5cm



# The First Cut is the Deepest, but the Second Cut is Wider...

<b>TUMOR THICKNESS (mm)</b>	<b>MARGIN RADIUS (cm)</b>
<b>In situ</b>	<b>0.5</b>
<b>&lt;1.0</b>	<b>1.0</b>
<b>1-2</b>	<b>1.0-2.0</b>
<b>&gt;2.0</b>	<b>≥2.0</b>

# Take Home Points

- Depth of invasion correlates with likelihood of metastasis, width of primary excision, and survival
- Sentinel LN Bx is highly effective for patients with  $>1$ mm thick melanomas and no clinically apparent metastases or thin melanomas with ulcers or Clark IV or V
- If you know melanoma, you can get a good score on the ABSITE