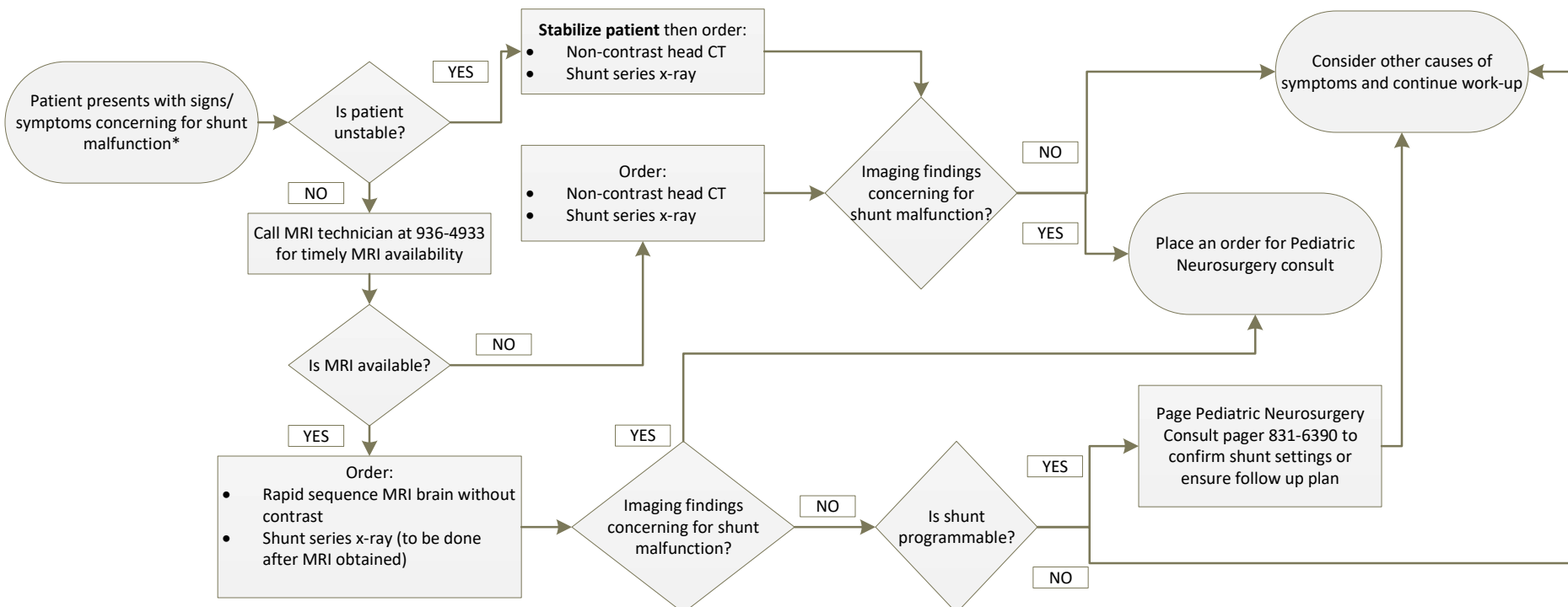


Pediatric Ventricular Shunt Malfunction Evaluation

Clinical Practice Guideline



*Signs and Symptoms Concerning for Shunt Malfunction:

- Persistent headaches unrelieved by over the counter medications
- Persistent nausea/vomiting
- Bulging fontanelle
- Rapid increase in head circumference
- Increased irritability or lethargy
- Altered mental status
- Acute decline in vision or papilledema on exam
- Stridor (spina bifida patients)

Programmable vs. Non-Programmable Shunt:

- Commonly described in last clinic note
- Described in latest shunt operative note
- Programmable shunt settings need checked within 48 hours

Types of Shunts:

- Ventriculo-peritoneal (most common)
- Ventriculo-atrial
- Ventriculo-pleural
- Ventriculo-subgaleal (infants only, temporary shunt)

If imaging is stable but there is concern about patient's symptoms/exam place order for Pediatric Neurosurgery Consult

References:

- Iskandar, B. J., Sansone, J. M., Medow, J., & Rowley, H. A. (2004). The use of quick-brain magnetic resonance imaging in the evaluation of shunt-treated hydrocephalus, *Journal of Neurosurgery: Pediatrics*, 101(2), 147-151. Retrieved Mar 7, 2019, from <https://thejns.org/view/journals/j-neurosurg-pediatr/101/2/article-p147.xml>
- Kestle, J. W.MD, & Riva-Cambrin, J.MD, MSc. (2019). Prospective multicenter studies in pediatric hydrocephalus, *Journal of Neurosurgery: Pediatrics PED*, 23(2), 135-141. Retrieved Mar 7, 2019, from <https://thejns.org/view/journals/j-neurosurg-pediatr/23/2/article-p135.xml>
- Naftel, R. P., Tubergen, E., Shannon, C. N., Gran, K. A., Vance, E., Oakes, W., Blount, J. P., & Wellons, J. C. (2012). Parental recognition of shunt failure: a prospective single-institution study, *Journal of Neurosurgery: Pediatrics PED*, 9(4), 363-371. Retrieved Mar 7, 2019, from <https://thejns.org/view/journals/j-neurosurg-pediatr/9/4/article-p363.xml>
- Patel, D. M., Tubbs, R., Pate, G., Johnston, J. M., & Blount, J. P. (2014). Fast-sequence MRI studies for surveillance imaging in pediatric hydrocephalus, *Journal of Neurosurgery: Pediatrics PED*, 13(4), 440-447. Retrieved Mar 7, 2019, from <https://thejns.org/view/journals/j-neurosurg-pediatr/13/4/article-p440.xml>
- Tubbs, R., Wellons, J. C., Blount, J. P., & Oakes, W. (2005). Transient ventriculoperitoneal shunt dysfunction in children with myelodysplasia and urinary bladder infection, *Journal of Neurosurgery: Pediatrics*, 102(2), 221-223. Retrieved Mar 7, 2019, from <https://thejns.org/view/journals/j-neurosurg/102/2/article-p221.xml>