



VANDERBILT UNIVERSITY  
MEDICAL CENTER

# Vanderbilt Fellows Vitreoretinal Case Conference



**Vanderbilt Eye Institute**



# Chief Complaint

- 48 y/o Caucasian woman referred for possible retinal dystrophy
- Reporting losing vision over the last 1-2 years
- Gradual, painless
- Worse specifically at night



# Past Medical History

- Rheumatoid Arthritis
- Fibromyalgia
- Gastric Bypass (2003)
  
- Meds
  - Remote use of hydroxychloroquine



# Past Ocular History

- Astigmatism as a child
- DES s/p punctal plugs
- PCIOL OU
- No family history of any eye conditions or blindness



# Social History

- denies EtoH
- +Tobacco

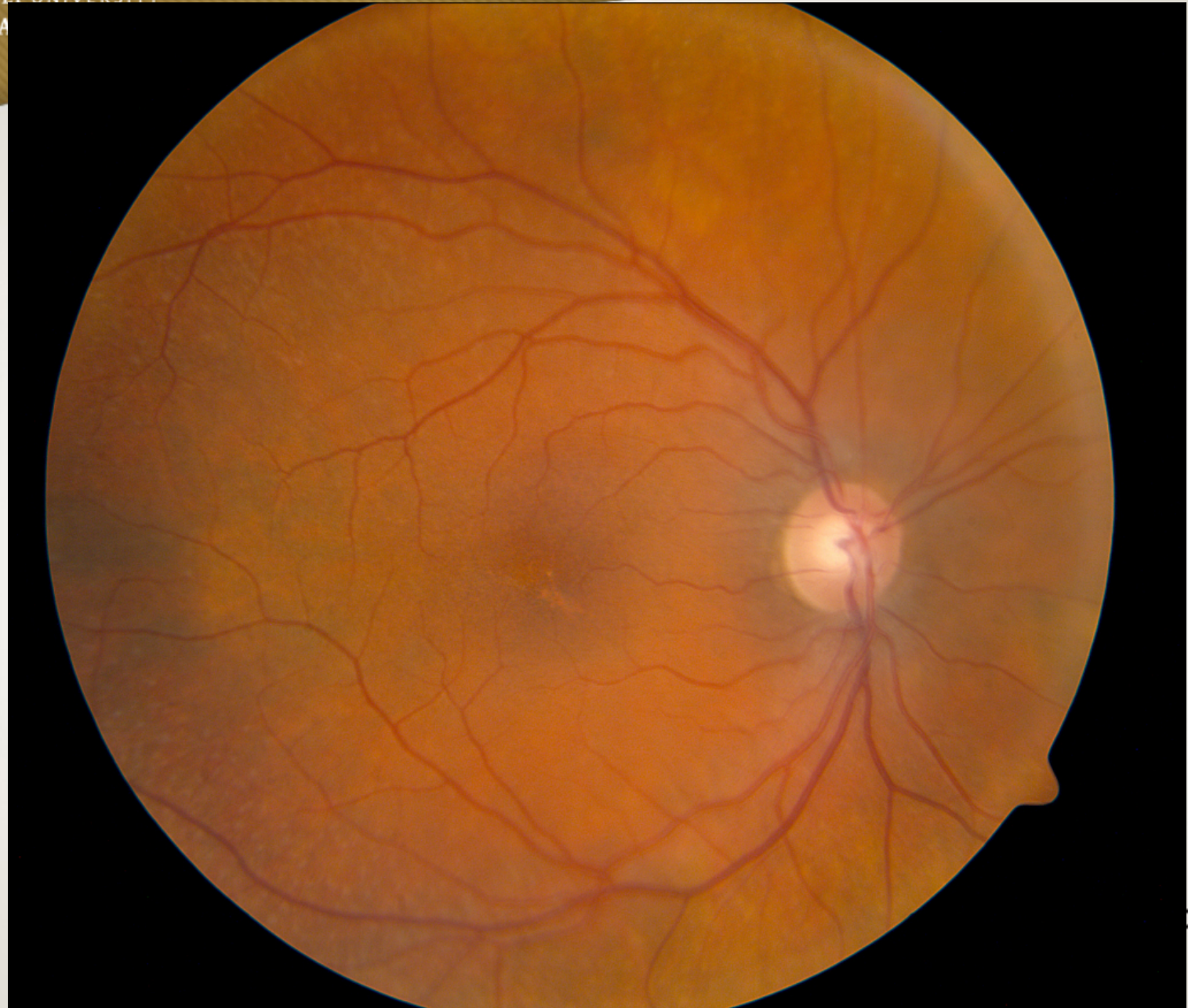


# Exam

	OD	OS
Va	20/30	20/40
IOP	12	12
CVF	FULL	FULL
PUPIL	R/R	R/R, NO APD
L/L/L	Wnl	Wnl
C/S	White	White
K	SPK	SPK
A/C	d/q	d/q
I/P	r/r	r/r
L	PCIOL	PCIOL
Avit	Quiet	Quiet



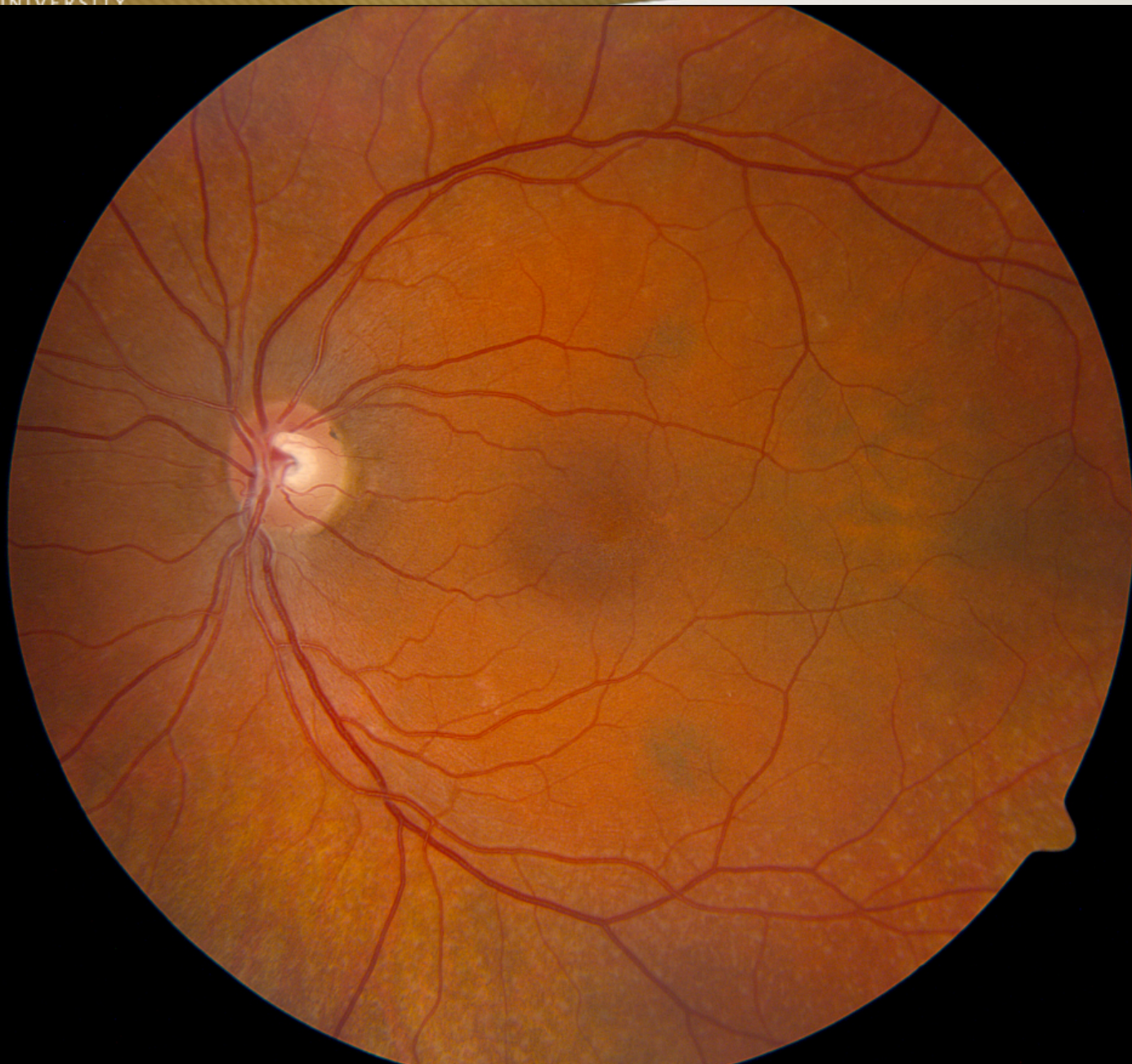VANDERBILT UNIVERSITY  
MEDICAL CENTER



ute



VANDERBILT UNIVERSITY  
MEDICAL CENTER

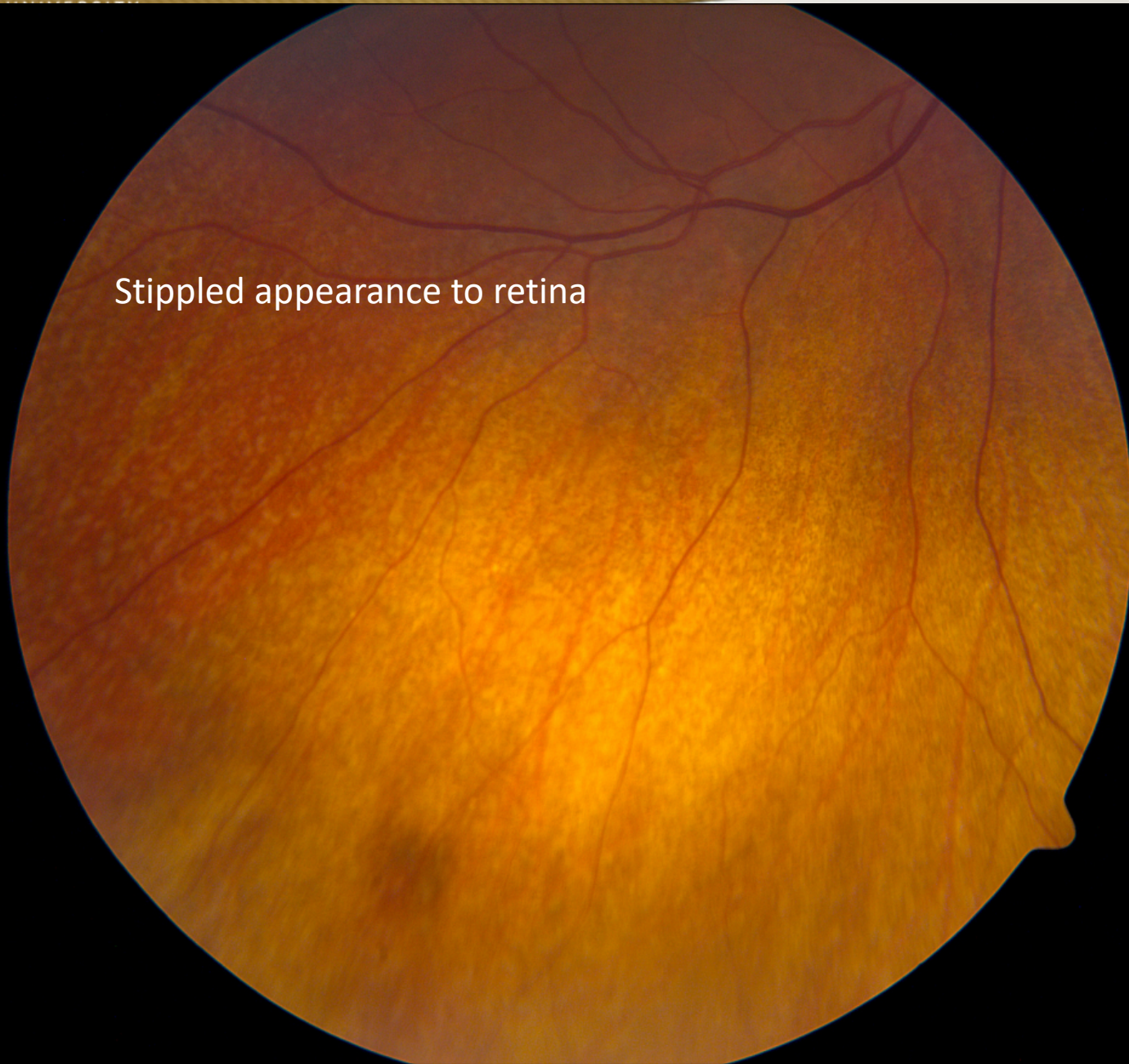


ute



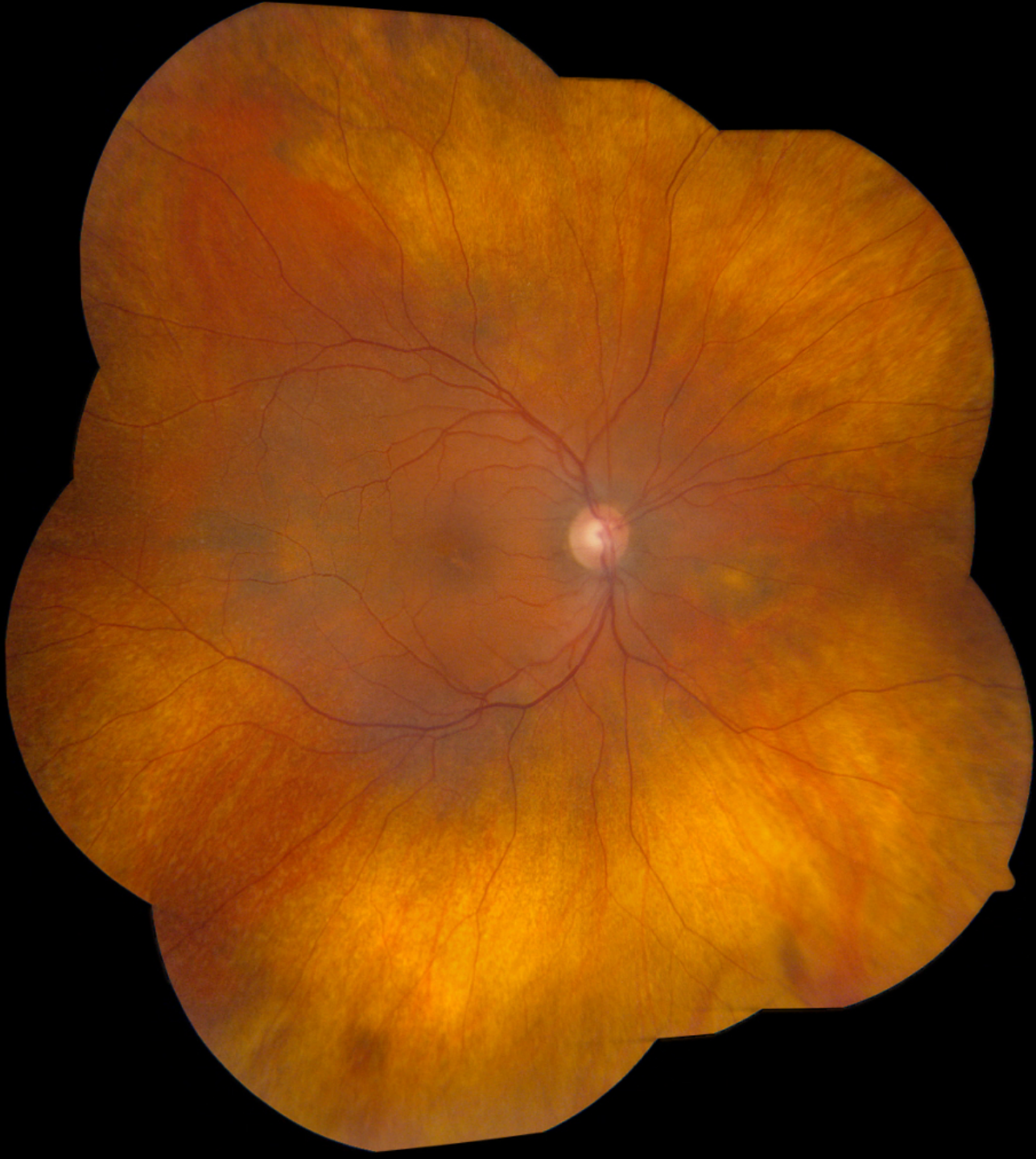

Stippled appearance to retina

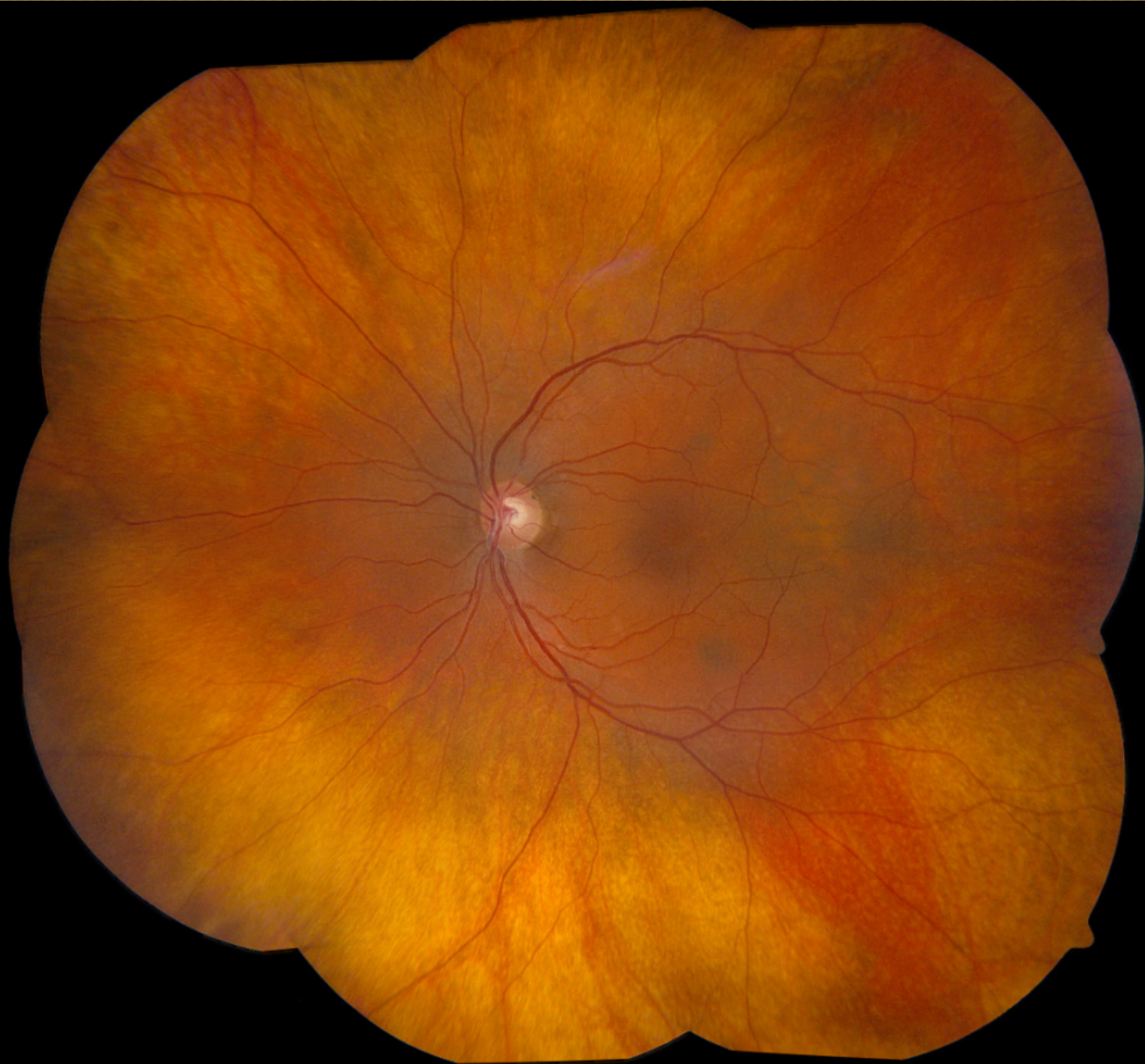



VANDERBILT UN  
MEDICAL C

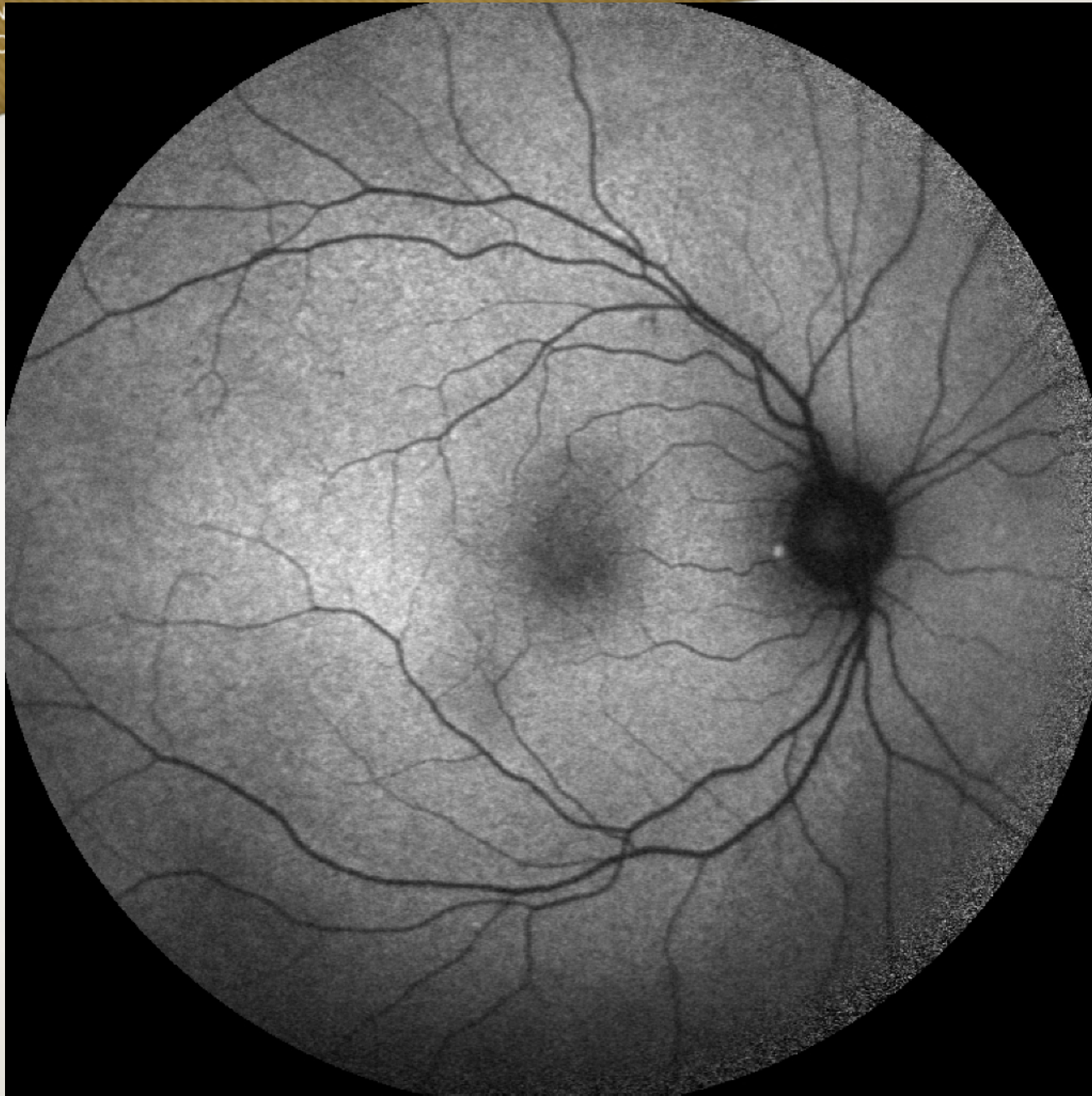


stitute





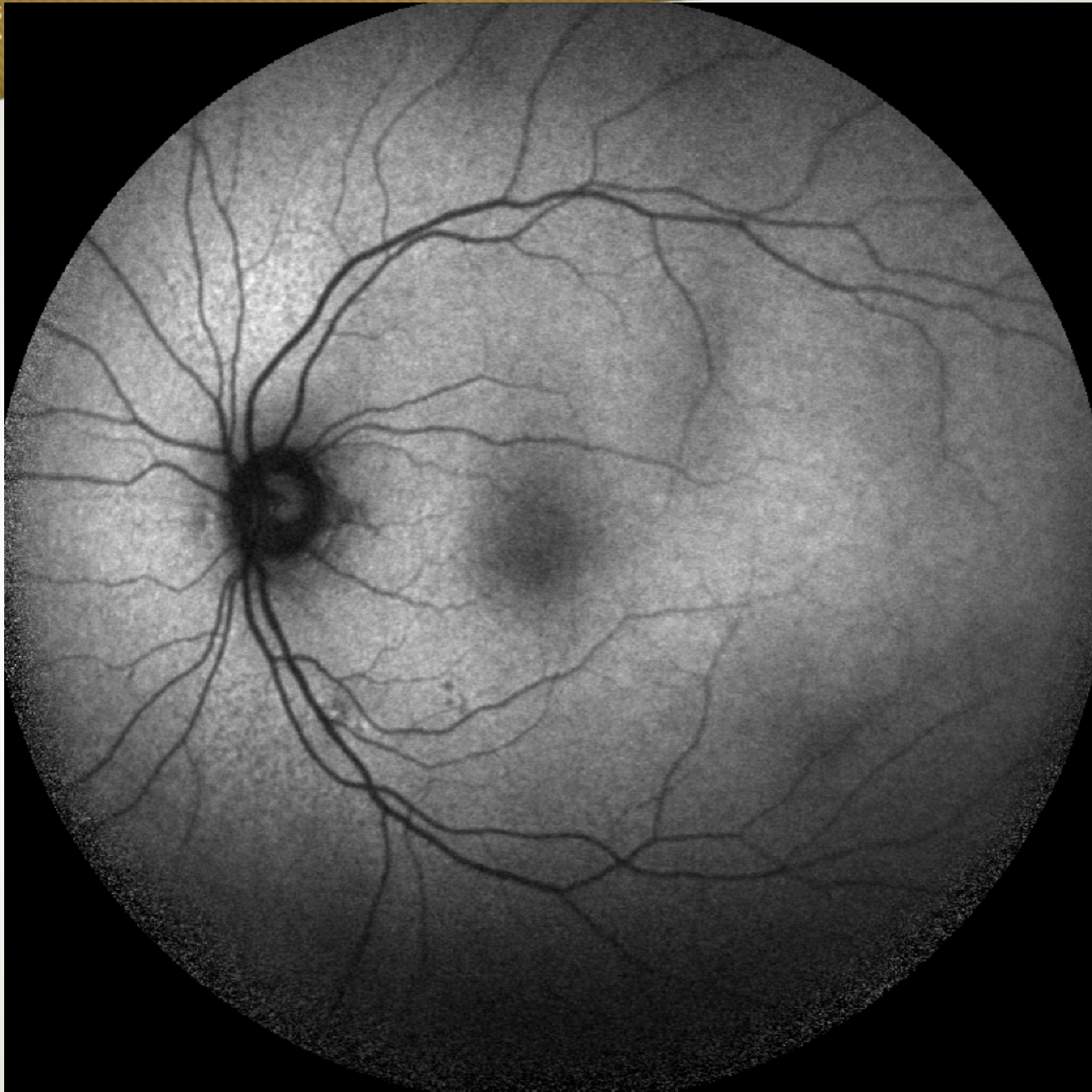
VANDERBILT UN  
MEDICAL C



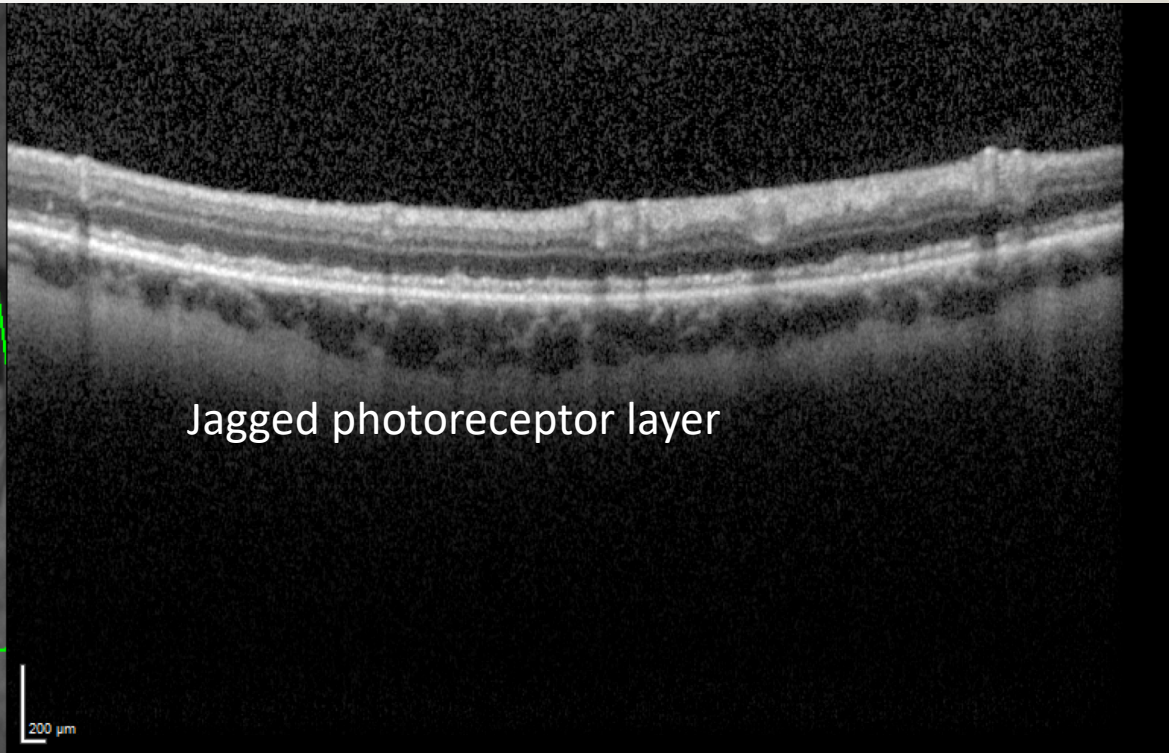
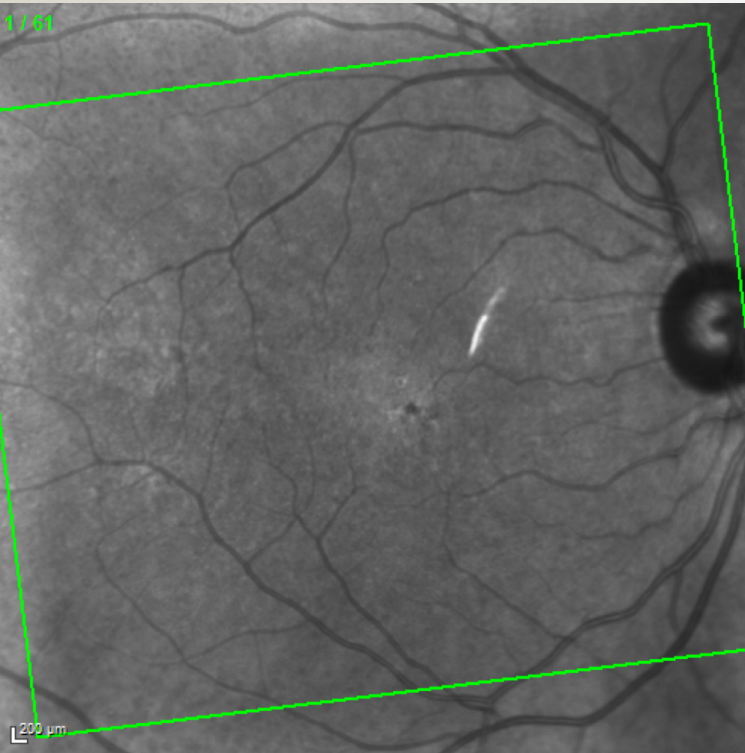
Institute



VANDERBILT UNIVERSITY  
MEDICAL CENTER

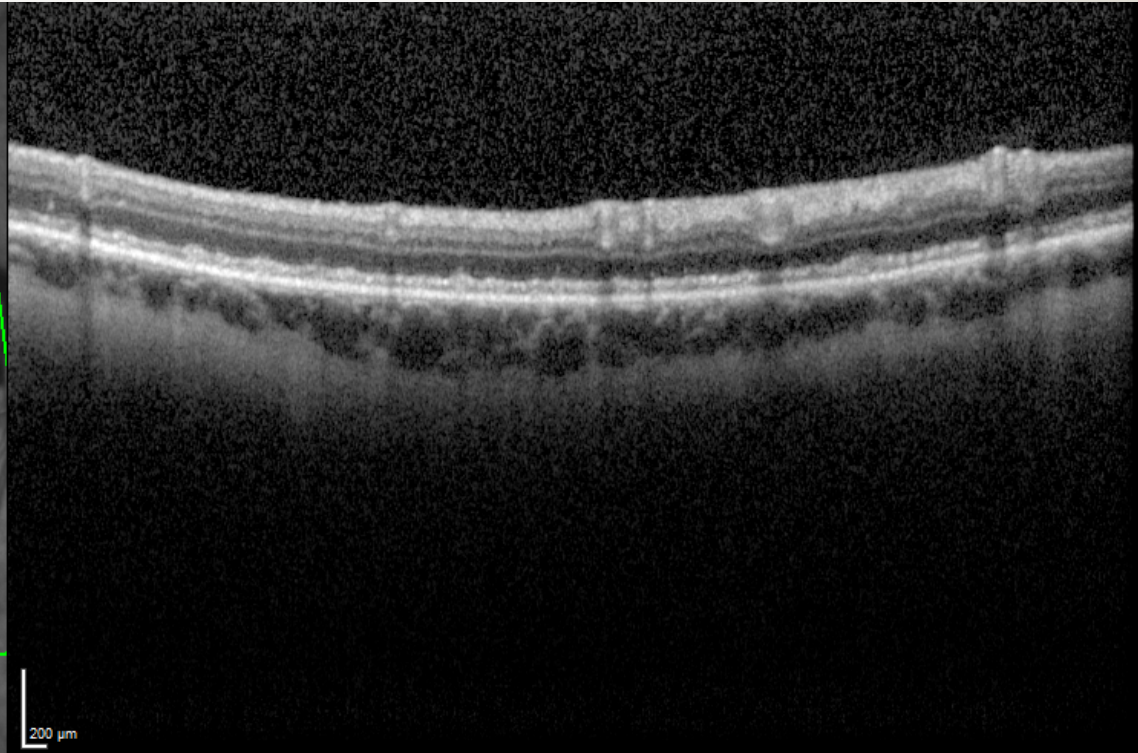
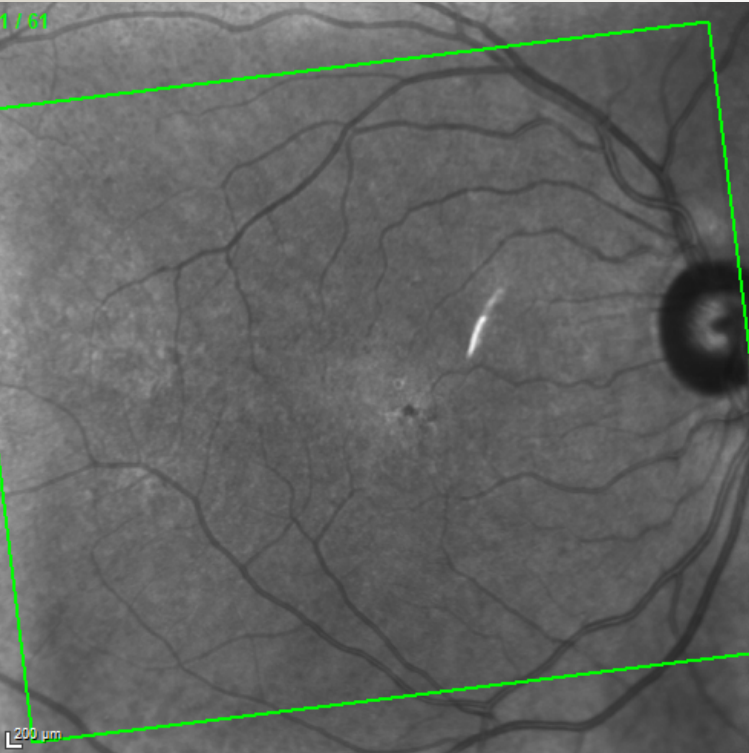


Institute





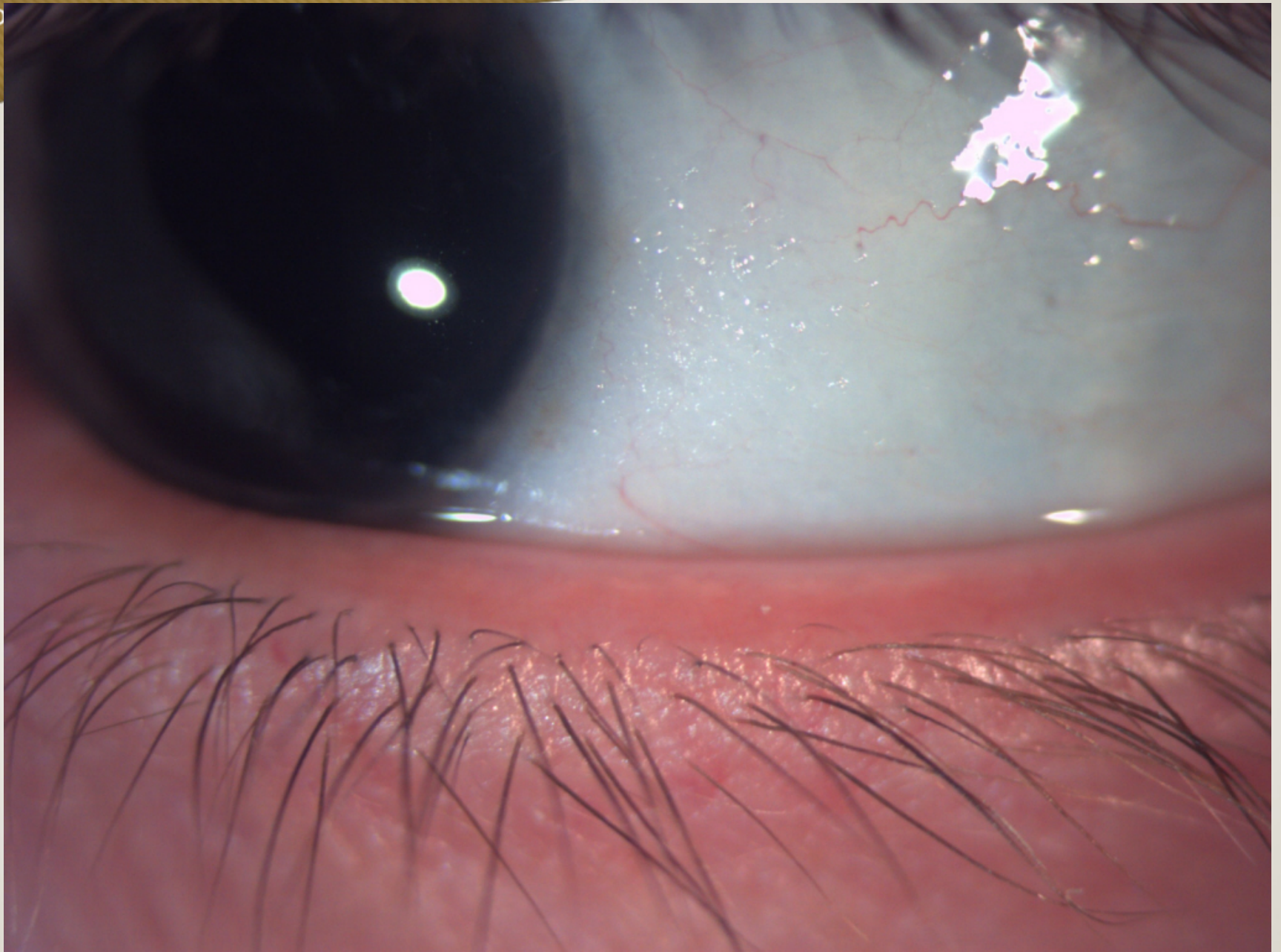VANDERBILT UNIVERSITY  
MEDICAL CENTER



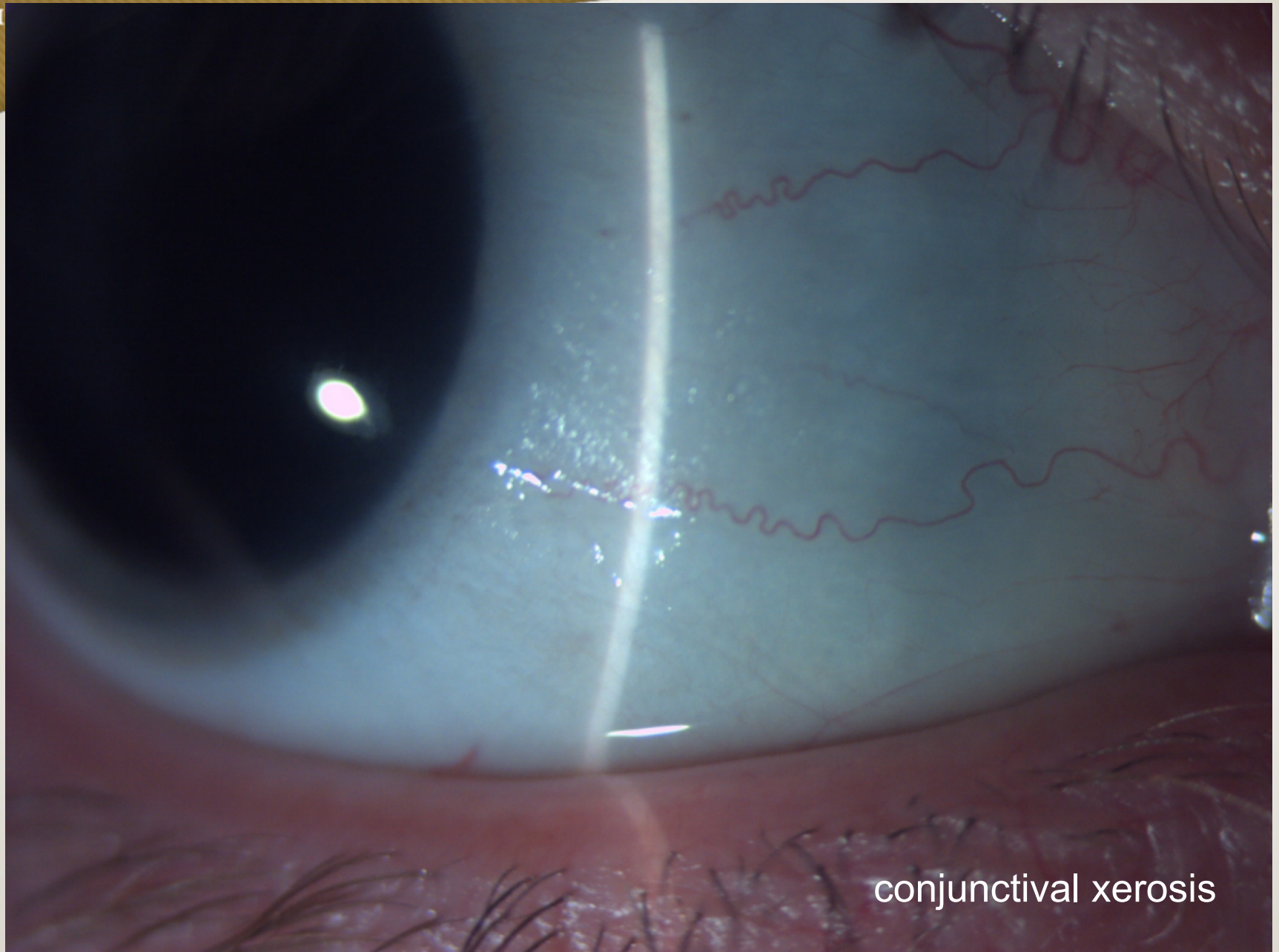
Vanderbilt Eye Institute



VANDERBILT UNIVERSITY  
MED





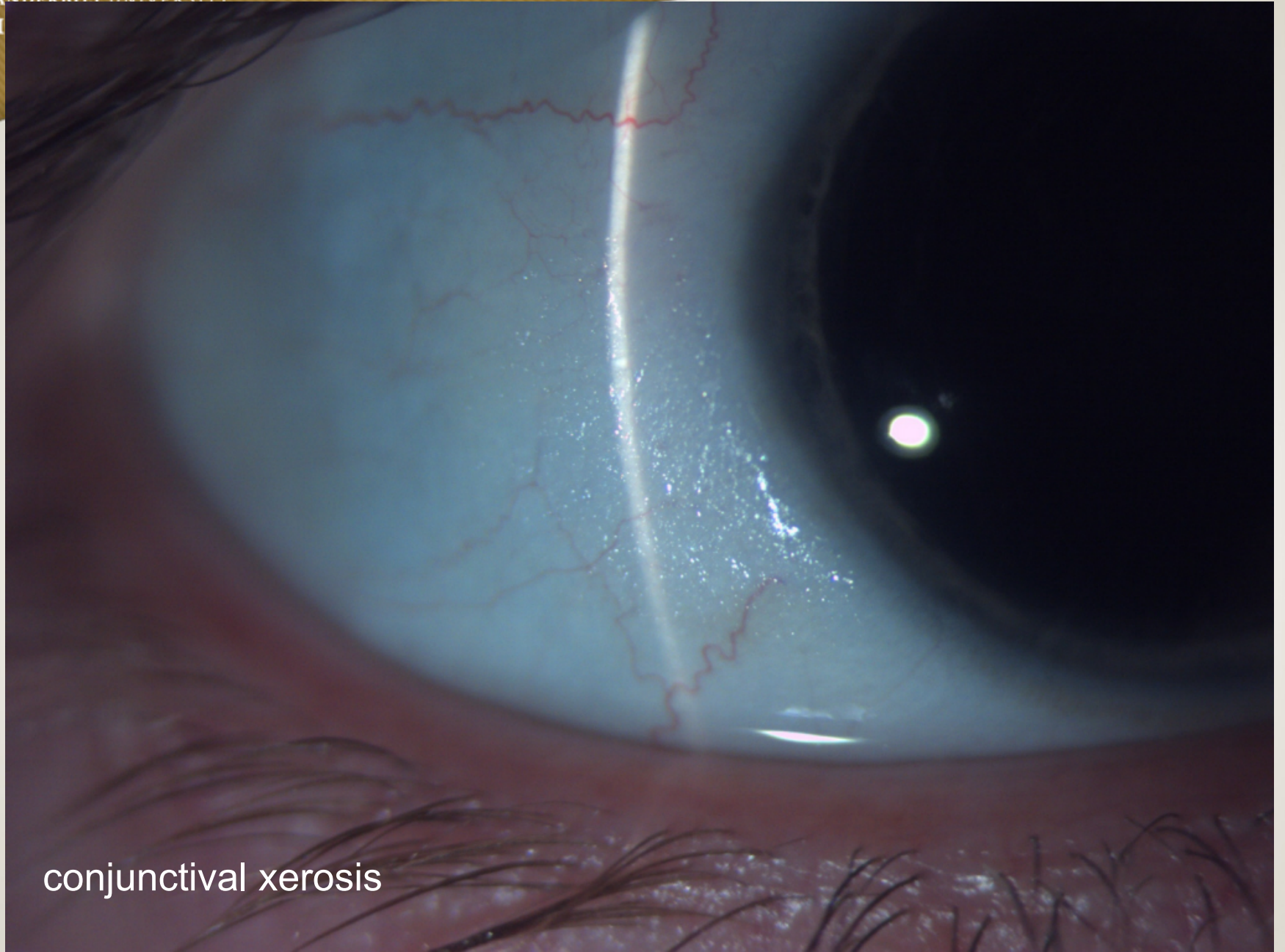


conjunctival xerosis



VANDERBILT UNIVERSITY

M



conjunctival xerosis



# Workup

**ViARet:  $<0.06^*$**



# Course

- Diagnosis: Vitamin A Deficiency (history of gastric bypass)
- Started on 10,000 IU Vitamin A