



VANDERBILT UNIVERSITY
MEDICAL CENTER

Vanderbilt Fellows Vitreoretinal Case Conference



Vanderbilt Eye Institute



Chief Complaint

- 15 y/o male sudden vision loss OD x 5 days



Past Medical History

- No significant medical hx
- No past ocular hx
- No significant family hx



Social History

- Denies tobacco/alcohol/illicit drug use
- No medications



Exam

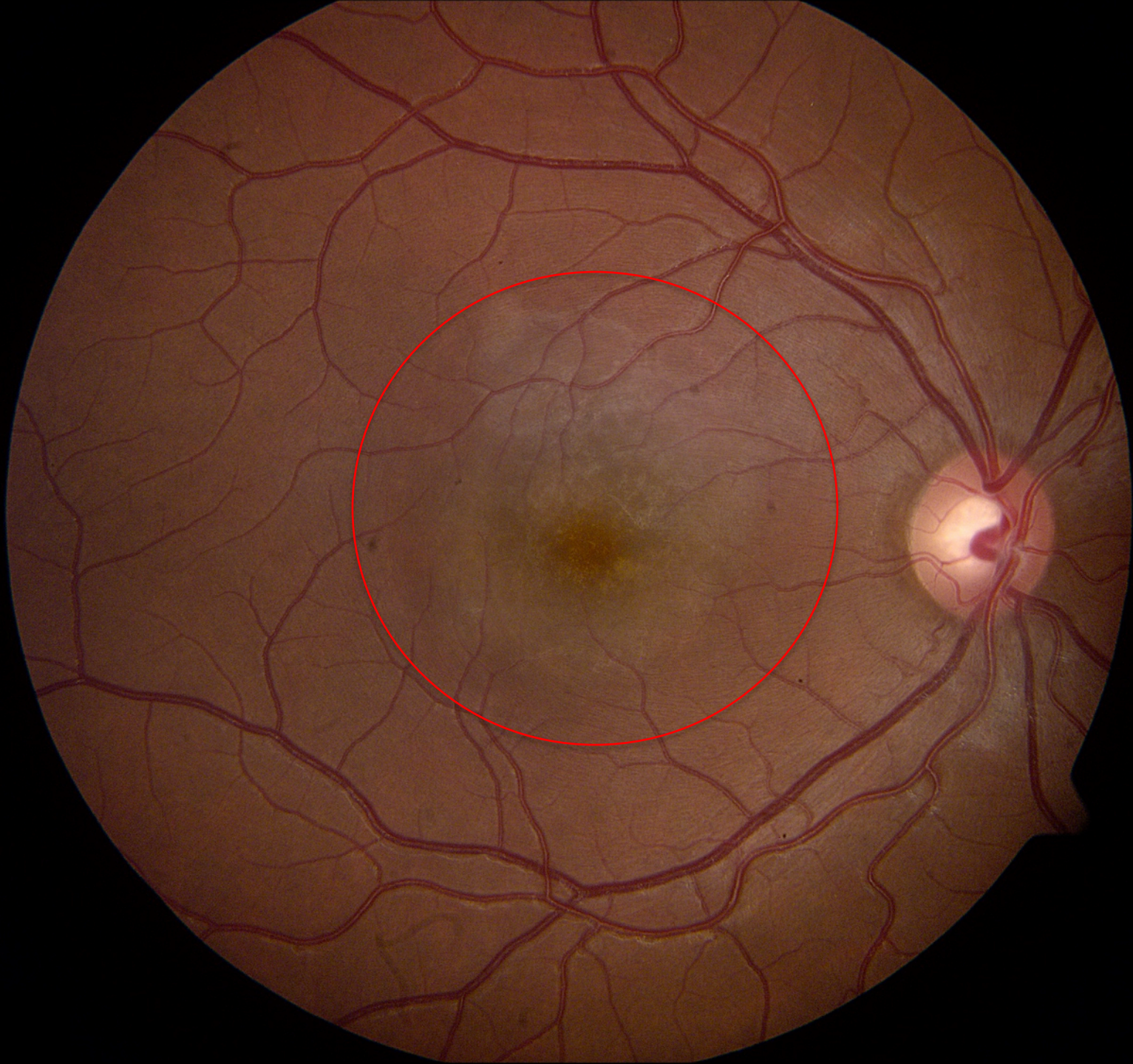
| | OD | OS |
|----------|---------------|-------|
| Vision | CF | 20/20 |
| Pupils | r/r | r/r |
| Motility | Full Ortho | Full |
| IOP | 13 | 13 |
| External | Wnl | Wnl |
| CVF | FCF | FCF |

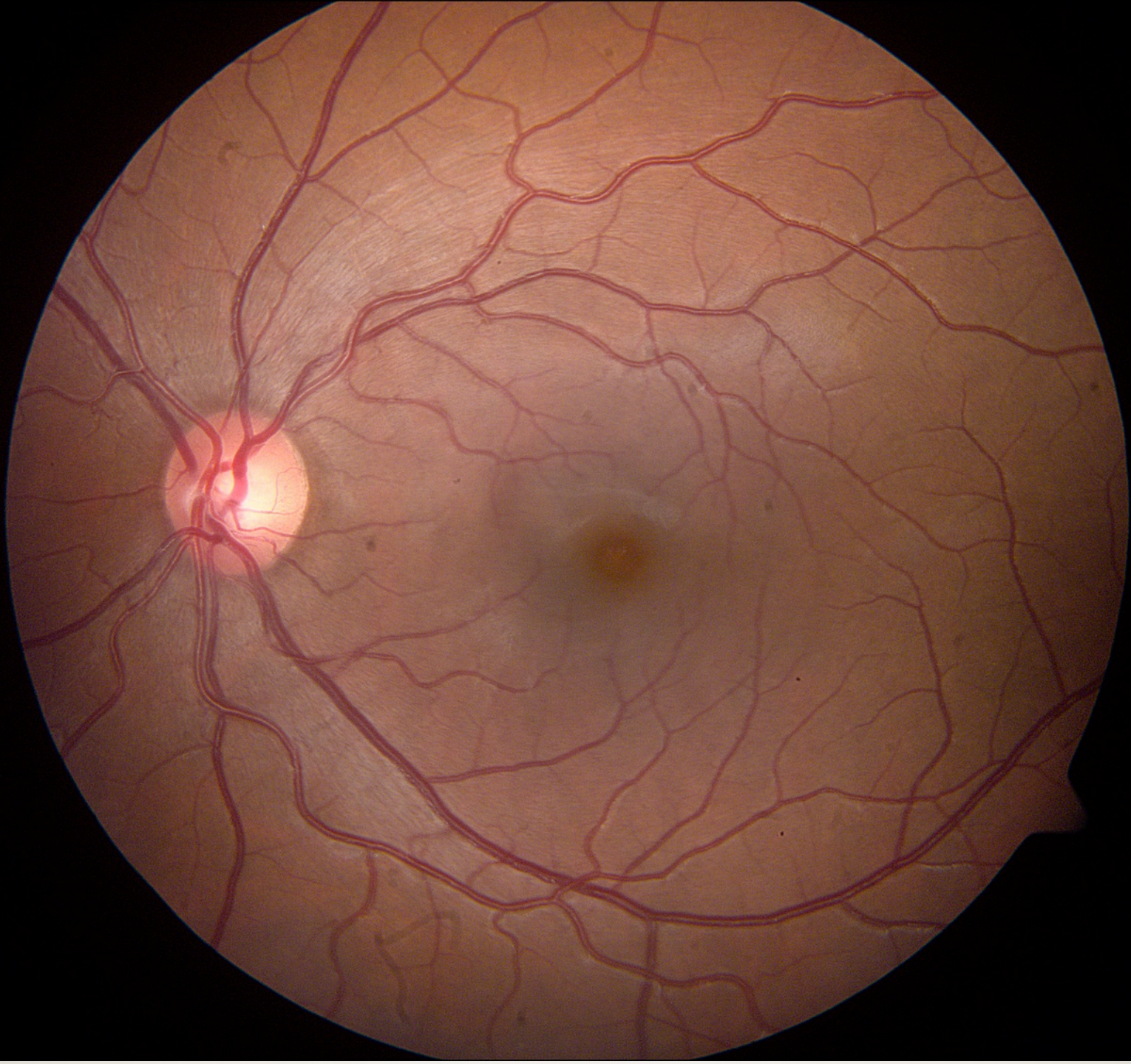


Anterior Segment

| | OD | OS |
|-------|----------------|-------|
| L/L/L | Wnl | Wnl |
| C/S | w/q | w/q |
| K | Clear | Clear |
| A/C | d/q No cell | d/q |
| I/P | r/r | r/r |
| L | Clear | Clear |
| Avit | clear | clear |

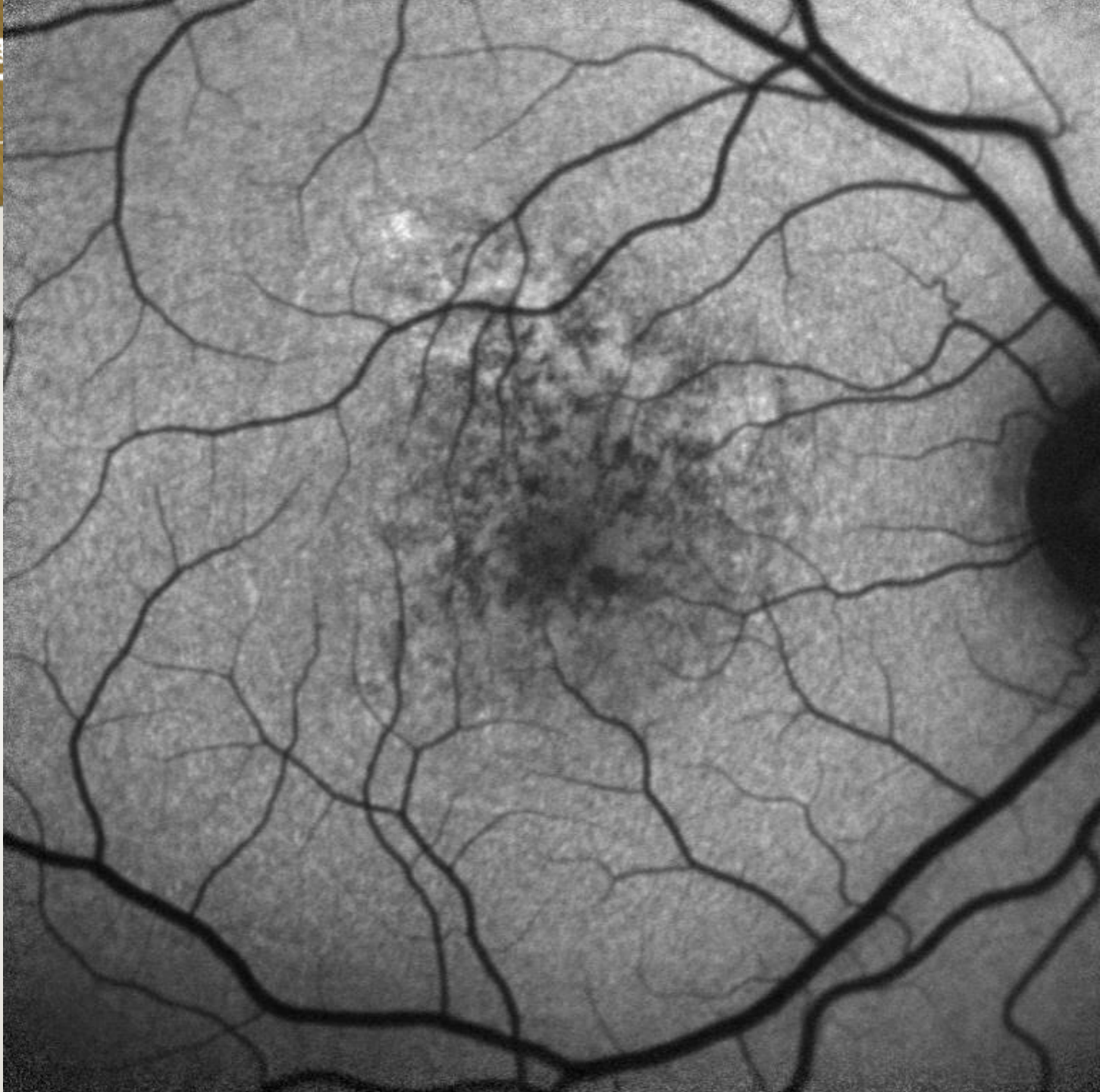
VANI
ME







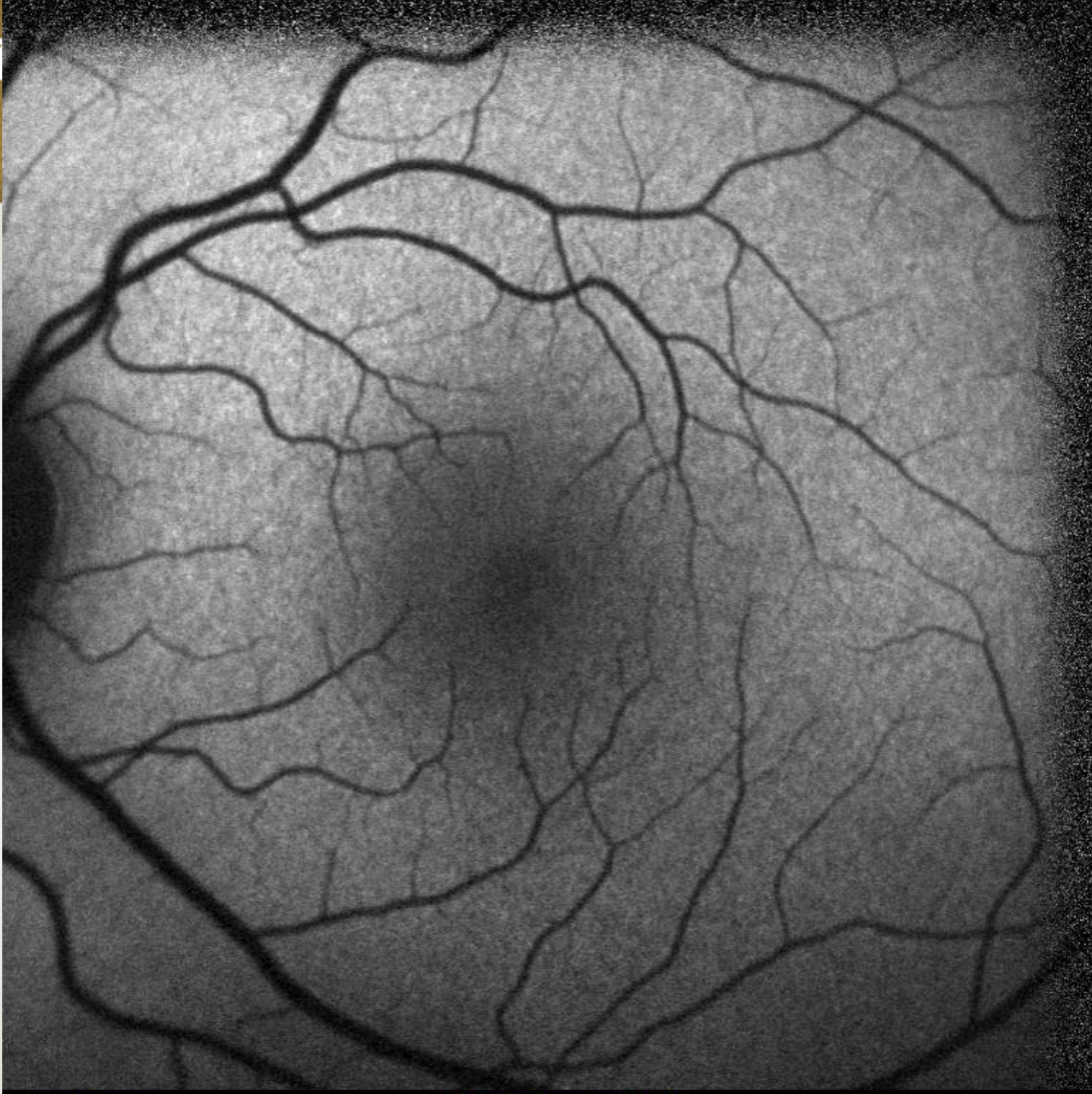VANDERBILT
MEDICAL



itute

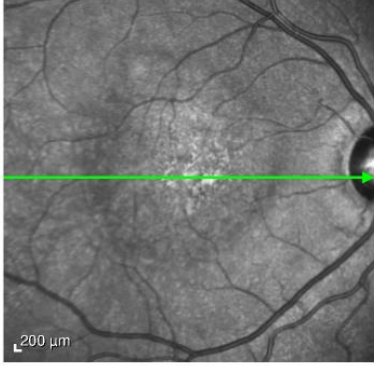


VANDERBILT U
MEDICAL

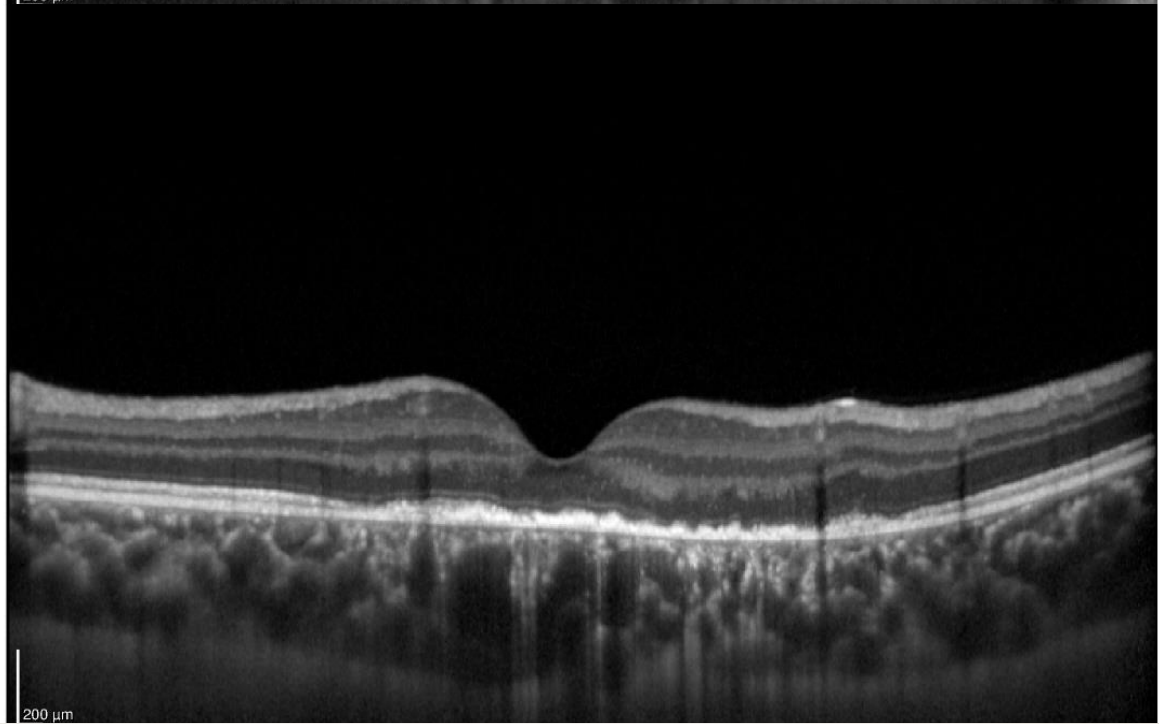
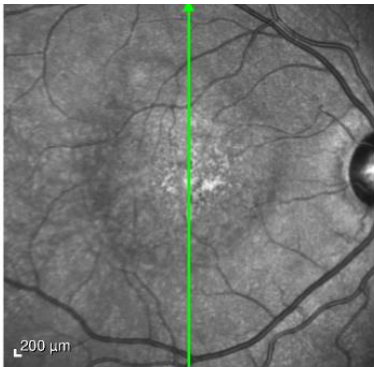
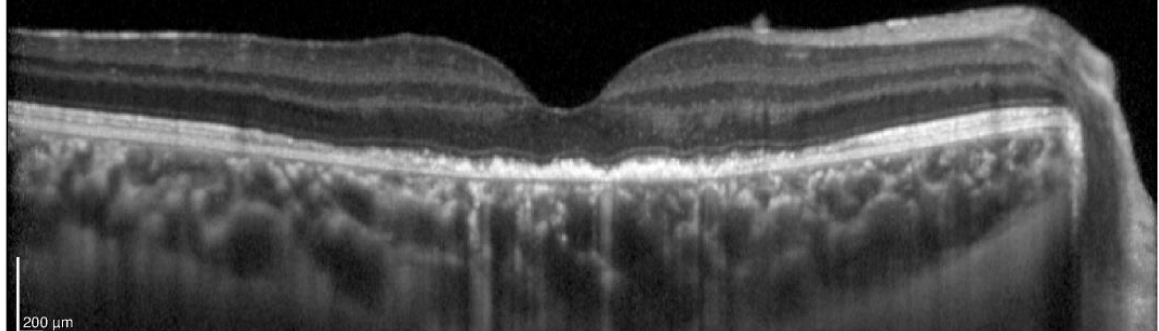


tute

VA
M

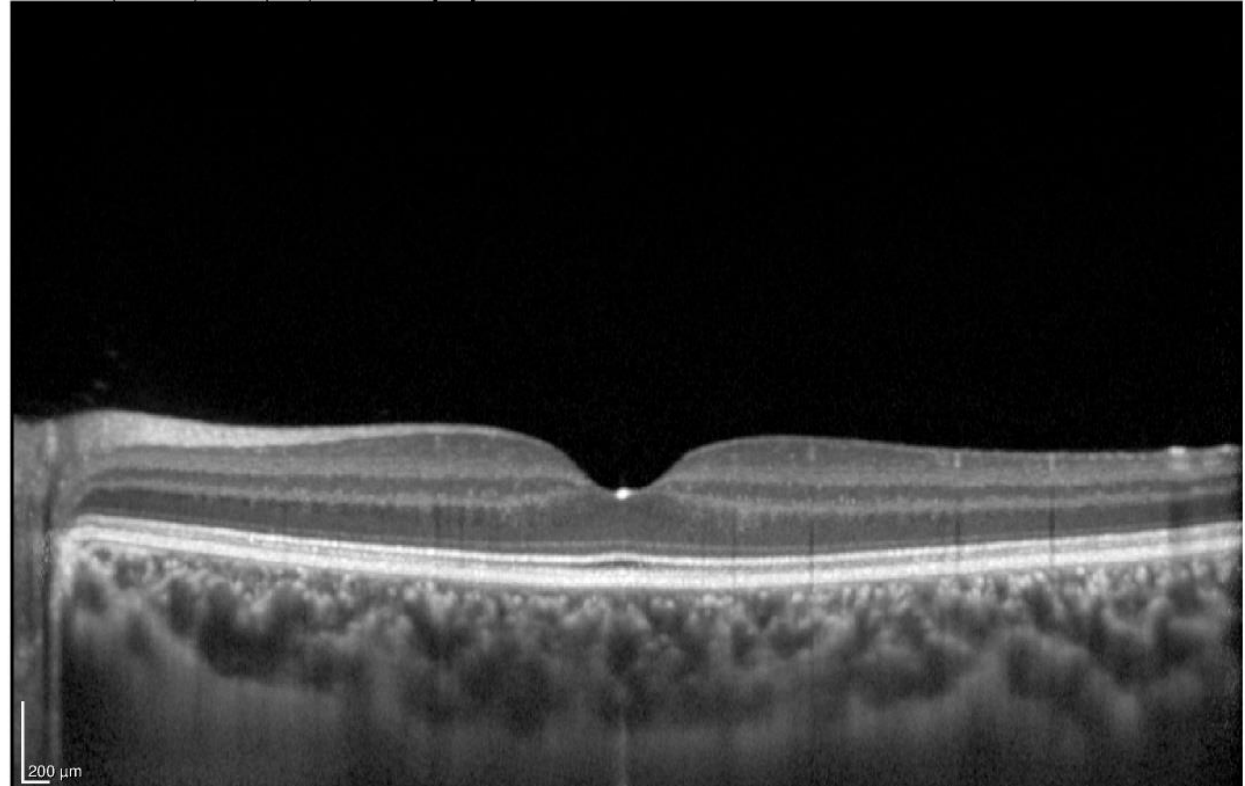
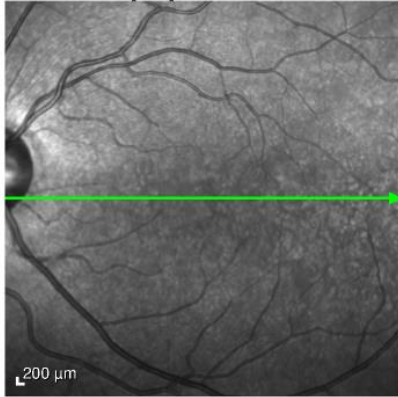


Irregularity of the outer photoreceptor layer





VANDERBILT UNIVERSITY
MEDICAL CENTER



Vanderbilt Eye Institute



Upon further questioning

Developed hand, foot and mouth disease one week prior



Labwork

- Coxsackievirus A9 – 1:64
- Coxsackievirus B3 – 1:160
- Coxsackievirus B4 – 1:320



Course

- Diagnosis: Unilateral acute idiopathic maculopathy
 - Short course of PO steroids

6 week follow-up – Va 20/40 OD

