



VANDERBILT UNIVERSITY
MEDICAL CENTER

Vanderbilt Fellows Vitreoretinal Case Conference



Vanderbilt Eye Institute



Chief Complaint

- 47 year-old woman
- Referred for abnormal fundus findings on routine eye exam



History of Present Illness

- Noted to have fundus changes in 2012 by outside eye MD
- Mild difficulty seeing at night
- Difficulty reading small print
- No photopsias/floaters



Past Medical History

- No significant medical hx
- No past ocular hx



Past Family History

- Father - legally blind
 - Diagnosed with possible Stargardt's disease at age 50 (20/20 at time of dx)
- Aunt (father's sister) also affected



Social History

- Denies EtoH or tobacco
- no illicit drug use



Review of Systems

- (-) HA, fevers, chills, joint pain, abdominal pain, diarrhea, N/V
- (-) recent illnesses



Examination

	OD	OS
Vision	20/25	20/20
Pupils	r/r No APD	r/r
Motility	Full Ortho	Full
IOP	17	18
External	Wnl	Wnl
CVF	FCF	FCF

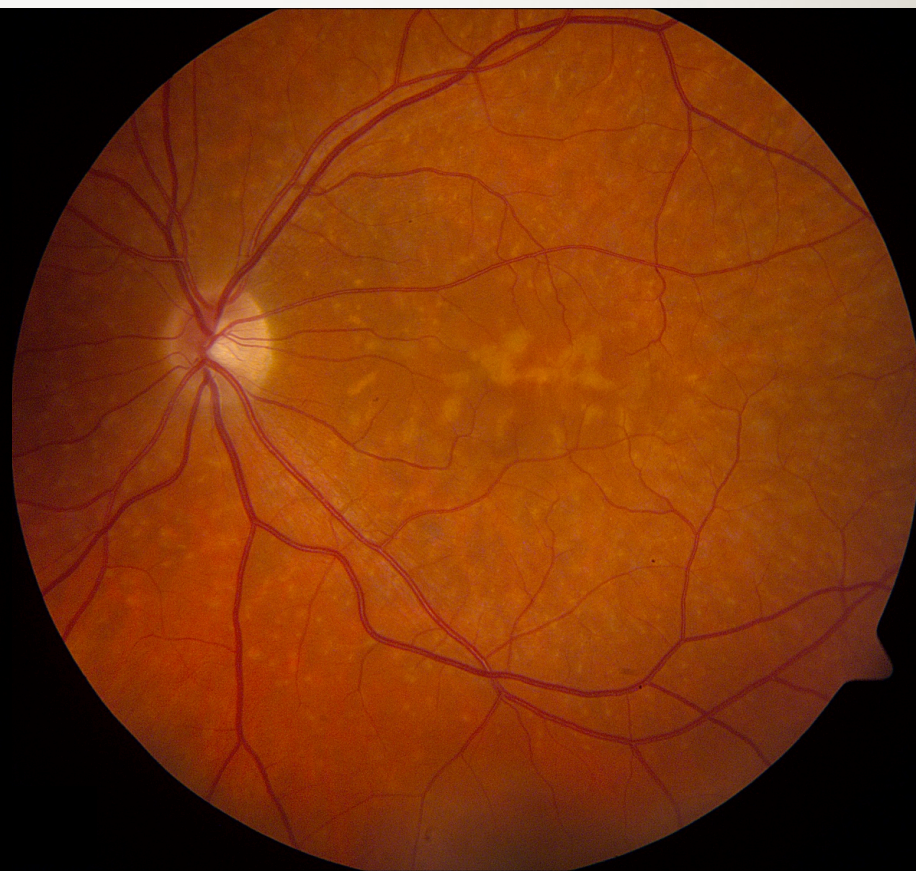
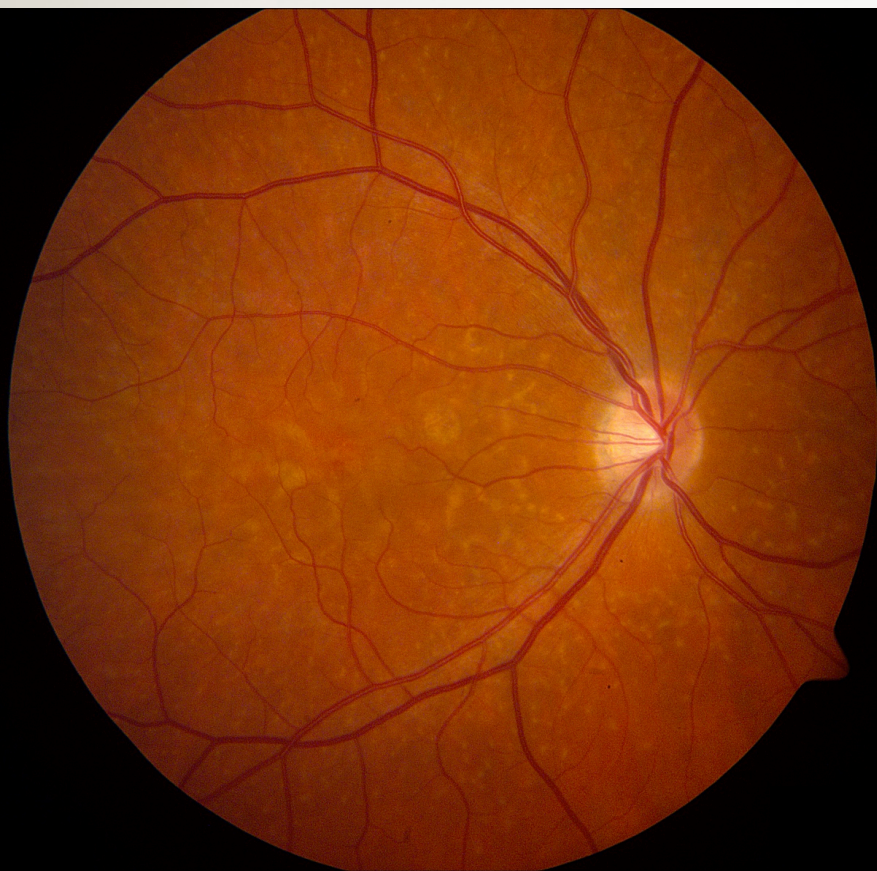

Anterior Segment

	OD	OS
L/L/L	Wnl	Wnl
C/S	w/q	w/q
K	Clear	Clear
A/C	d/q	d/q
I/P	r/r	r/r
L	Clear	Clear
Avit	clear	clear



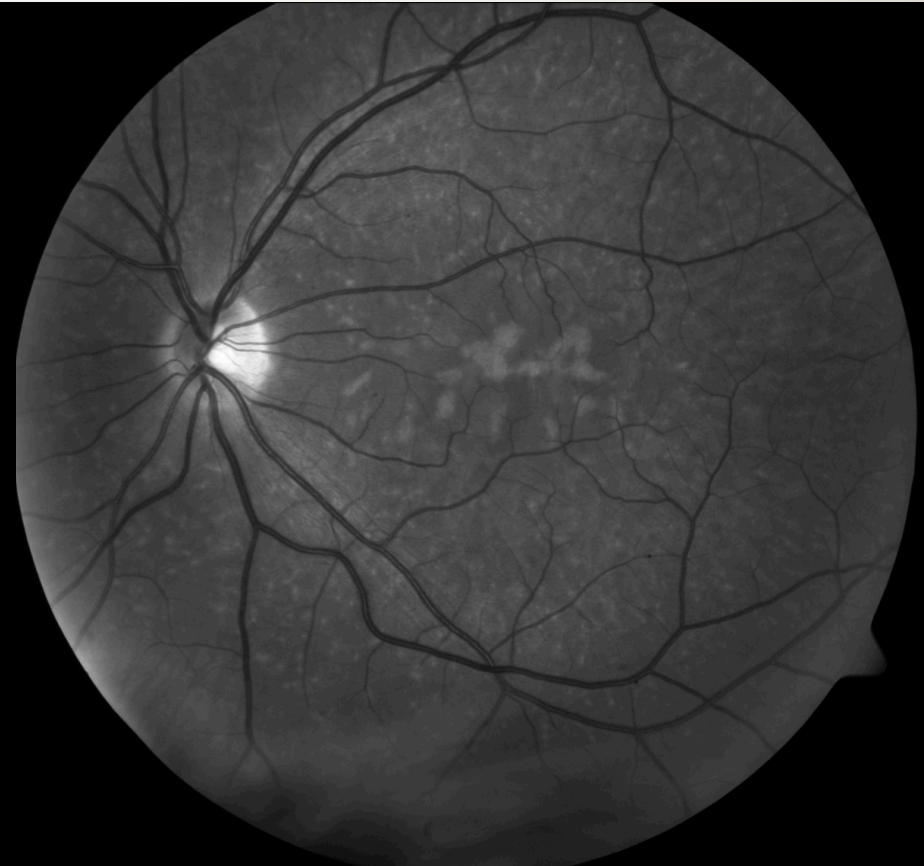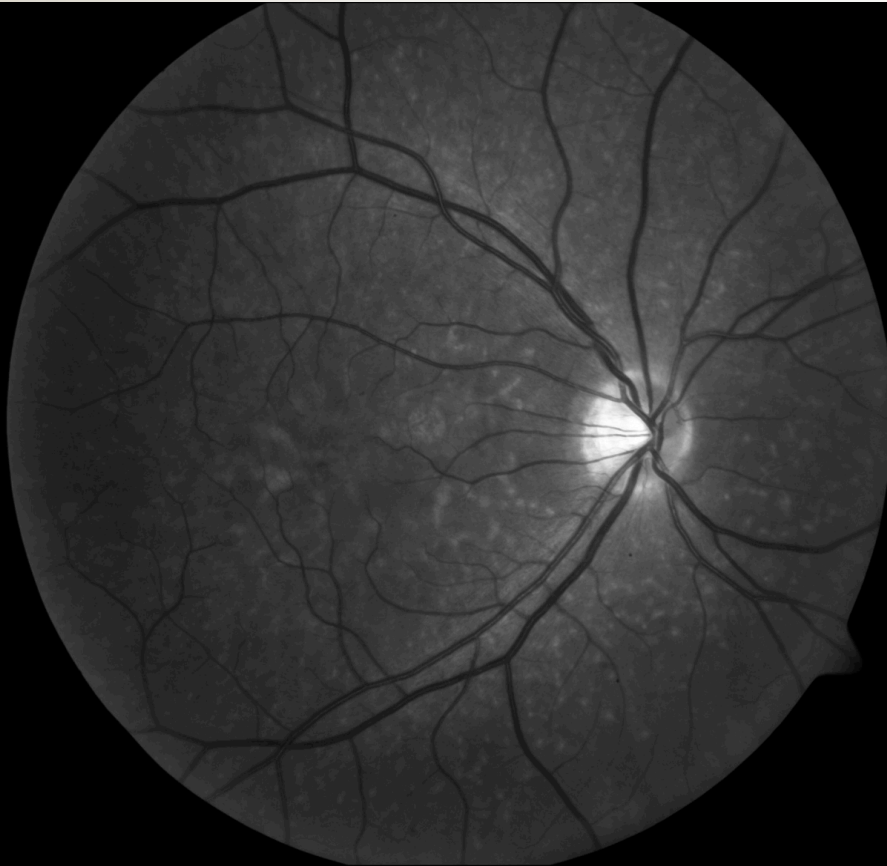VANDERBILT UNIVERSITY
MEDICAL CENTER



Vanderbilt Eye Institute



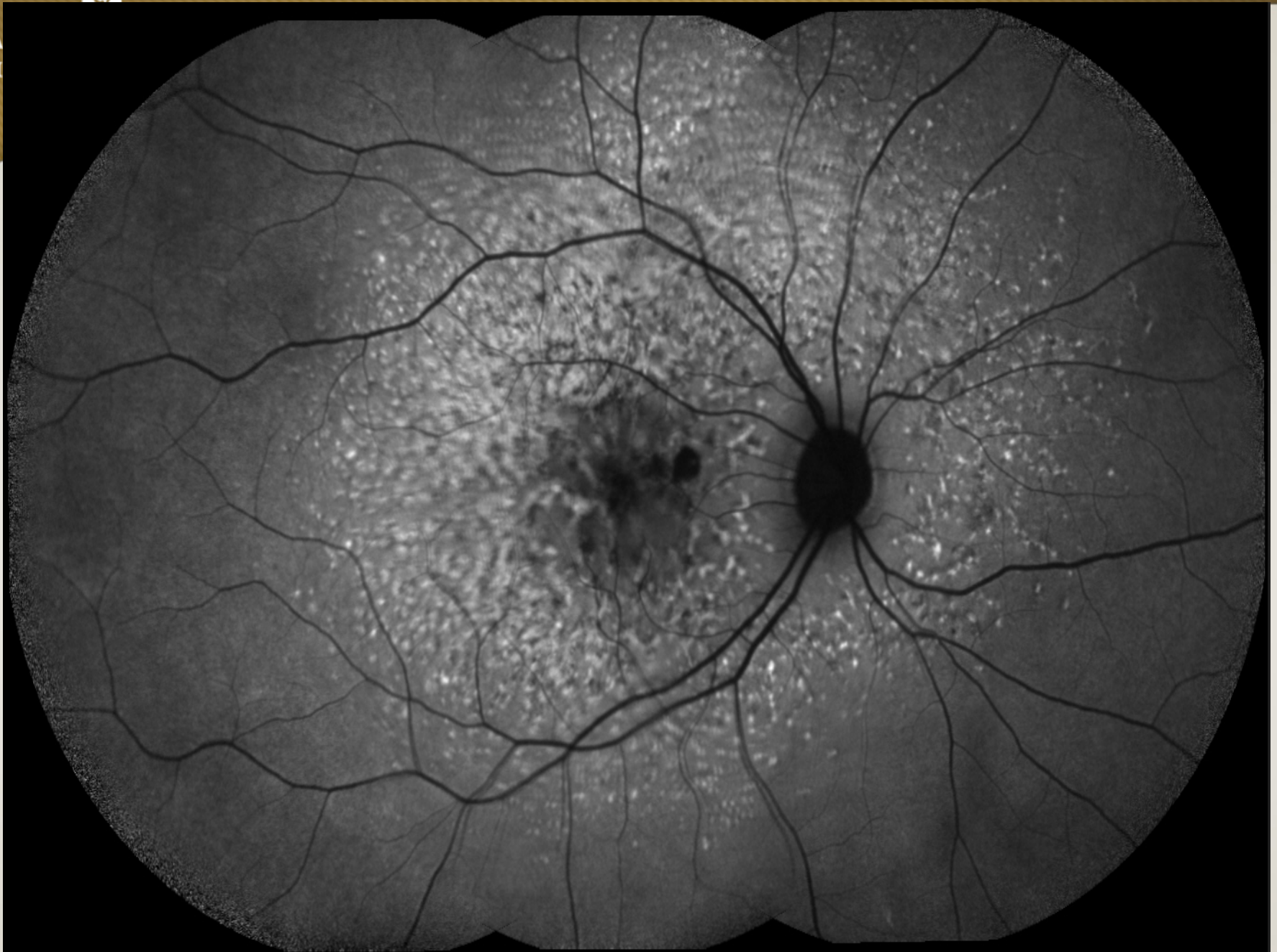VANDERBILT UNIVERSITY
MEDICAL CENTER

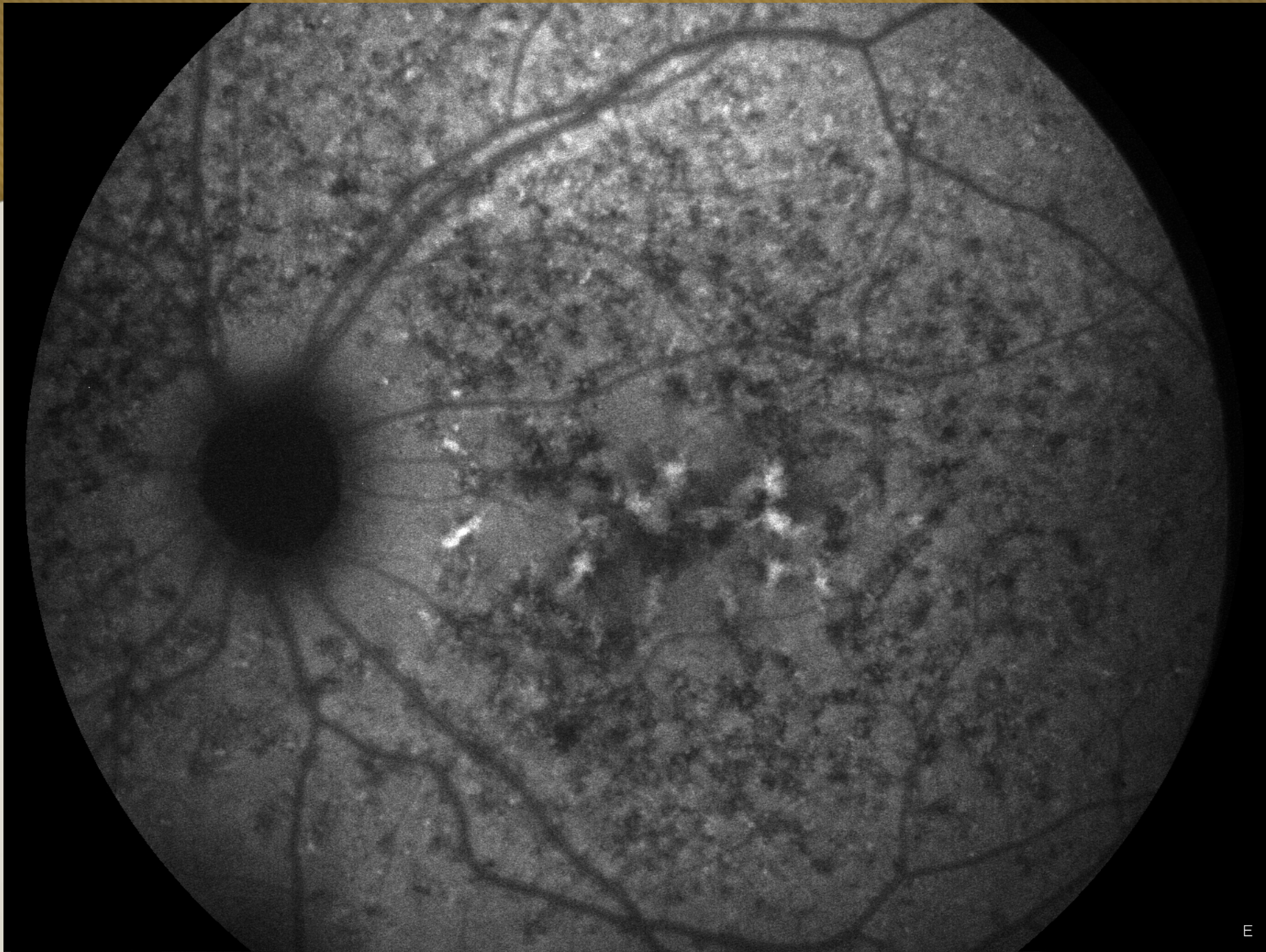


Vanderbilt Eye Institute



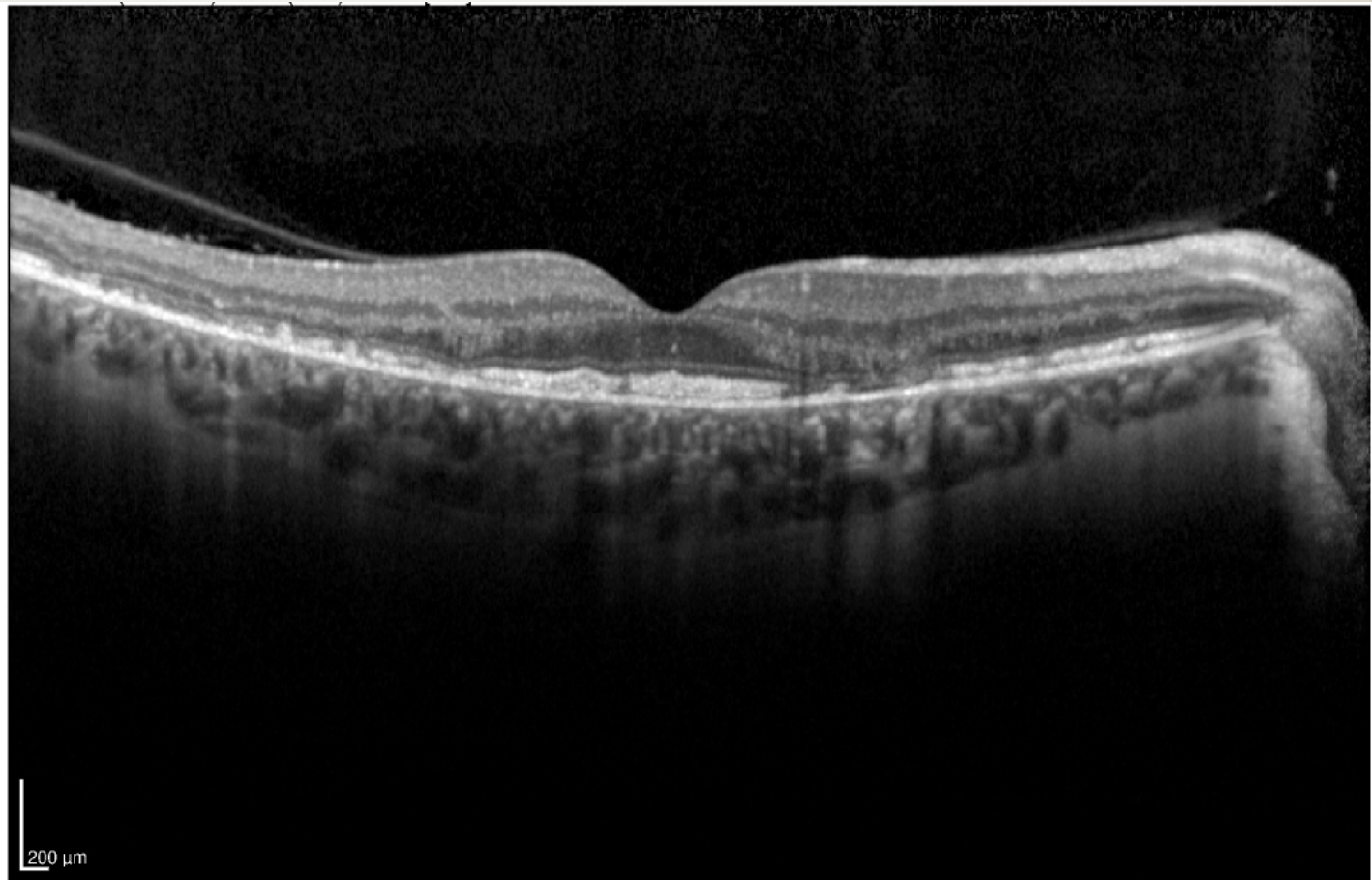
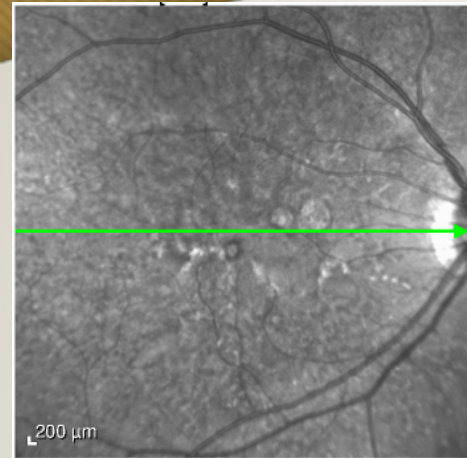
VA
M



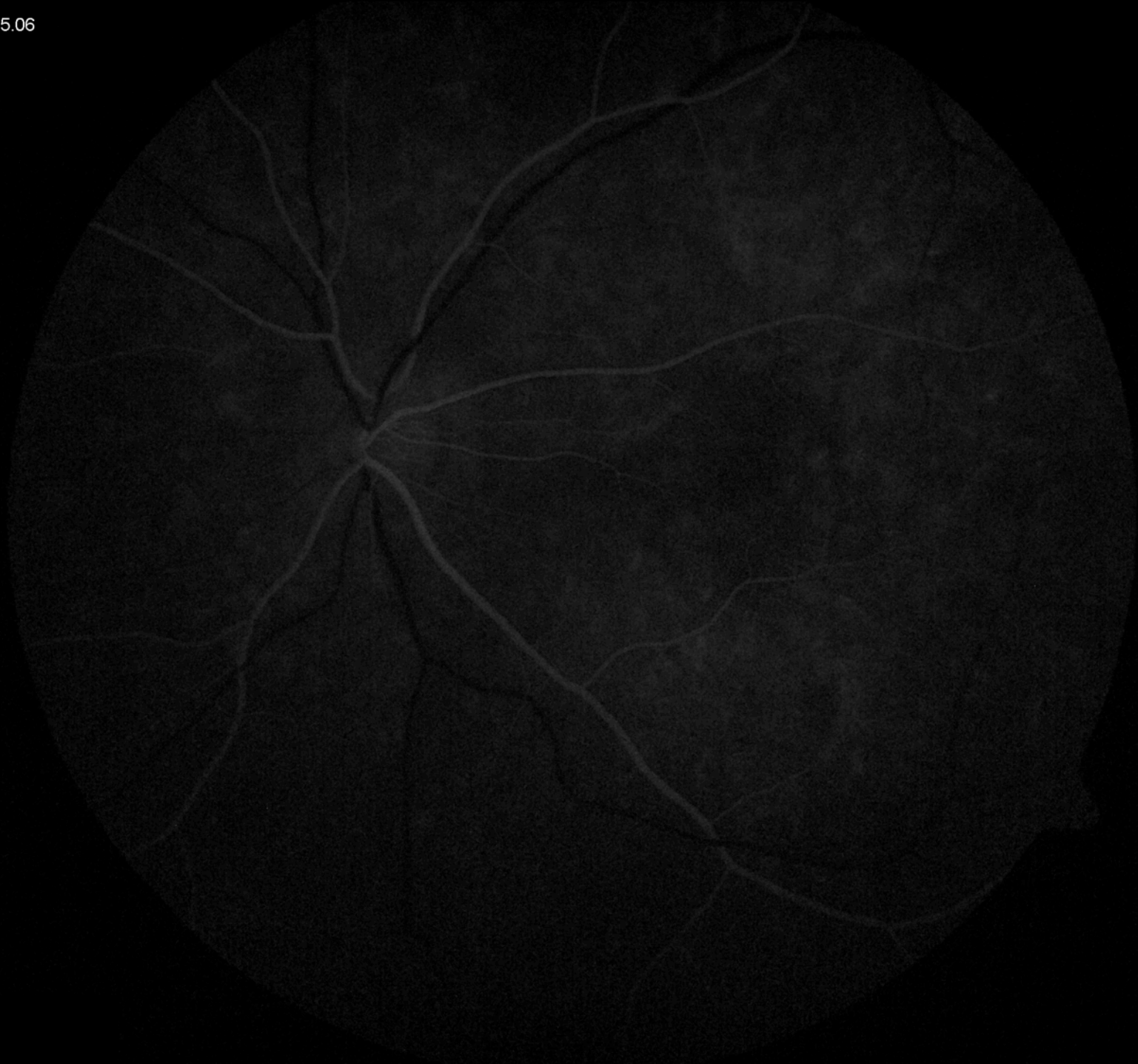



VANDERBILT UNIVERSITY
MEDICAL CENTER

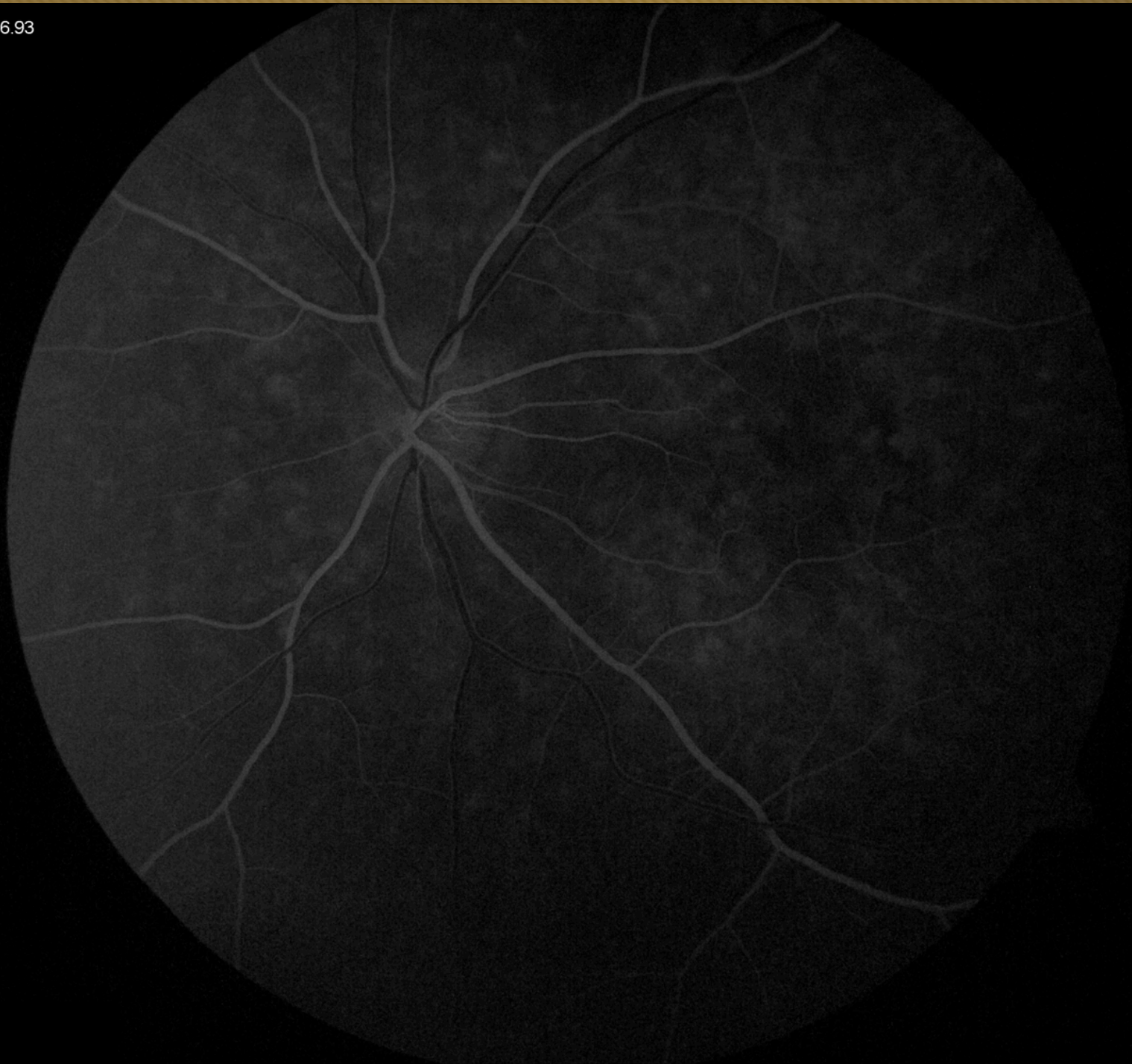

Vanderbilt Eye Institute



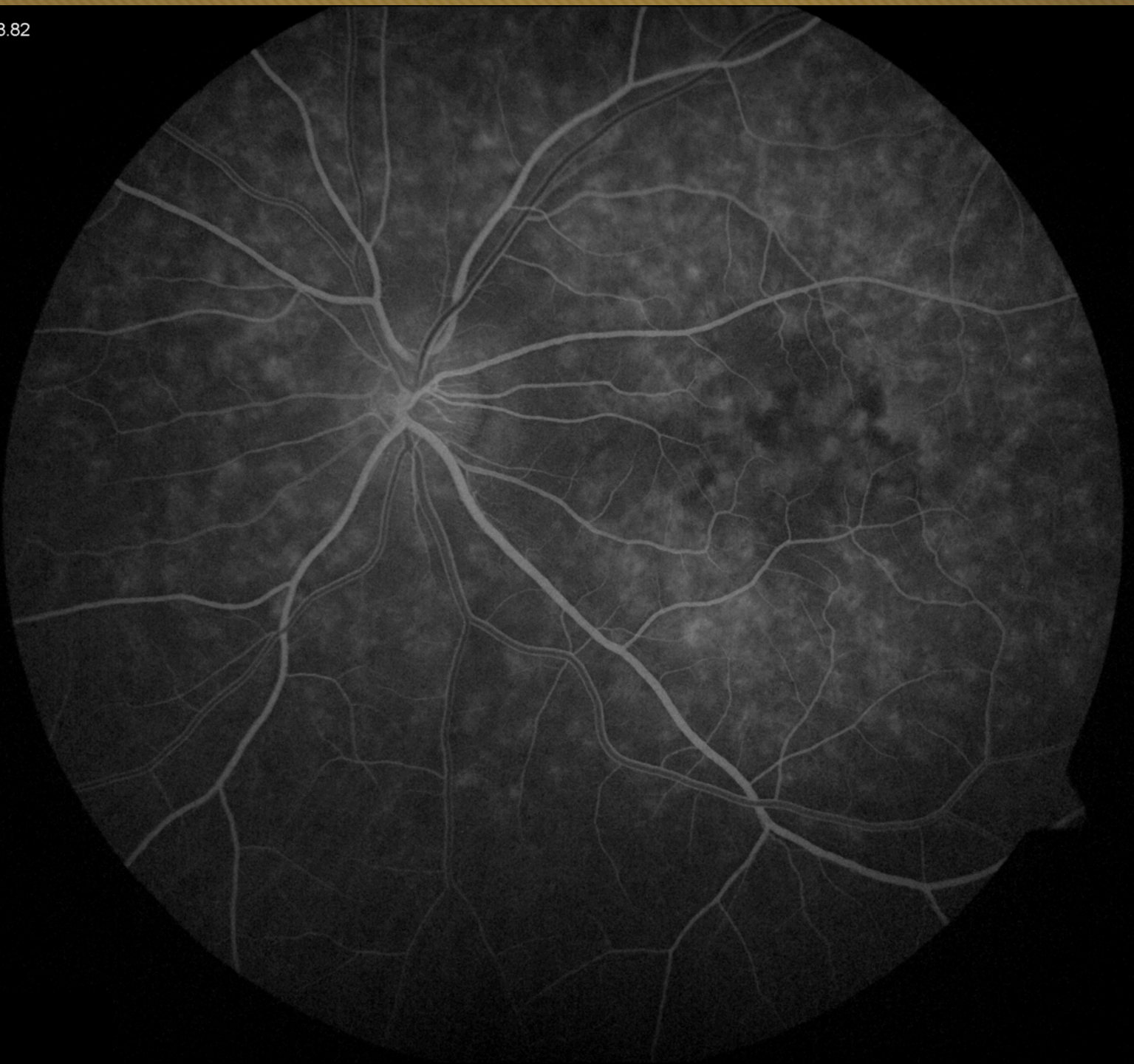
00:16.93

VANDE
MEDI



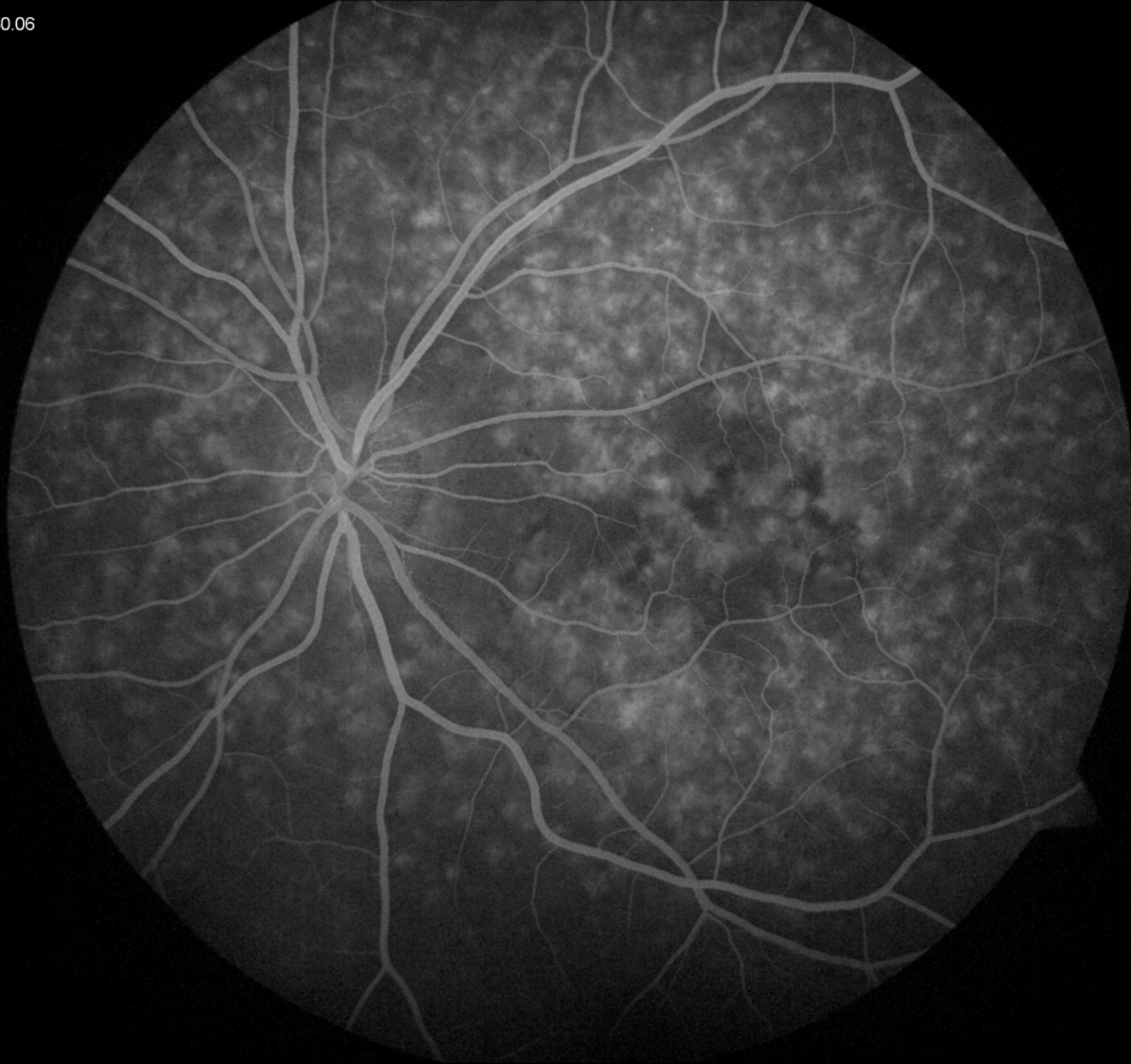00:18.82

VANDE
MEDI



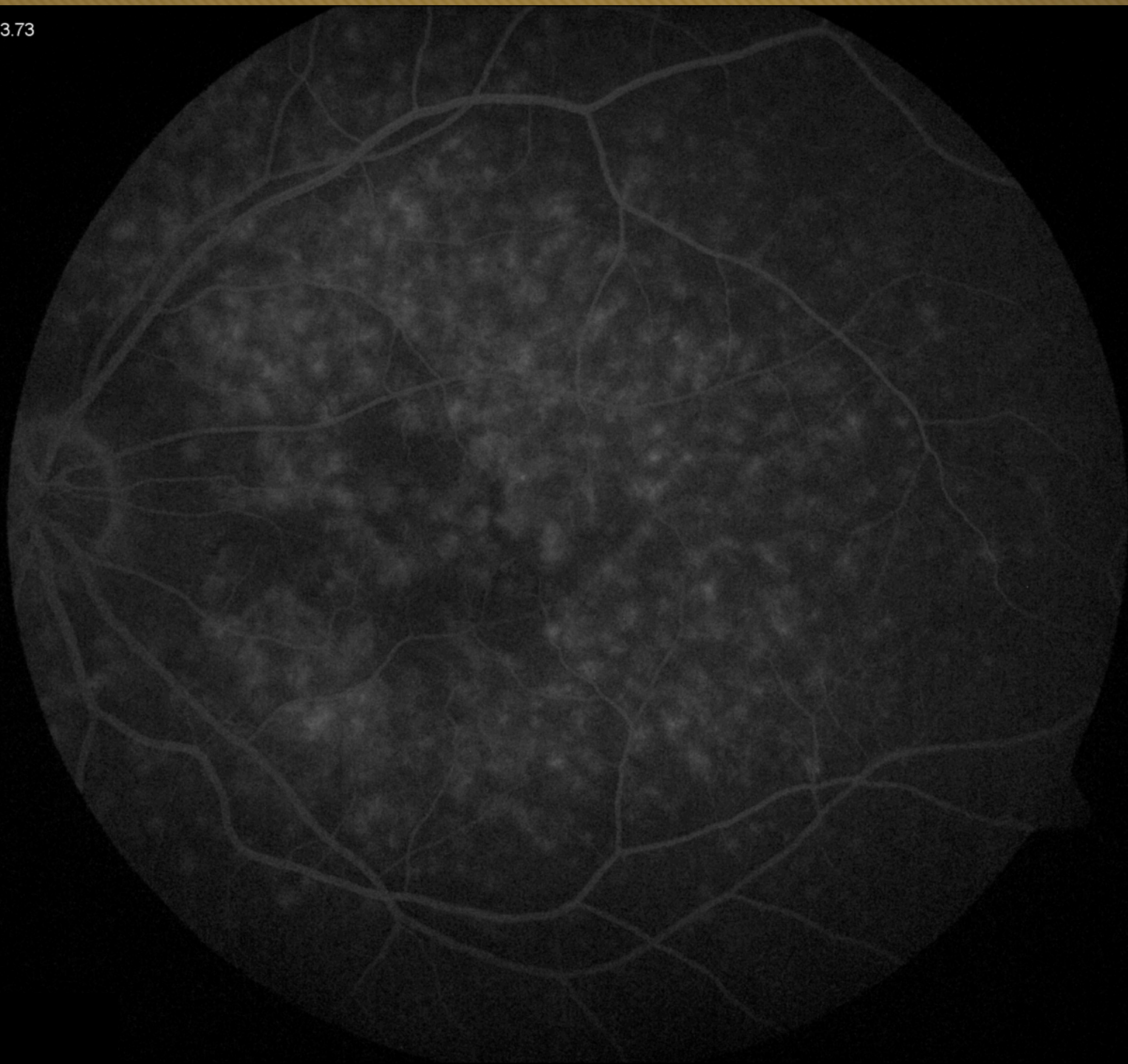
00:30.06

VANDER
MEDI



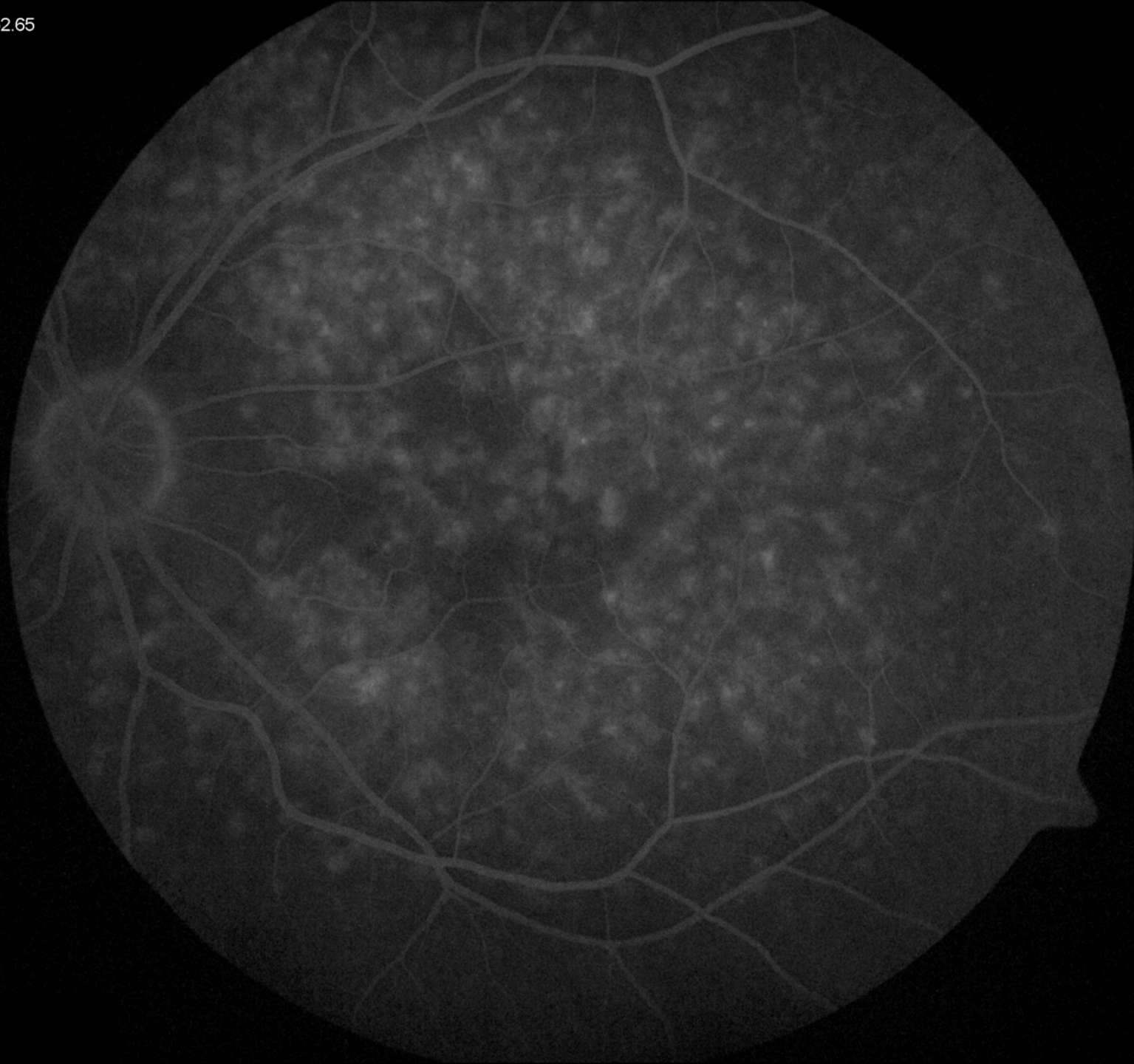
02:03.73

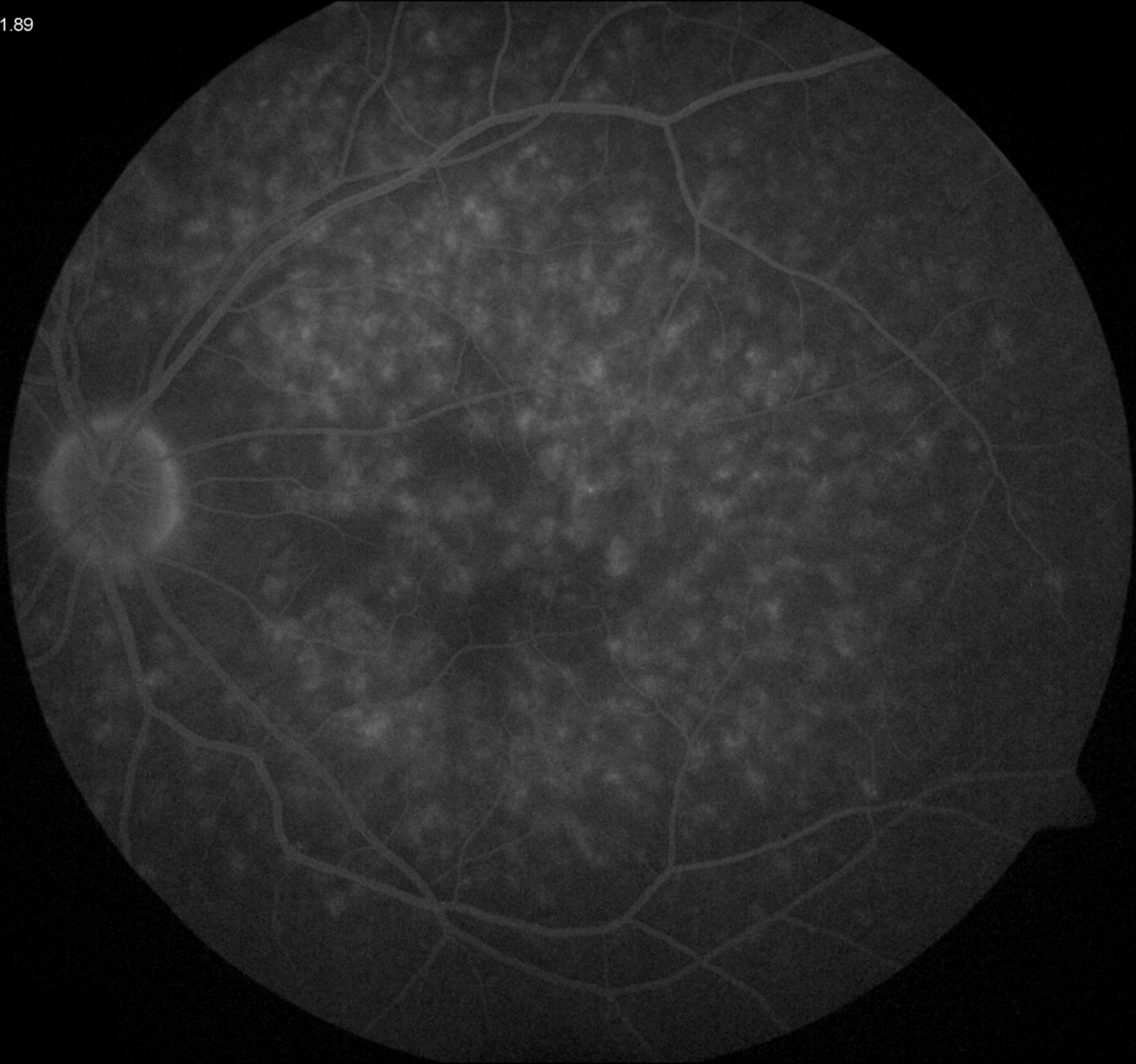
VANDE
MEDI



04:52.65

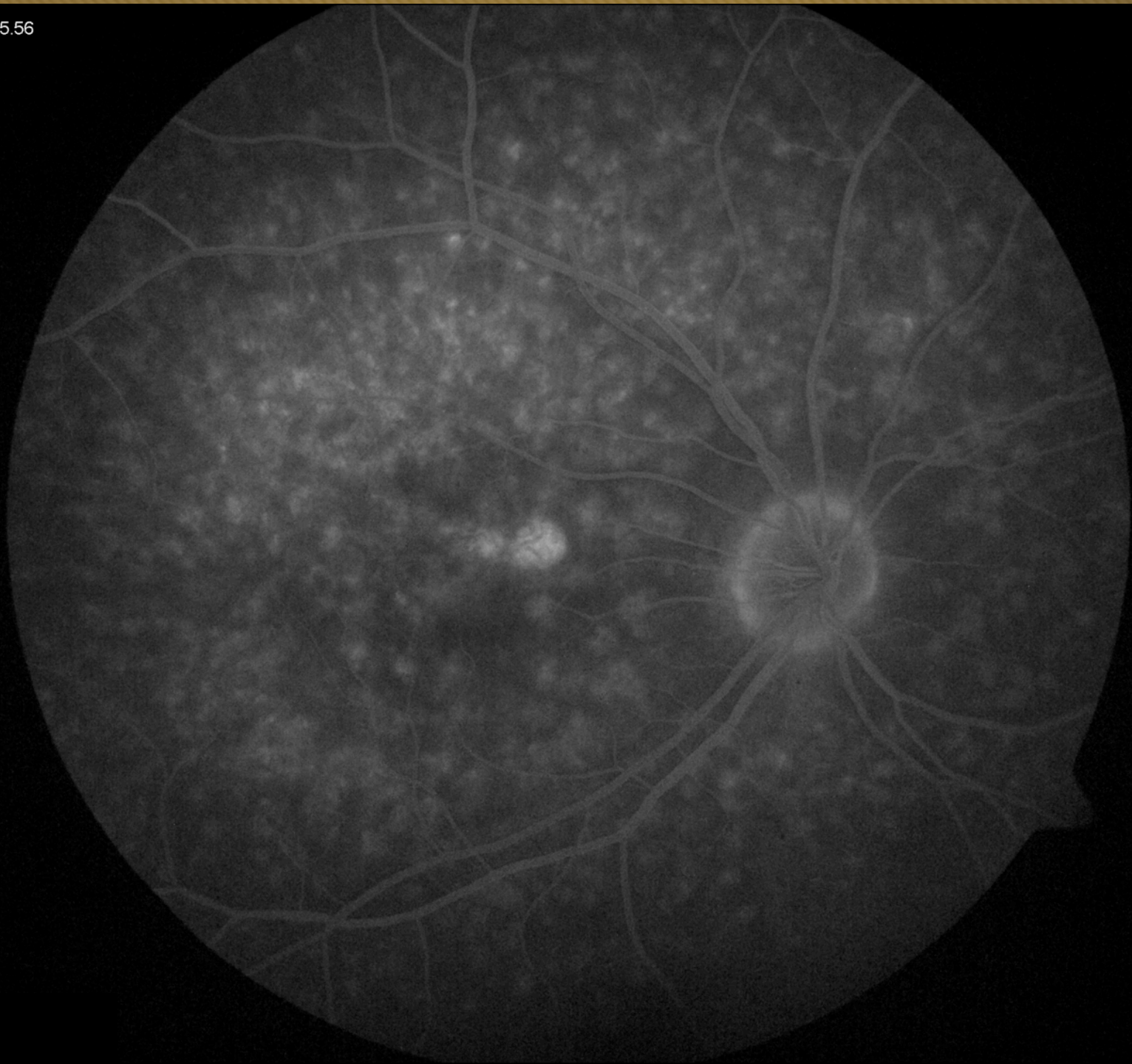
VANDE
MEDI





10:15:56

VANDE
MEDI





Differential Diagnosis

- Stargardt's
- Pattern Dystrophy
 - Group 4 (Multifocal Pattern Dystrophy)



Genetic Testing

- ABCA4 testing:
 - NO mutation detected
- PRPH2-RP testing:
 - Heterozygous mutation c.629C>G
 - Typically seen in AD inherited **adult-onset foveomacular dystrophy**