



VANDERBILT UNIVERSITY
MEDICAL CENTER

Vanderbilt Fellows Vitreoretinal Case Conference



Vanderbilt Eye Institute



Chief Complaint

- 44 y/o Caucasian woman
- Right eye visual disturbance x 1 year



History of Present Illness

- Inferior visual field defect right eye
- No pain/redness
- No blurring of vision
- White flashes in right eye x 2 weeks
- No floaters or curtains



Review of Systems

- (+) mild headaches
- (+) constipation

- (-) fevers, chills, joint pain, abdominal pain, diarrhea, N/V, rashes, cough, hematuria, blood in stool or oral ulcers

- (-) recent illnesses



Past Medical History

- Hypertension
- No past ocular hx
- No significant family hx

- 4 Pregnancies (most recently delivered 5 months ago)



Social History

- Denies tobacco/alcohol/illicit drug use
- Works from home
- (-) pets
- (-) foreign travel



Exam

	OD	OS
Vision	20/25	20/20
Color Plates	11/11	11/11
Pupils	5 → 2.5 No apd	5 → 2.5
Motility	Full	Full
IOP	12	12
External	Wnl	Wnl

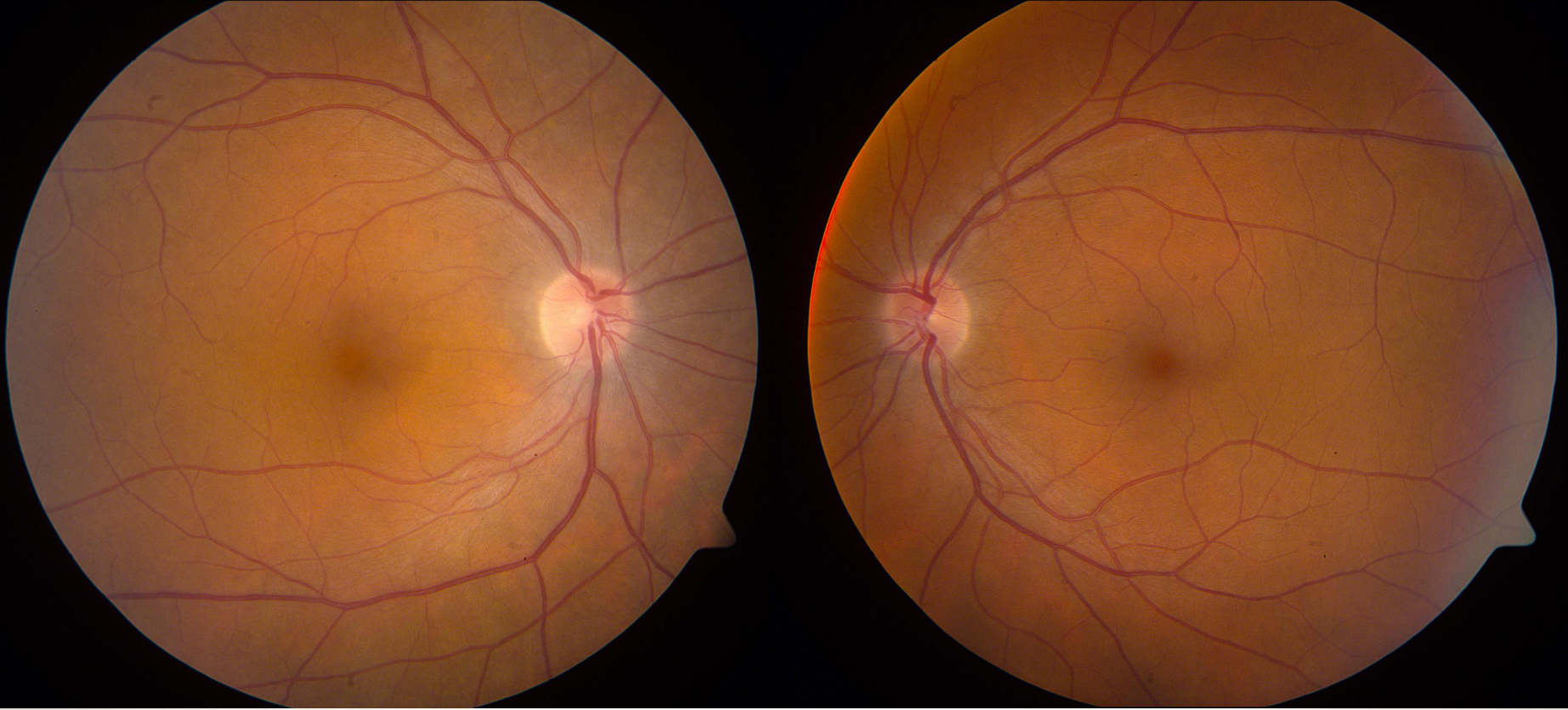

Anterior Segment

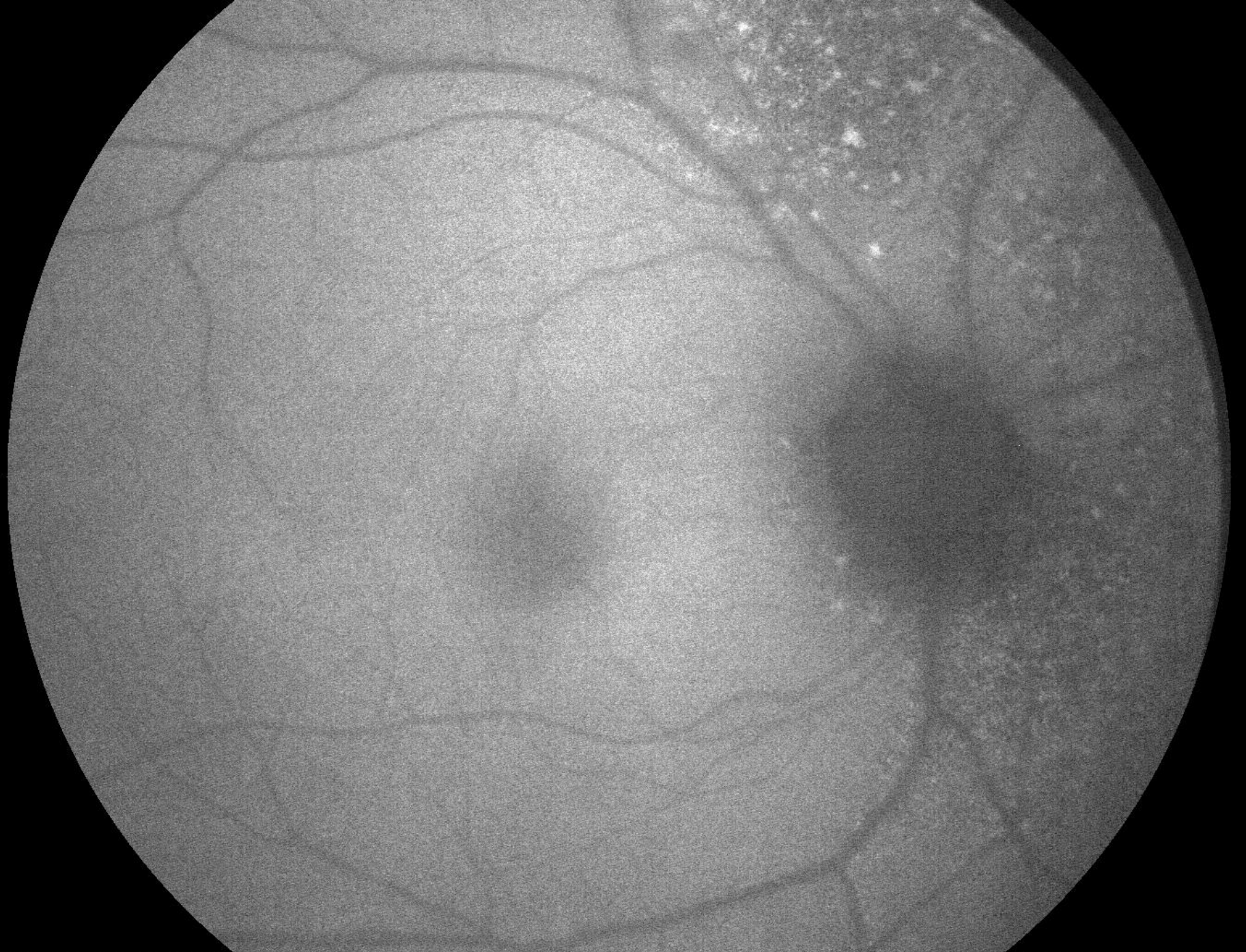	OD	OS
L/L/L	Wnl	Wnl
C/S	w/q	w/q
K	Clear	Clear
A/C	d/q	d/q
I/P	r/r	r/r
L	Clear	Clear
Avit	clear	clear

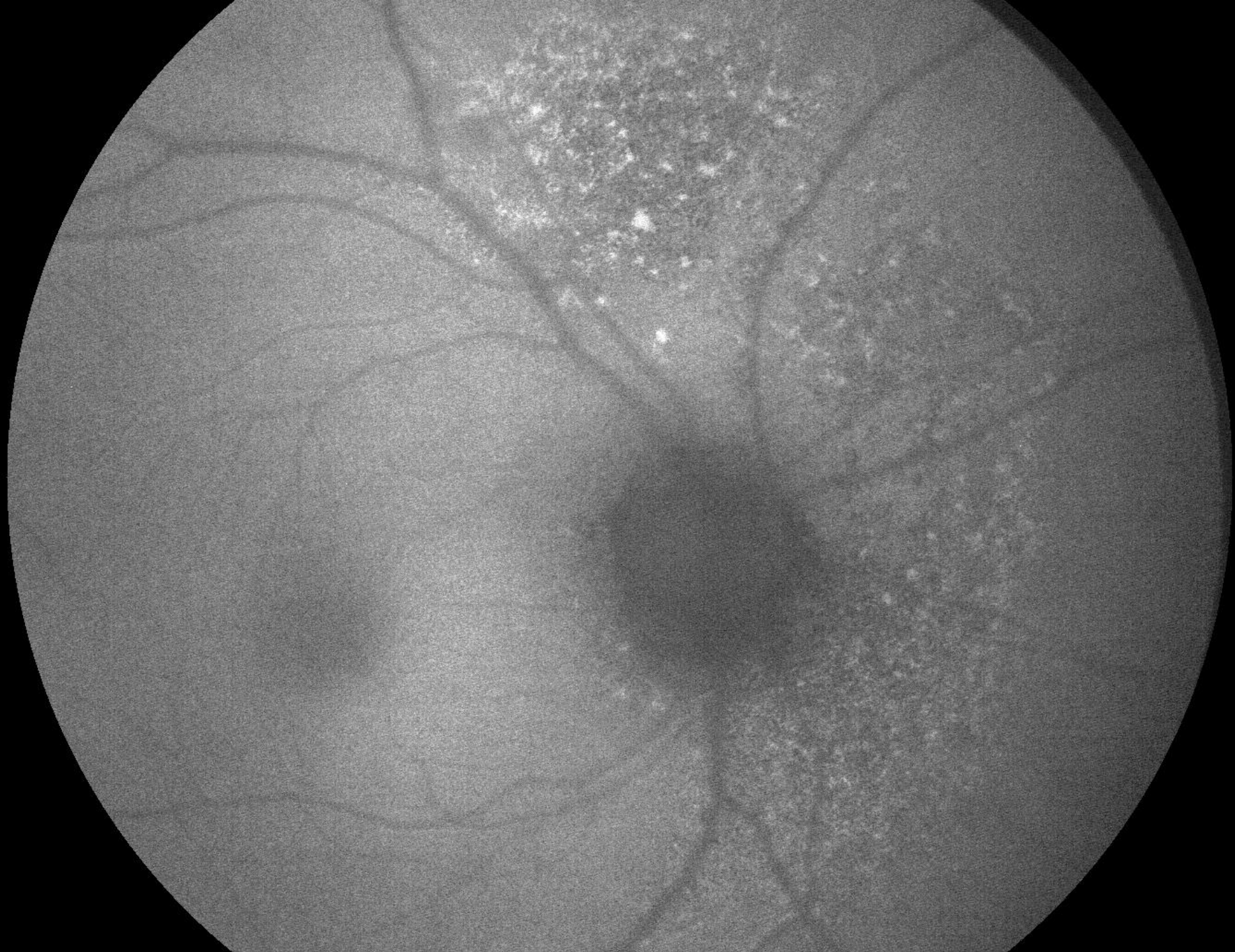


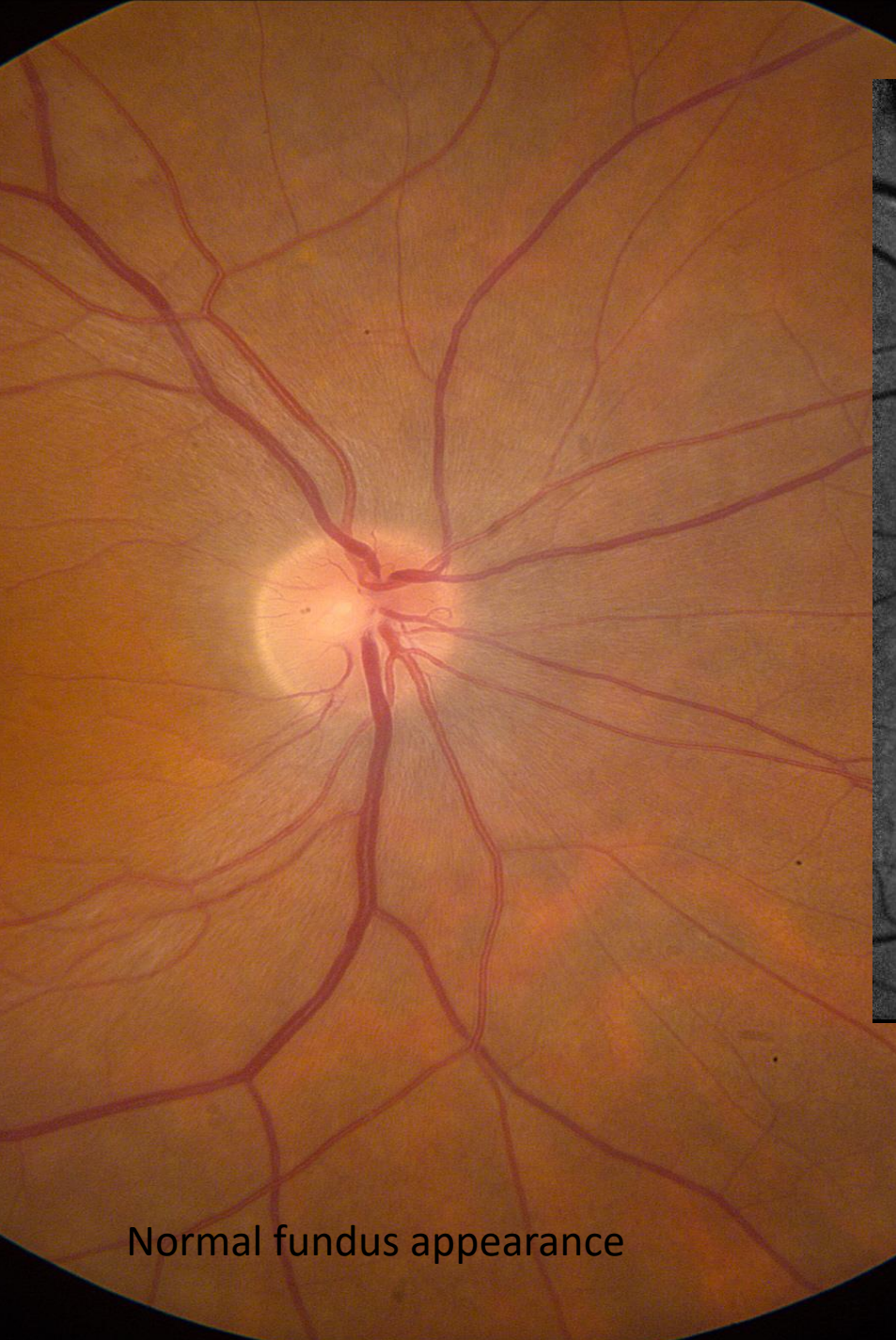
VANDERBILT UNIVERSITY
MEDICAL CENTER



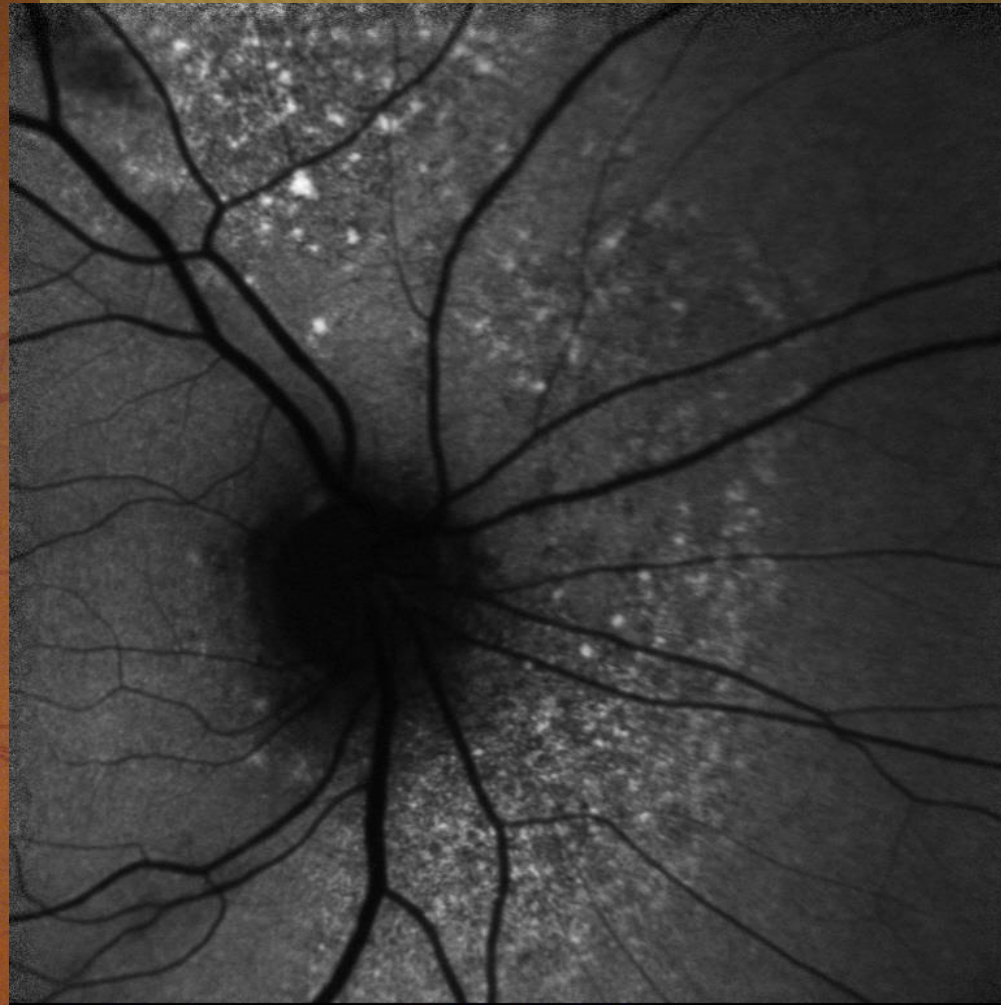
Vanderbilt Eye Institute





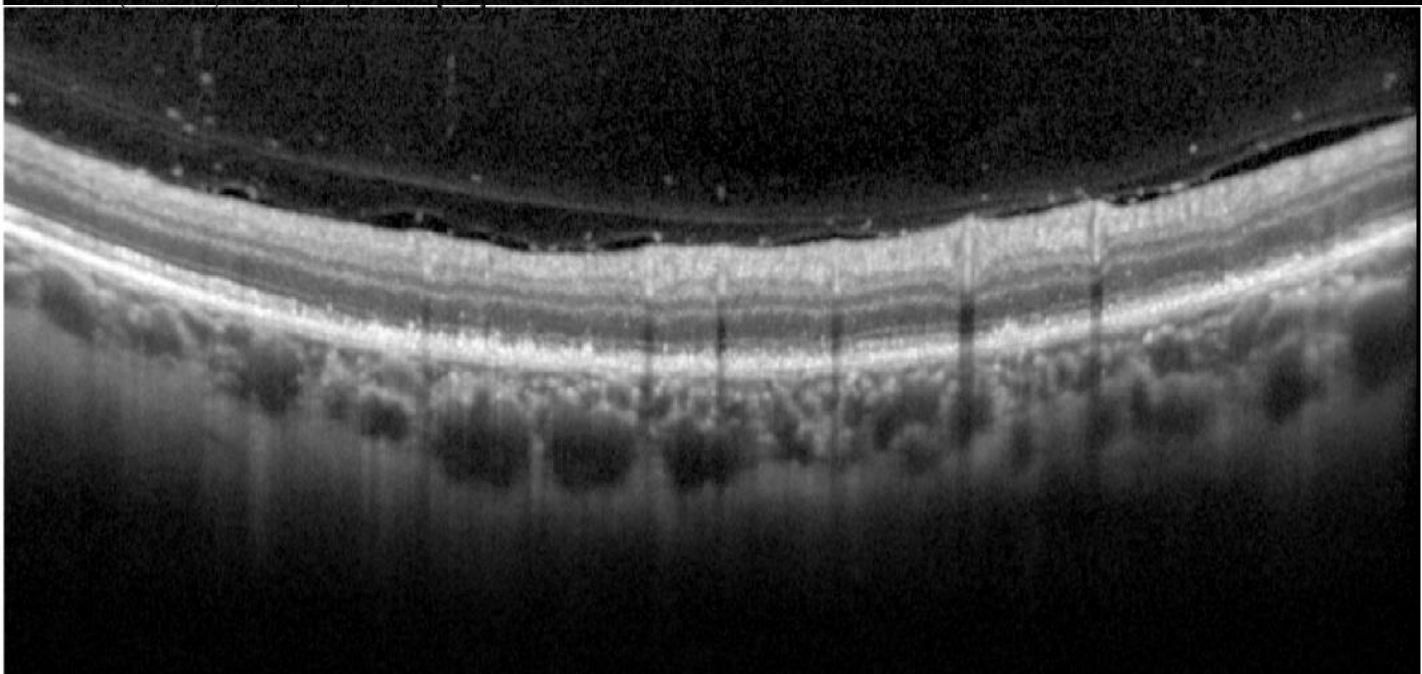
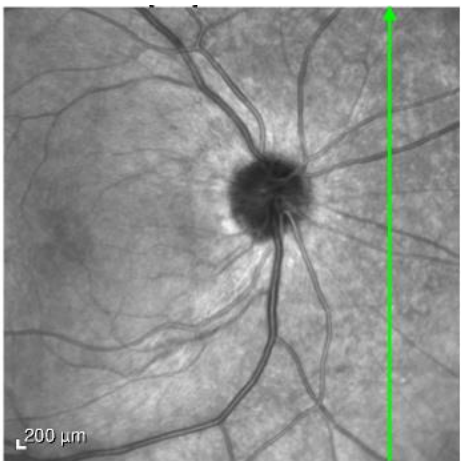
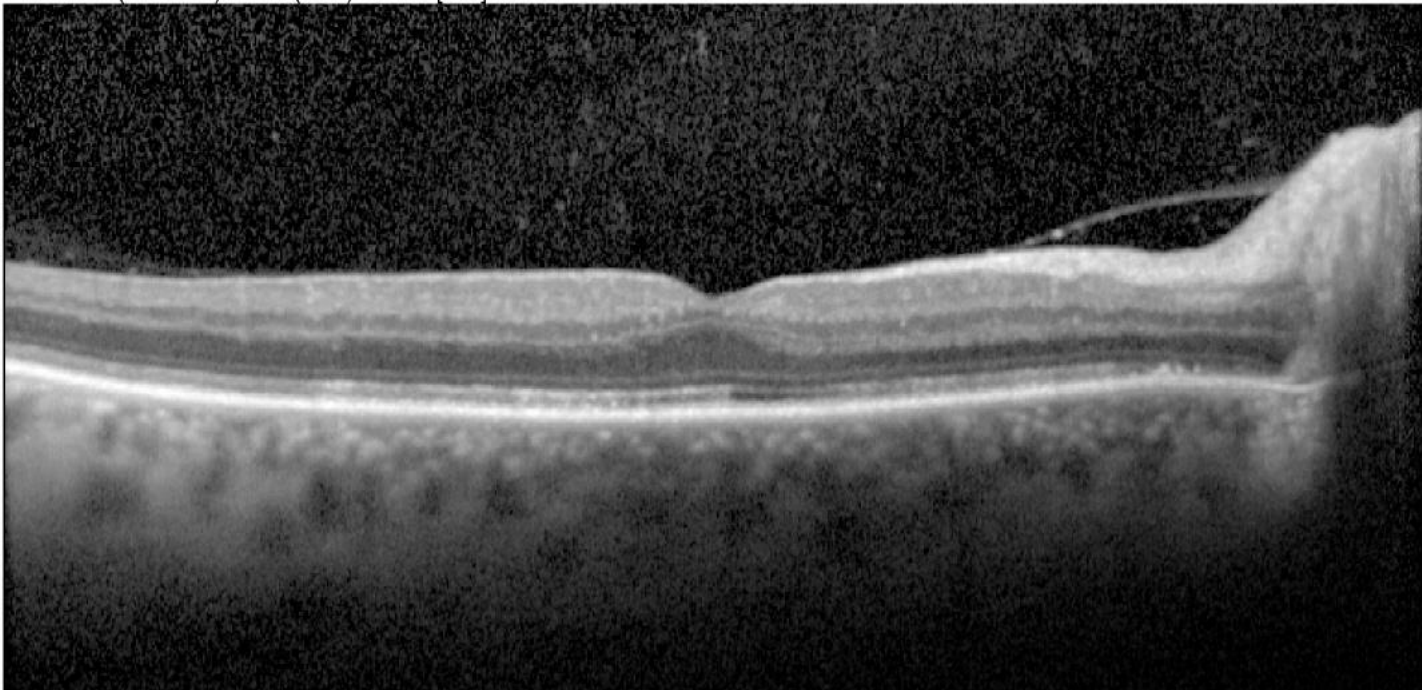
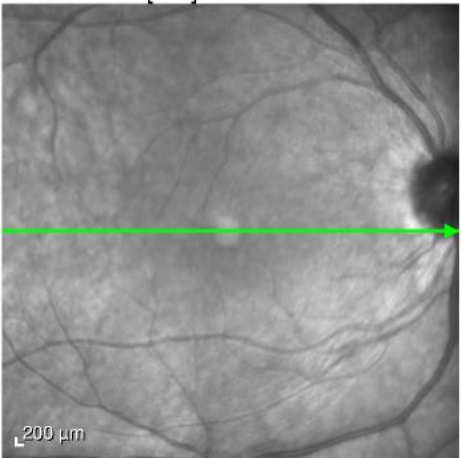


Normal fundus appearance



Speckled hyperautofluorescence

Vanderbilt Eye Institute



Ellipsoid disruption



Diagnosis

- Acute Zonal Occult Outer Retinopathy (AZOOR)