



VANDERBILT UNIVERSITY
MEDICAL CENTER

Vanderbilt Fellows Vitreoretinal Case Conference



Vanderbilt Eye Institute



Chief Complaint

- 28 year-old woman
- Black spots in both eyes for approximately 18 hours
 - Preceded by headache
 - No photopsias/floaters



Past Medical History

- No significant medical hx
- No past ocular hx
- No significant family hx



Social History

- (+) EtoH
- no illicit drug use



Review of Systems

- (-) fevers, chills, joint pain, abdominal pain, diarrhea
- (+) recent illnesses (recent 'GI bug')



Exam

	OD	OS
Vision	20/20-2	20/20
Pupils	r/r	r/r
Motility	Full Ortho	Full
IOP	19	17
External	Wnl	Wnl
CVF	FCF	FCF



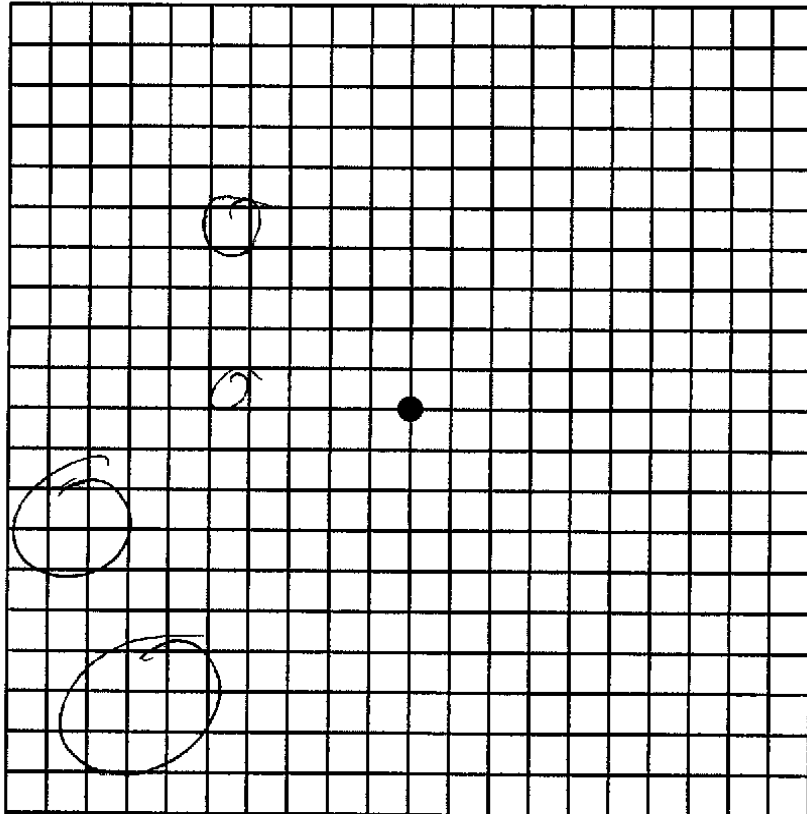
Anterior Segment

	OD	OS
L/L/L	Wnl	Wnl
C/S	w/q	w/q
K	Clear	Clear
A/C	d/q No cell	d/q
I/P	r/r	r/r
L	Clear	Clear
Avit	clear	clear



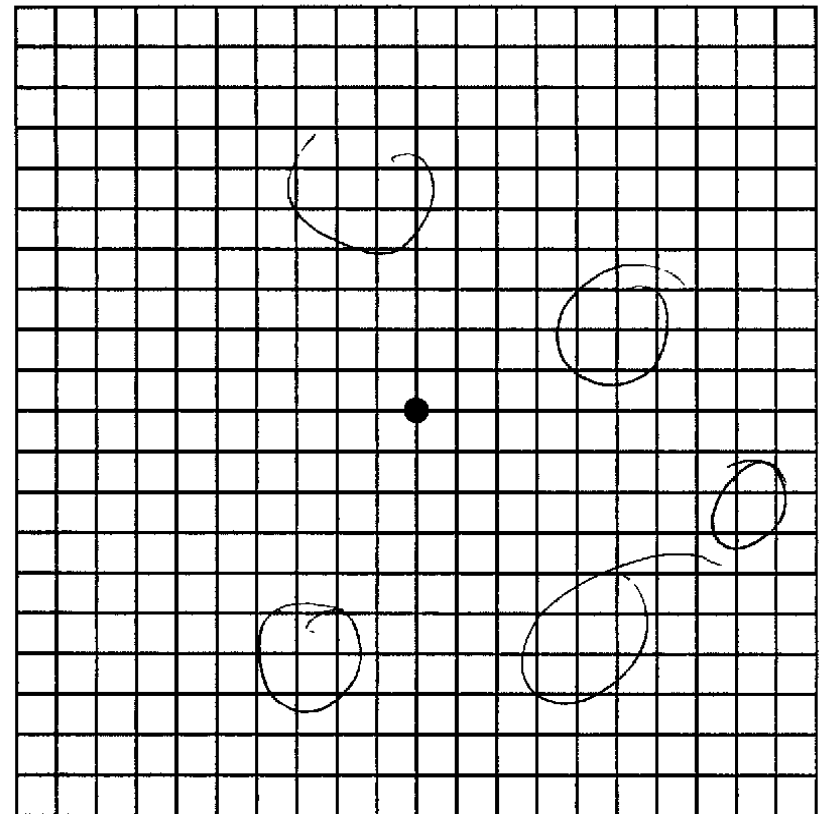
AMSLER RECORDING CHART

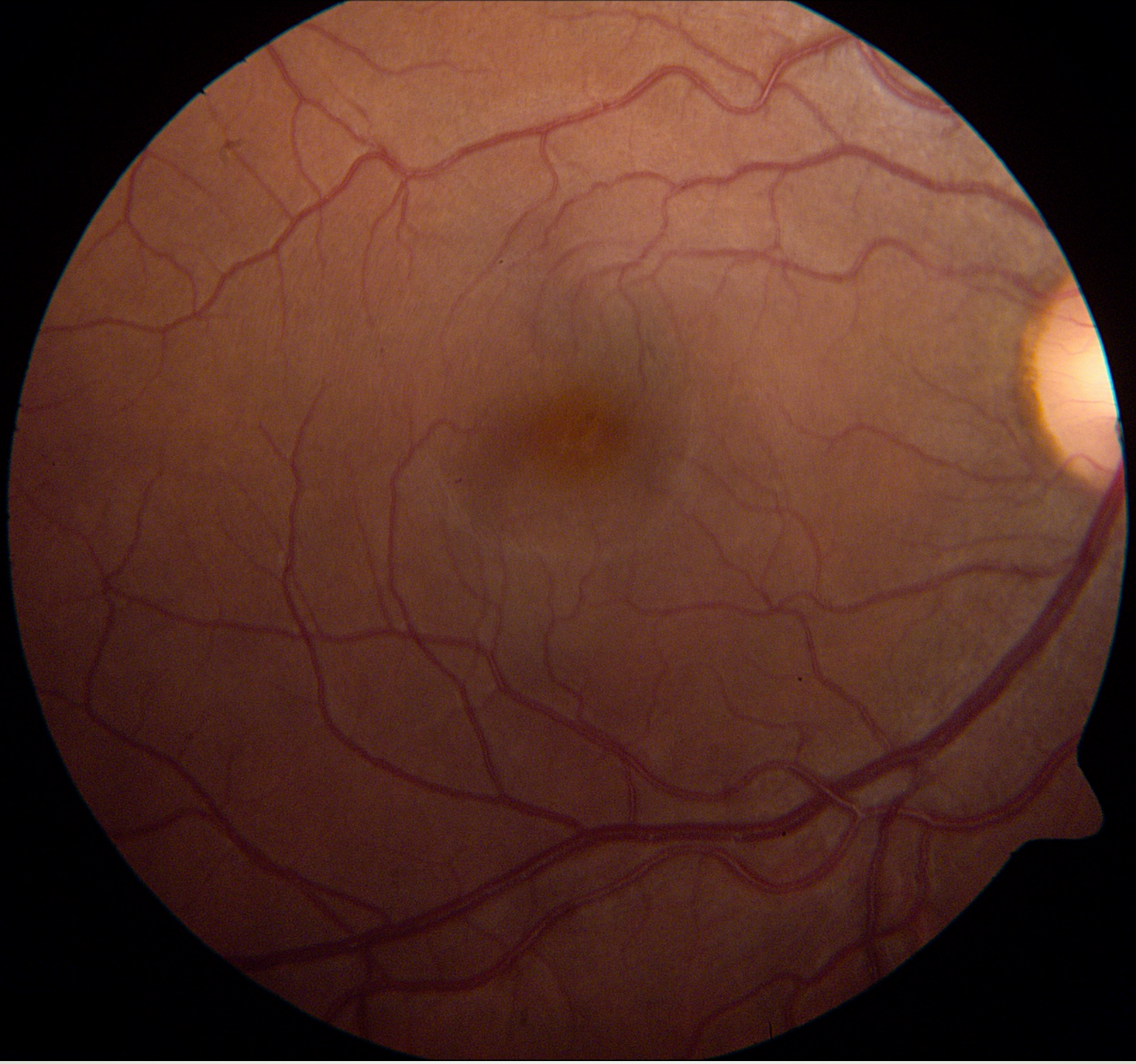Left

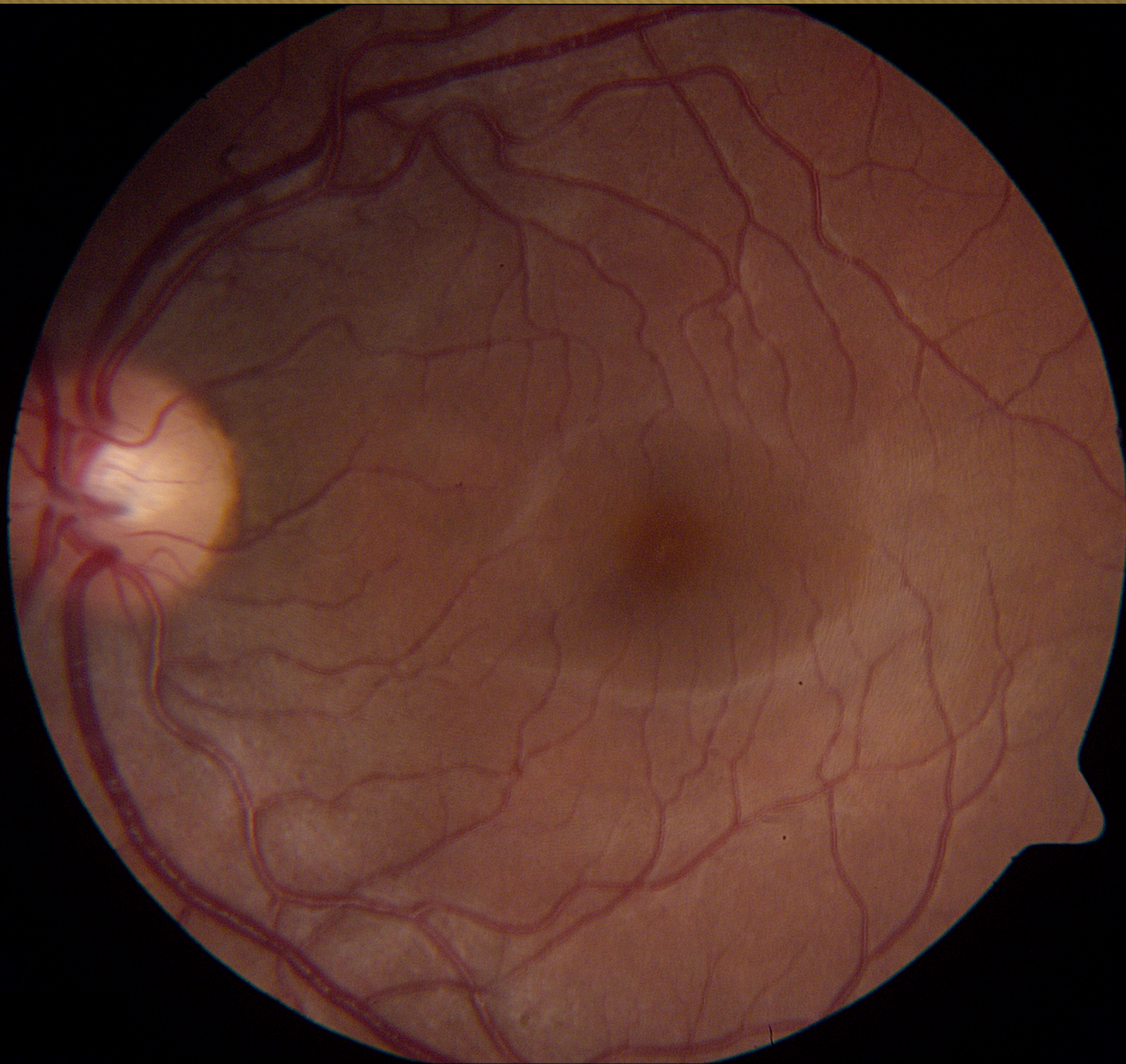

AMSLER RECORDING CHART

Right



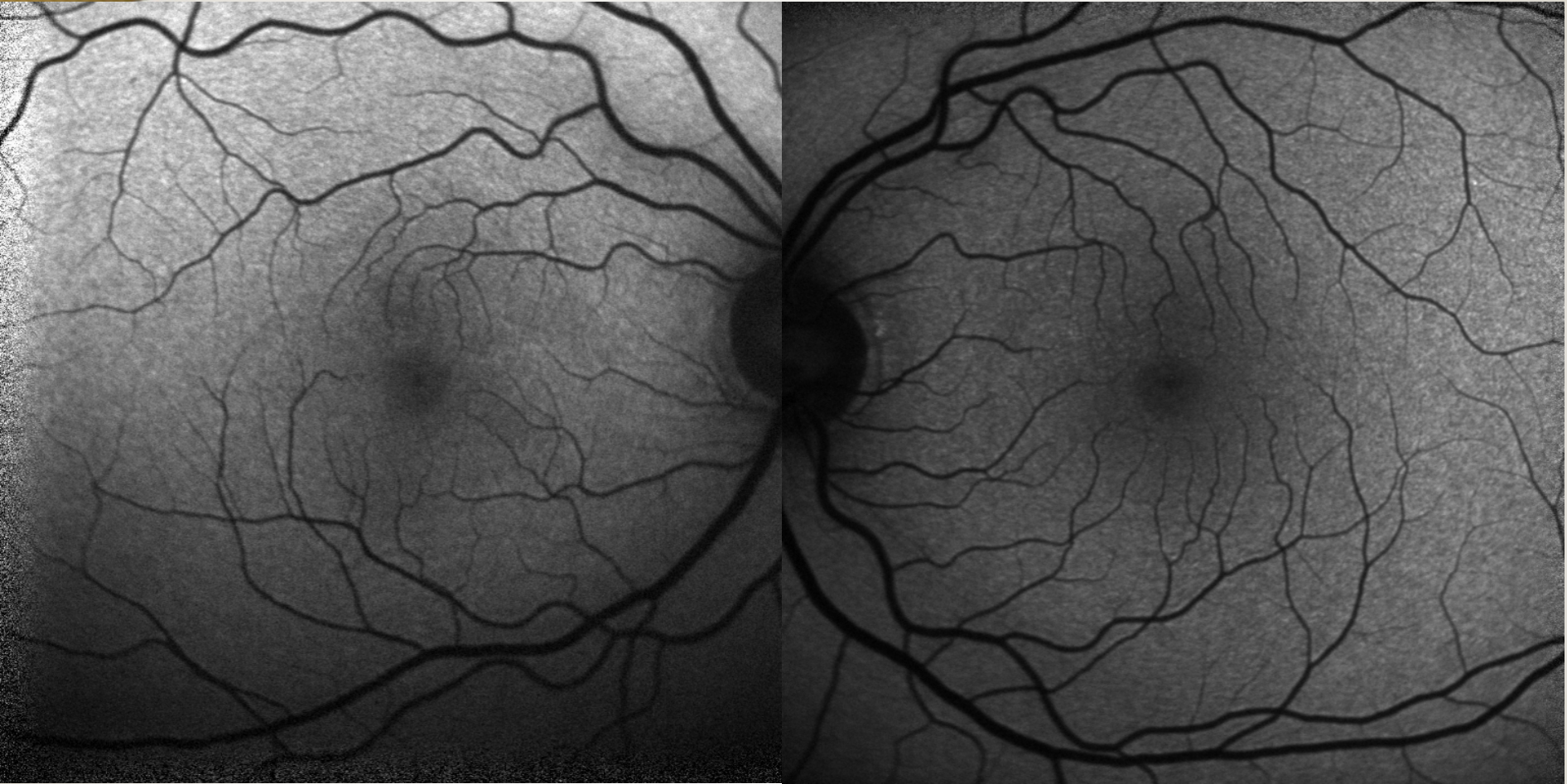





VANDERBILT UNIVERSITY
MEDICAL CENTER

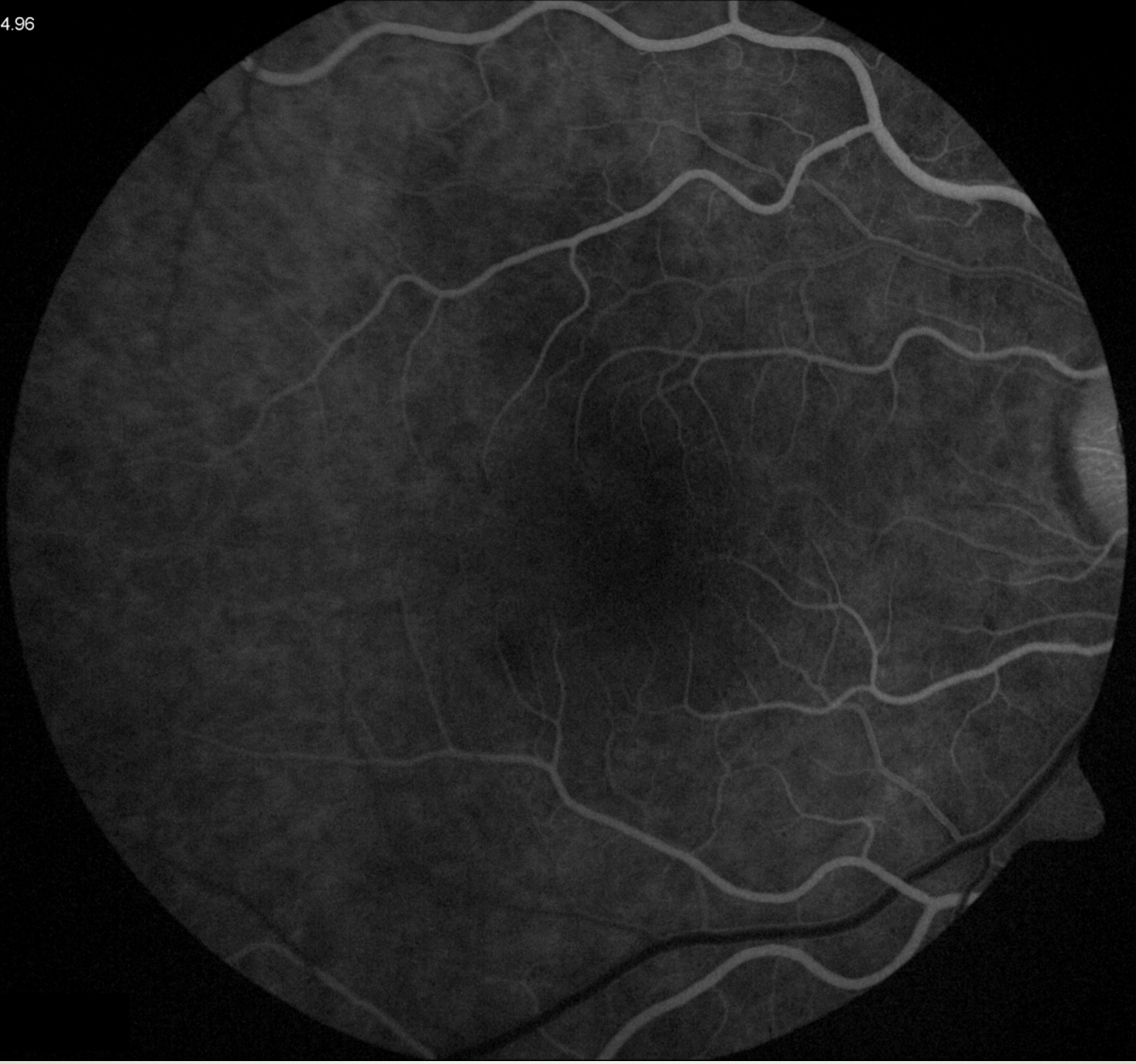Fundus Autofluorescence



Vanderbilt Eye Institute

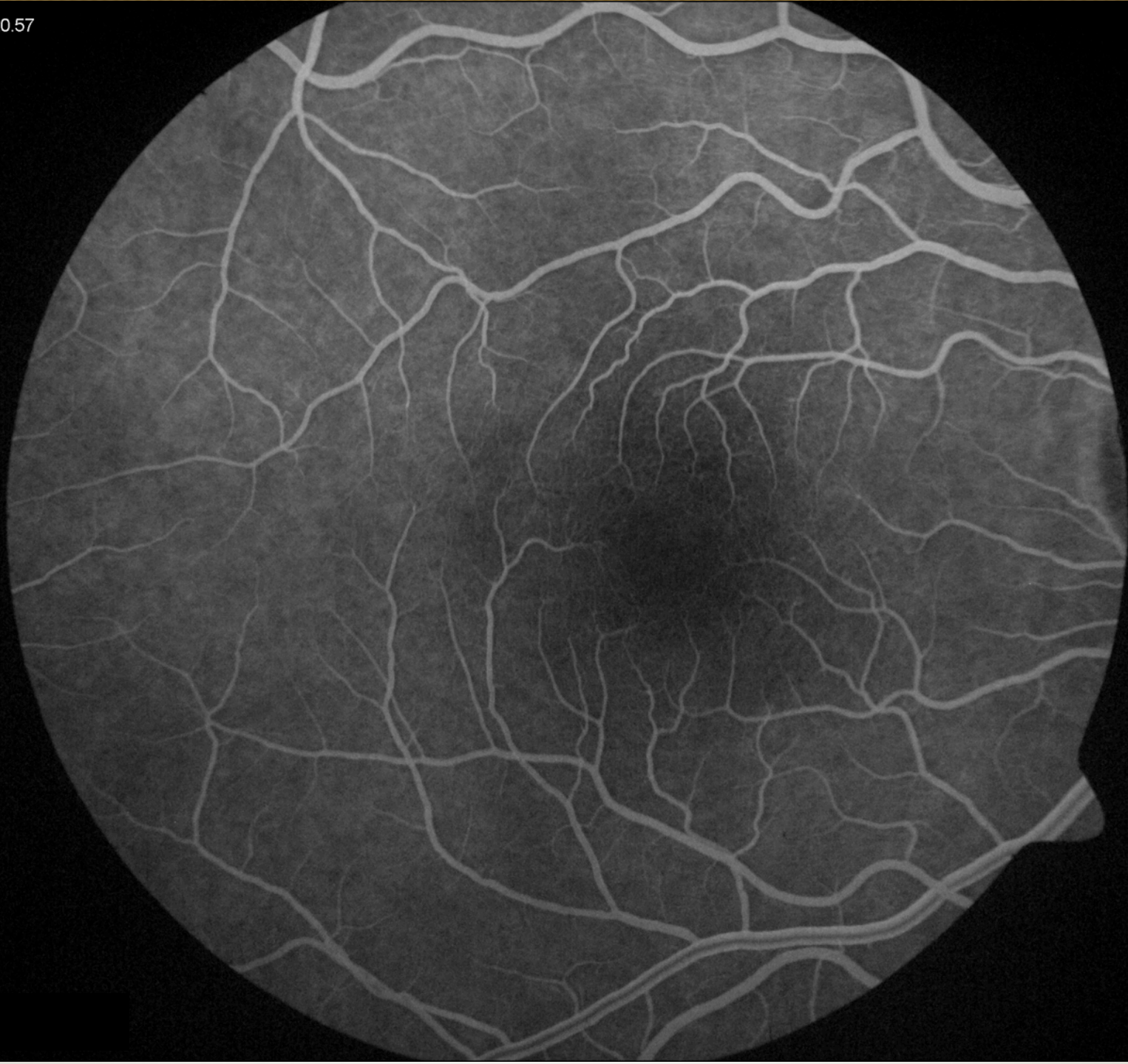
00:14.96

VANDE
MEDI



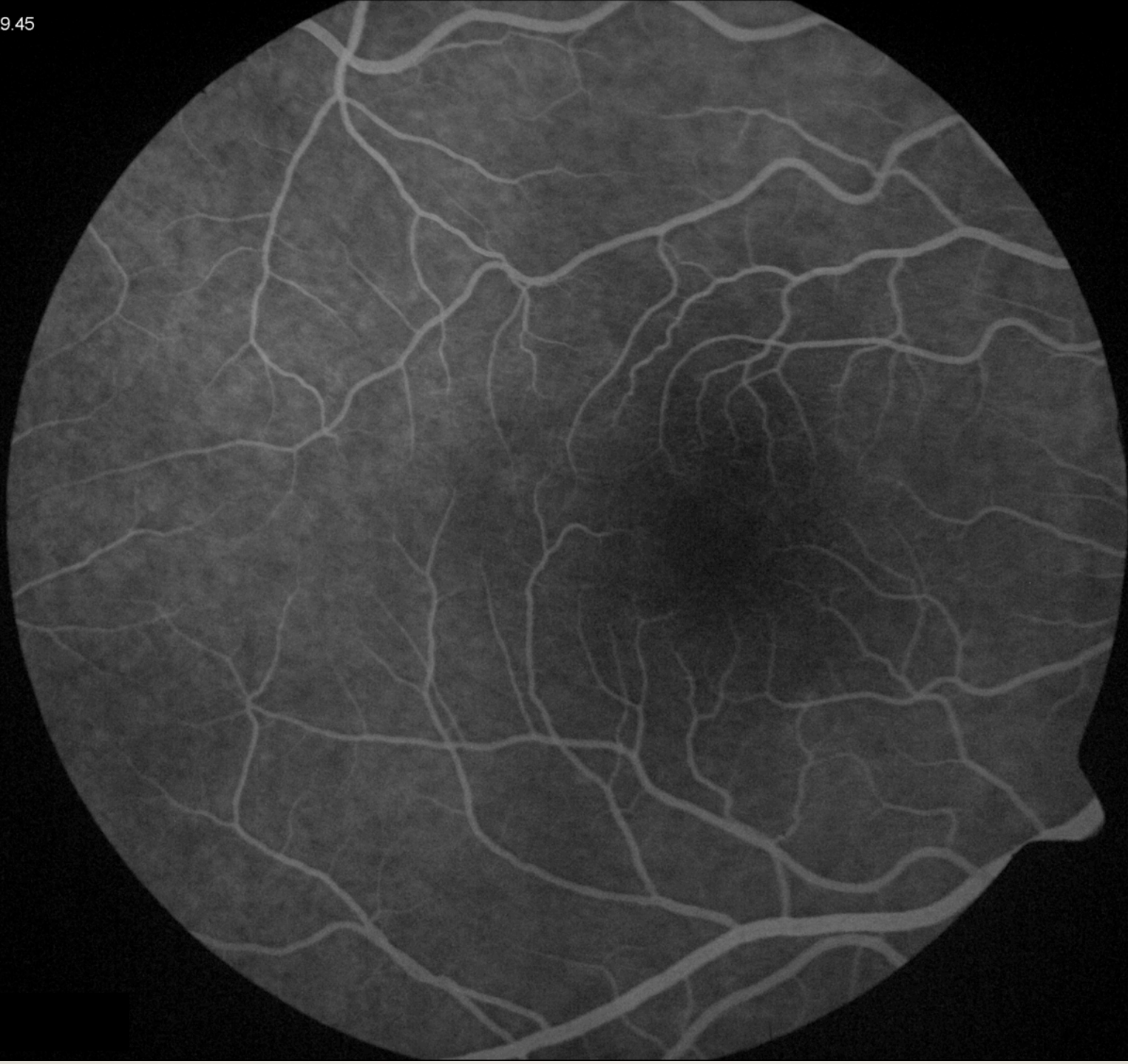
00:20.57

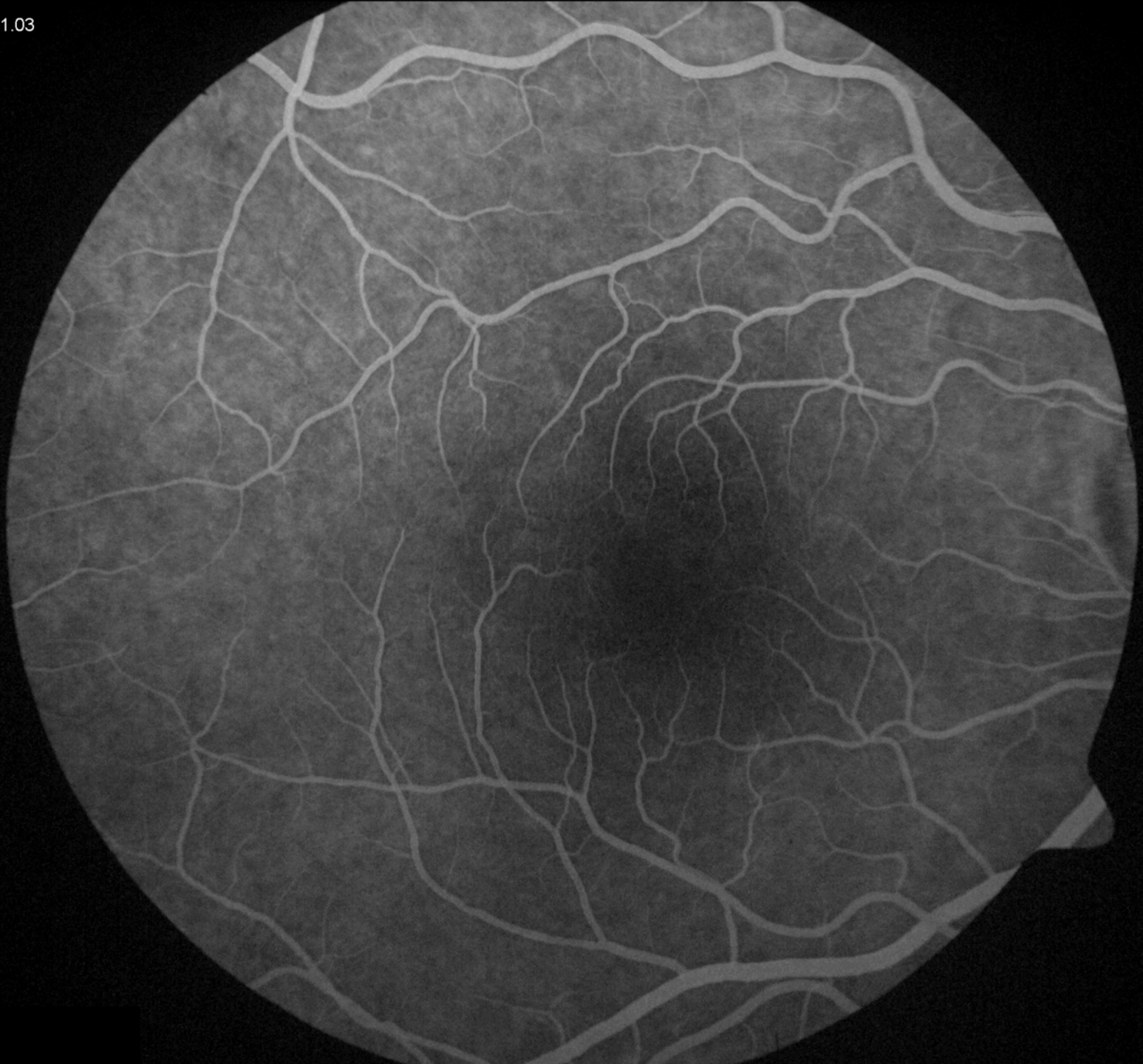
VANDE
MEDI



00:29.45

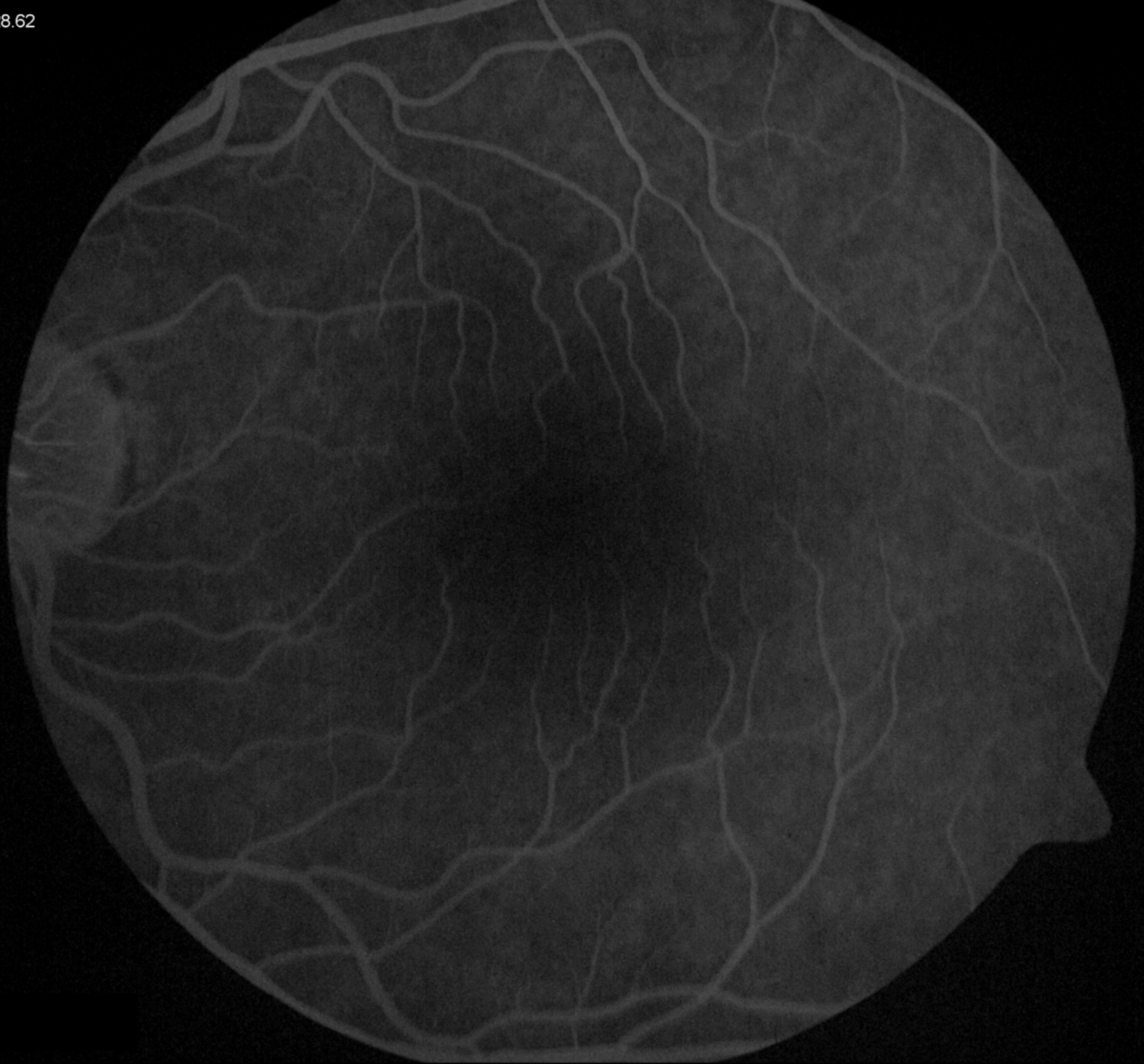VANDE
MEDI





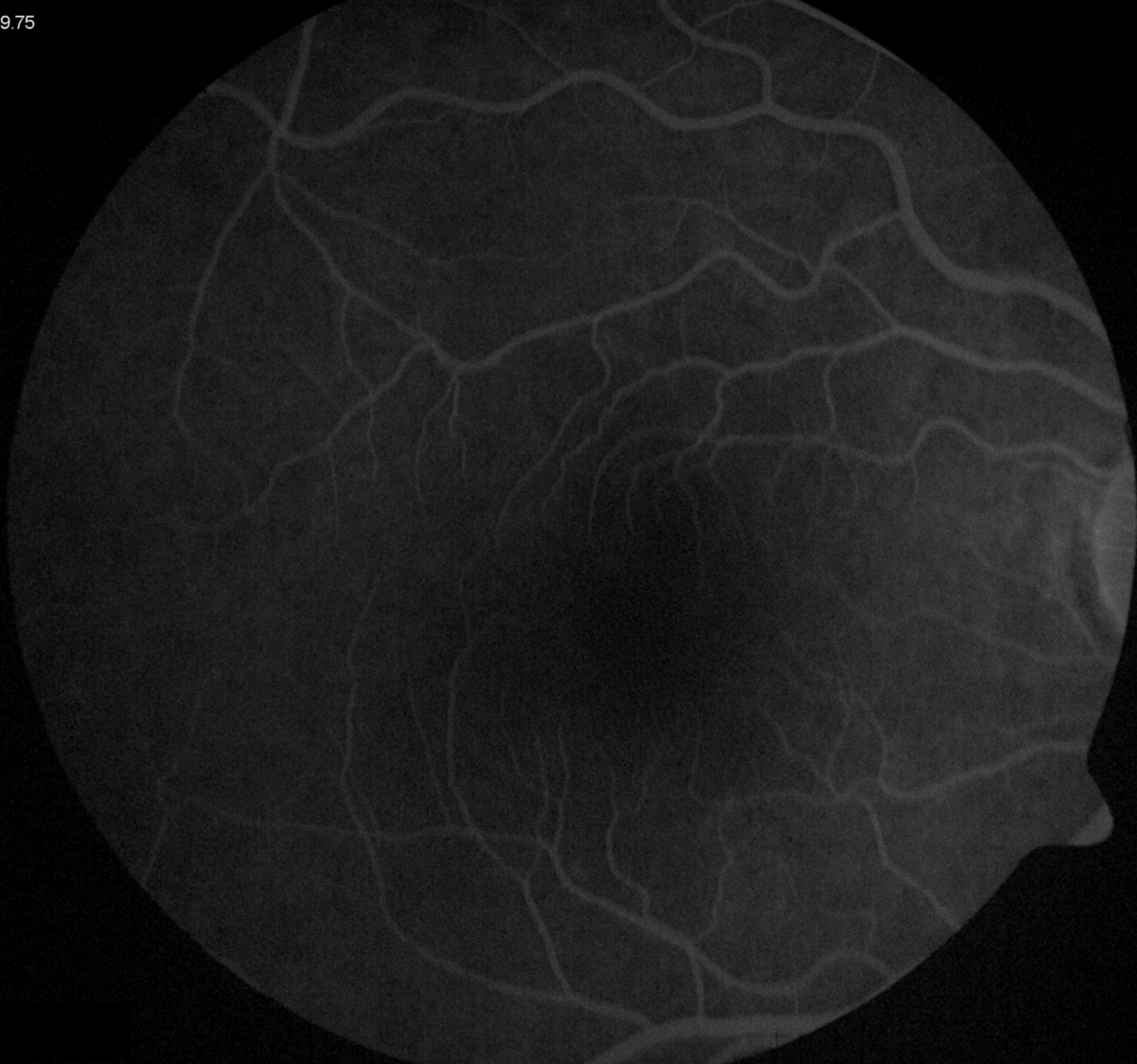02:28.62

VANDE
MED



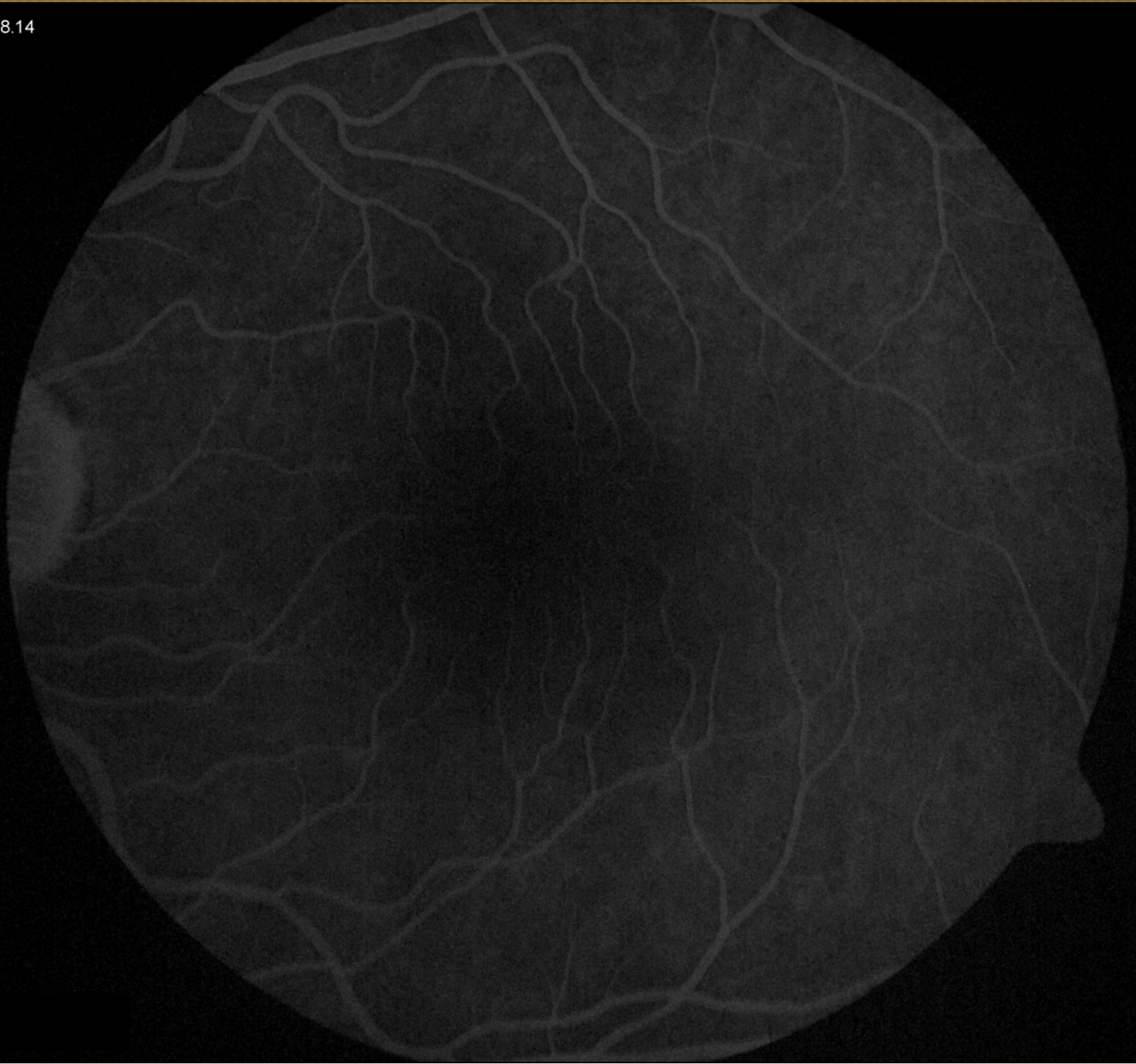
04:39.75

VANDE
MEDI



05:18.14

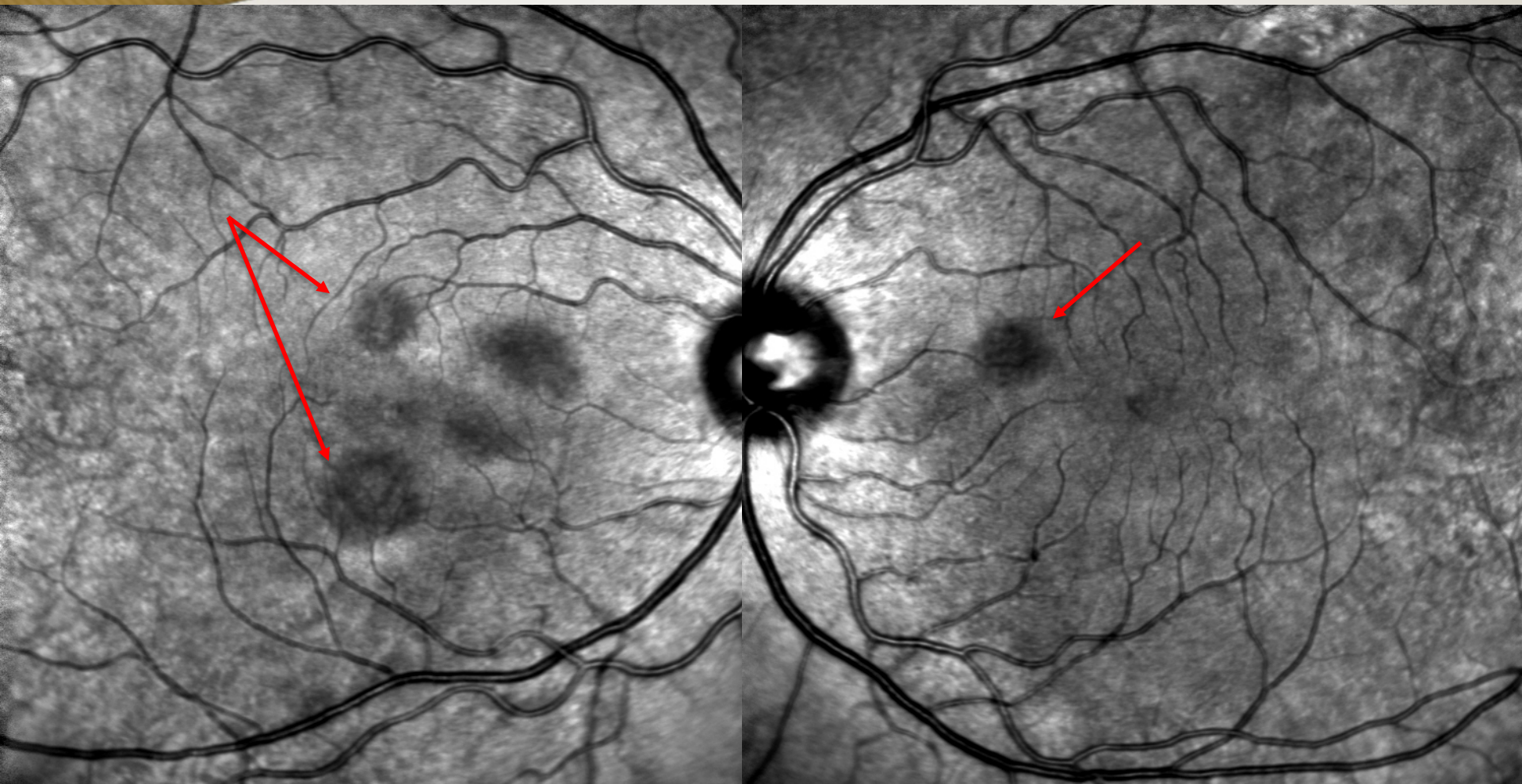
VANDE
MEDI



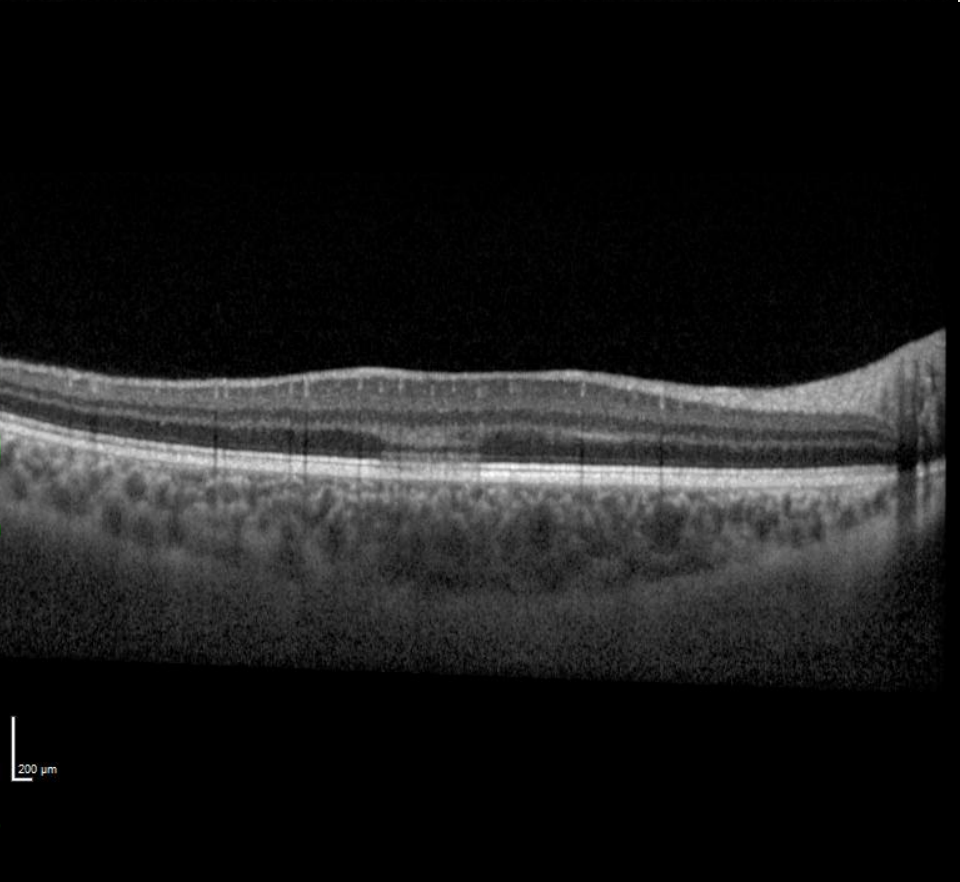
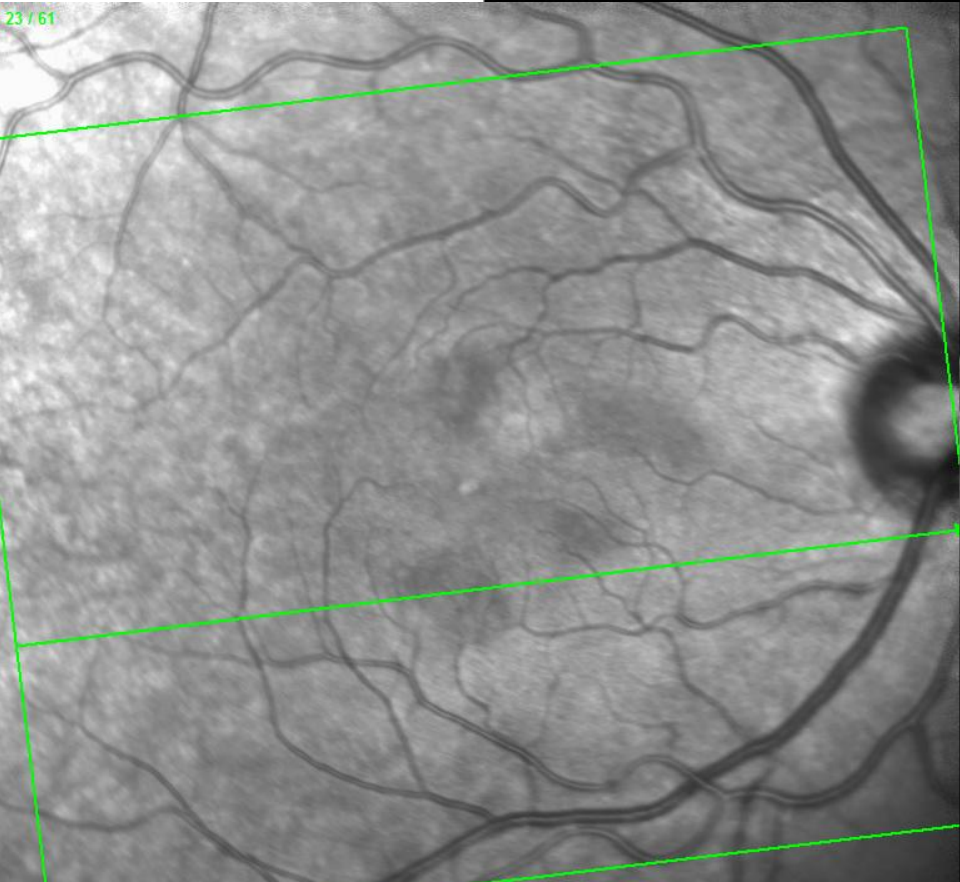
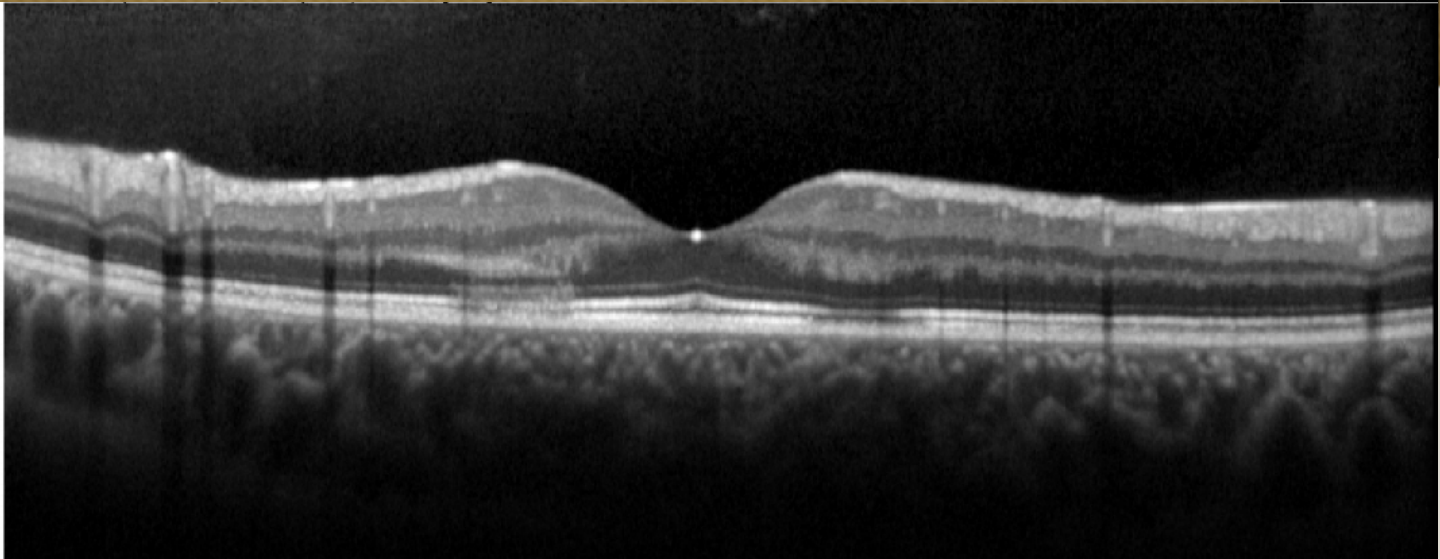
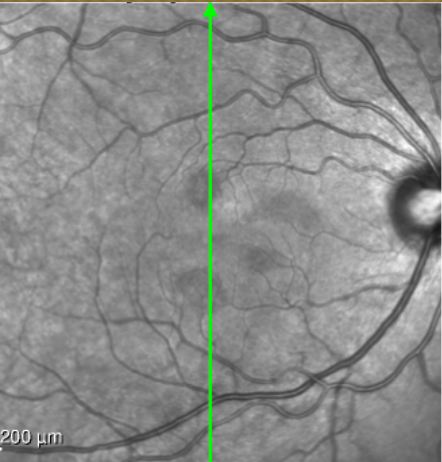


VANDERBILT UNIVERSITY
MEDICAL CENTER

Infrared

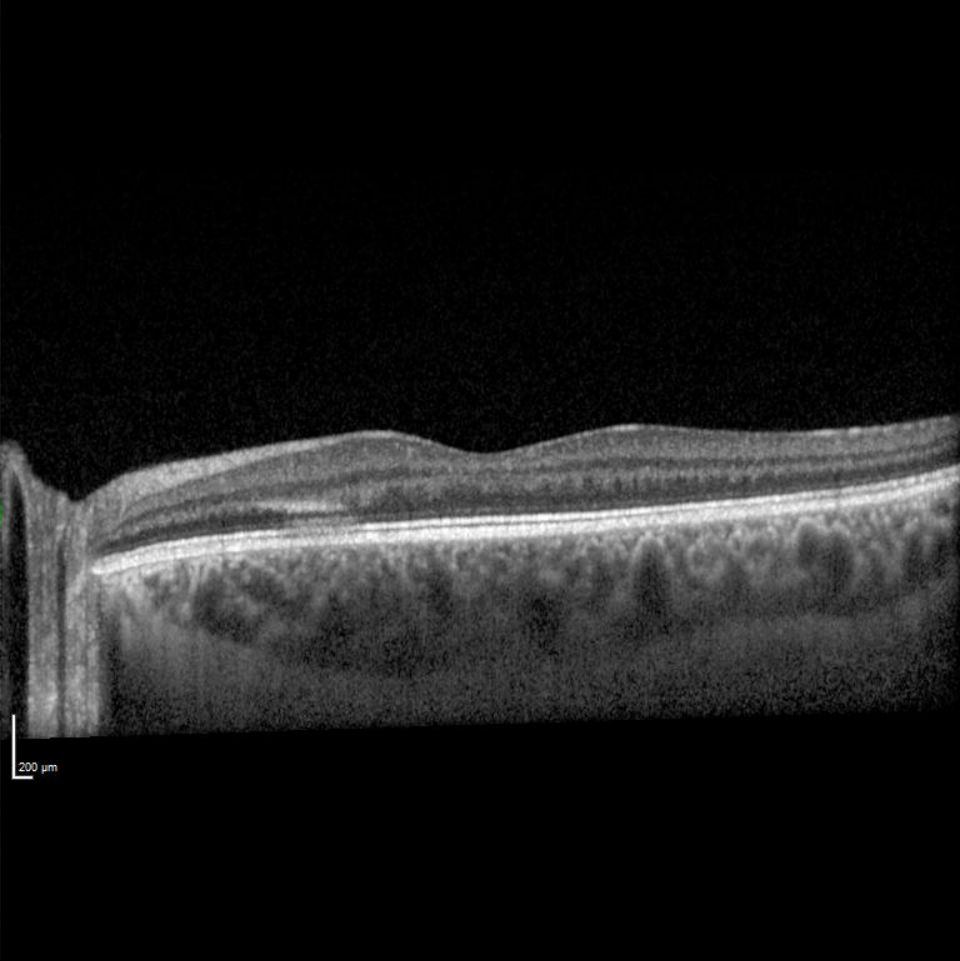
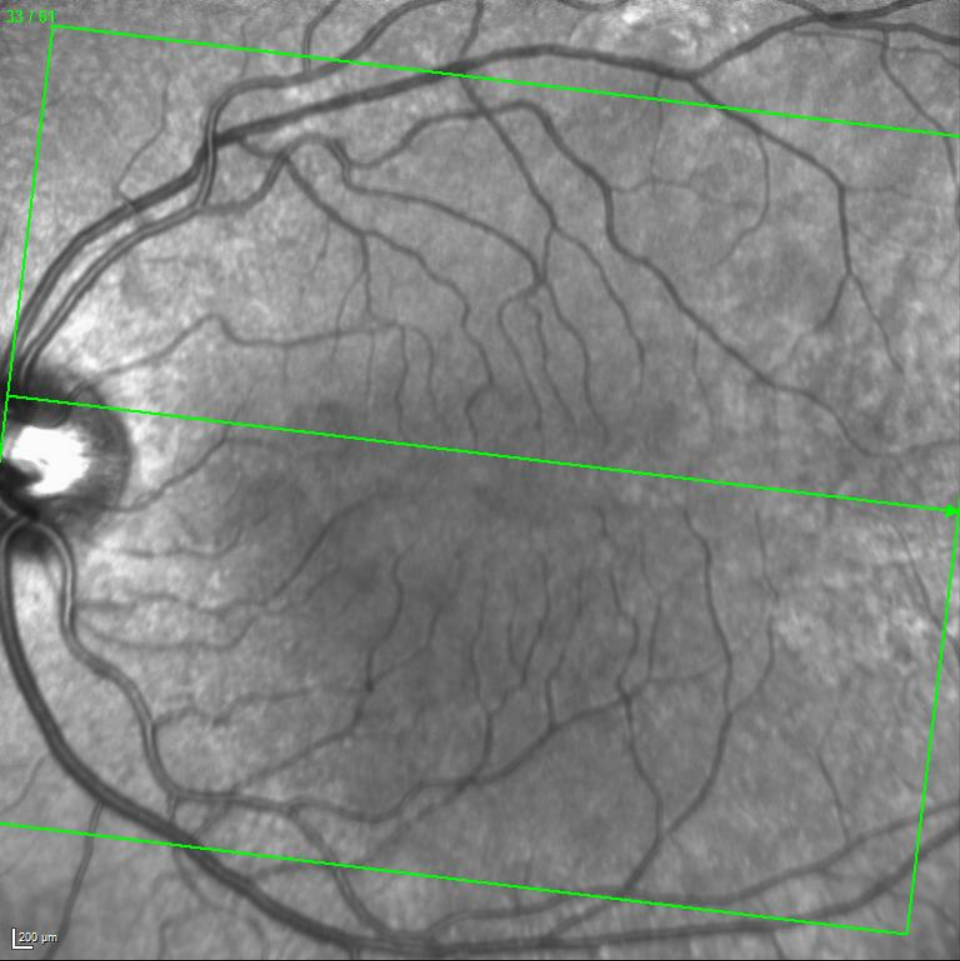

Vanderbilt Eye Institute





VANDERBILT UNIVERSITY
MEDICAL CENTER



Vanderbilt Eye Institute



Course

- Diagnosis: Acute macular neuroretinopathy
- Observation x 4 weeks
- On follow-up, patient reporting significant improvement in symptoms