

Approach to Abdominal Incisional Hernias

Richard Davis

Background:

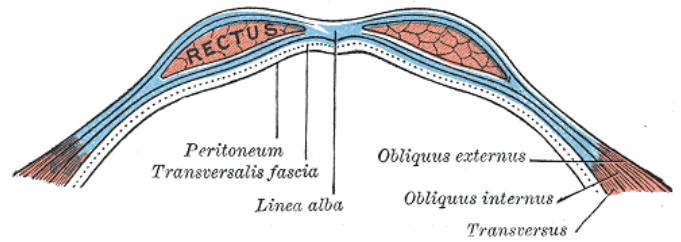
Incisional hernias can arise after up to 25% of midline laparotomy incisions. Risk factors include emergency surgery, wound infection, smoking, obesity, and uncontrolled diabetes. Other less tangible risk factors include surgical technique and patient factors such as collagen formation; there is a known association between arterial aneurysmal disease and postoperative hernias. Incisional hernias can range from asymptomatic to painfully debilitating; most are bothersome and painful to the patient because of the associated bulge on Valsalva or on standing or coughing. In larger hernias, retraction of the lateral abdominal wall muscles leads to lack of trunk support and chronic low back pain. Especially large hernias can lead to

Incarcerated incisional hernias can be chronically or acutely incarcerated; acutely incarcerated ones represent a surgical emergency. Otherwise, unincarcerated or chronically incarcerated hernias can be repaired on an elective basis, which allows the clinician and patient to agree on risks and benefits of repair, as well as to address controllable risk factors.

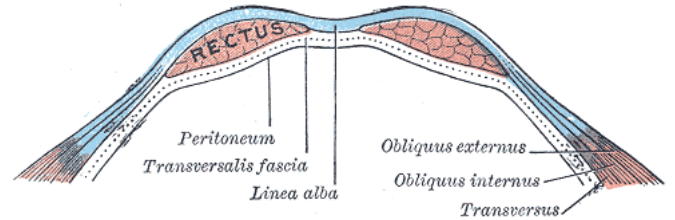
Patients should stop smoking for 4 to 8 weeks before surgery, and HbA1c should be well below 8. The wound should be completely free of contamination or infection. Situations where this is not possible are discussed further below. It is extremely difficult for obese people with incisional hernias to lose weight because of exercise limitations placed by the hernia itself.

In-depth counseling is in order for the patient with prohibitive risk factors, including a very high Body Mass Index or severe cardiac or pulmonary disease. Surgery may be delayed or deferred in such patients. Special attention should be paid, in large hernias, to the possibility of loss of domain. In this condition, a large hernia has been present for so long that the visceral cavity no longer has the size to accommodate return of all abdominal contents after repair of the hernia. Returning the contents of the hernia to the abdominal cavity, if that is even possible, will lead to respiratory embarrassment, excessive tension on the repair, and even abdominal compartment syndrome.

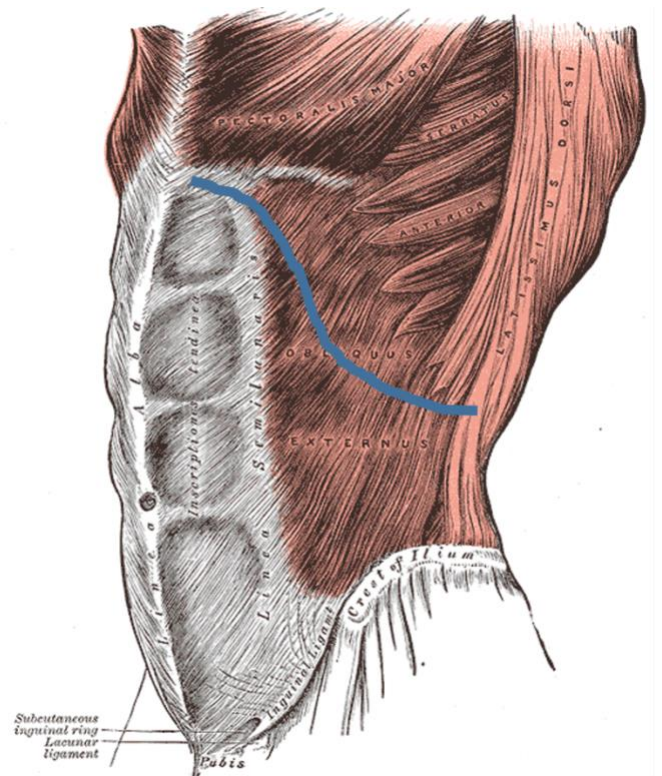
Anatomy:



The arcuate line is a horizontal line located 2-5cm below the umbilicus. Above this line, the rectus muscle is surrounded by fascia both anteriorly and posteriorly.



Below the arcuate line, there is no fascia posterior to the rectus muscle. There is only peritoneum and a layer of thin fatty tissue called the transversalis fascia. This layer is sufficient to protect the bowels from mesh, but is not strong enough to constitute one of the layers in a non-mesh hernia repair.



The fibers of the external oblique muscle run transversely, from superolateral to inferomedial, originating in part above the costal margin (blue line.)

Approach to Abdominal Incisional Hernias

Richard Davis

The fibers of the transversus abdominis run horizontally. The innervation of the anterior and lateral abdominal wall runs between the internal oblique and the transversus abdominis.

Principles:

In incisional hernia, the muscles of the lateral abdominal wall are no longer attached in the midline; they retract and become chronically short in length. At the time of repair, it is not advisable to simply re-approximate them; this approach will fail >50% of the time due to excessive tension.

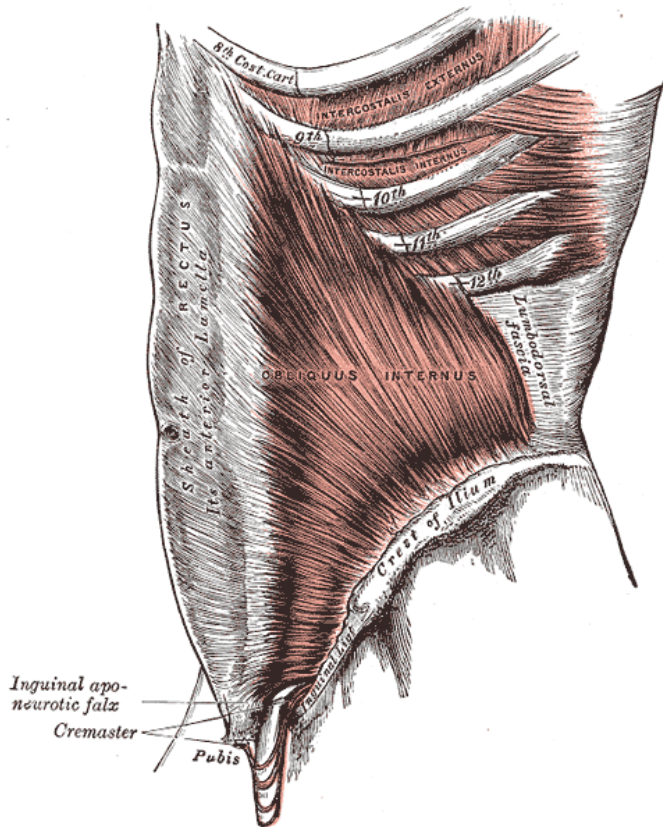
Any incisional hernia, no matter the size, represents a failure in wound healing at the site. Often the fascia at the site is attenuated, worsening the problem. In these situations, it is necessary to incise the shortened muscles, or to place a prosthetic mesh, or ideally to do both. Closure of a wound with mesh distributes the tension of the wound across a larger area than simple closure.

Placement of a mesh increases the risk of complications, which is acceptable because of the decrease in risk of recurrence. The surgeon must take precautions to minimize the risk of mesh complications, the most notable of which is mesh infection. Another well-known complication, chronic neuropathic pain, is much less common in incisional hernia repair compared to inguinal hernia repair. Chronic pain after incisional hernia repair is best avoided by not securing the mesh with tight “encircling” sutures within muscle or fascia, as these have the potential to entrap parietal nerves.

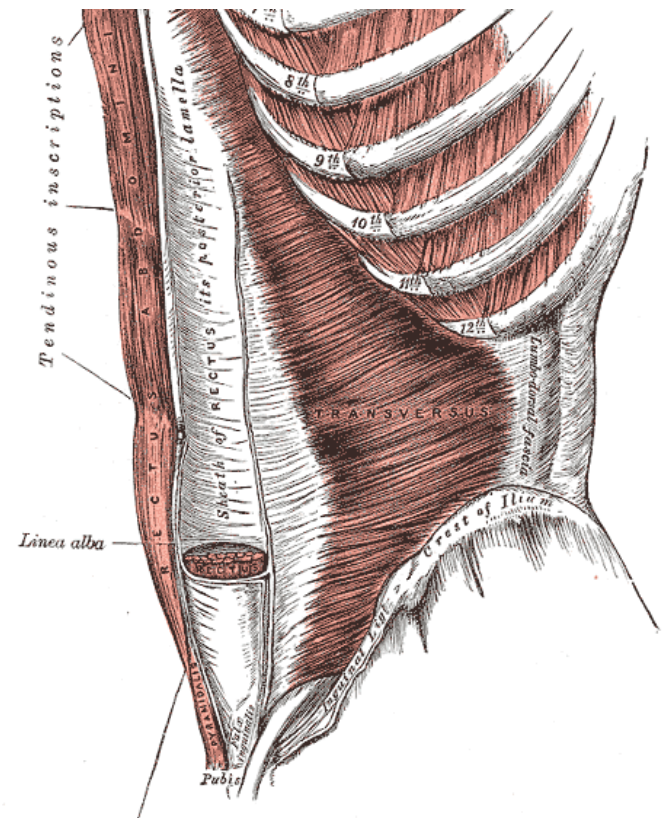
The most commonly available mesh in resource-limited settings will be plain polypropylene (“Nylon”) mesh. This is classified as “Light” and “Heavy.” Light mesh will be more flexible, soft, and comfortable to the patient after implantation; this comes at a cost of slightly higher risk of hernia recurrence.

Polypropylene mesh may be delivered sterile from the manufacturer, or it can be sterilized with ethylene oxide. It can also be sterilized in a steam autoclave that is functioning properly. See the [Sterilization](#) chapter for further details.

If you have high contamination of your operating room with dust or flying insects, you will have to decide whether the risk of mesh implant is higher than the risk of hernia recurrence. If you feel that the risk of infection is unacceptably high, the component separation technique described in this Atlas can be used without mesh placement.

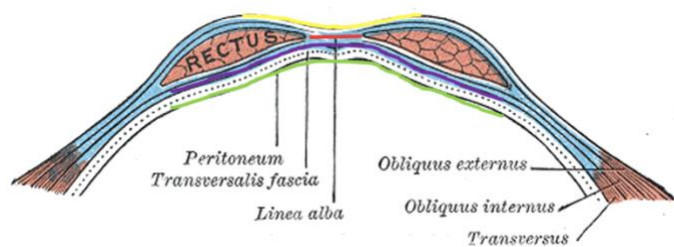


The fibers of the internal oblique muscle run perpendicular to the external oblique, transversely from inferolateral to superomedial.



Approach to Abdominal Incisional Hernias

Richard Davis



Positions of mesh placement.

Onlay (Yellow): Mesh is placed by clearing off the anterior rectus sheath, closing the defect primarily, and securing the mesh.

Inlay (Red): Mesh is used to bridge a defect that cannot be closed; the mesh is sutured to the edges of the fascia.

Sublay (Purple): Mesh is placed in between the rectus muscle and the posterior rectus sheath. Also known as Retro-rectus placement, or the Rives-Stoppa technique.

Underlay (Green): Mesh is placed within the peritoneal cavity, in contact with bowel. Also known as Intraperitoneal Onlay Mesh, IPOM. Most frequently performed at laparoscopy, using special mesh that can be in contact with bowel (See Box, “Resource-Rich Settings.”)

Mesh should definitely be avoided in situations where:

- The mesh will come in contact with any body fluids such as urine, bile, or bowel contents, either during or after the repair.
- There is any infection at all in the operative field, including cellulitis.
- There is possibility of contact with any bowel (exceptions as per box, “Resource-Rich Settings.”)
- There has been any entry into a hollow viscus, even controlled (cholecystectomy, hysterectomy, bowel resection.)

Decision Making:

Regarding mesh placement, the farther away the mesh can be placed from the skin, the safer it will be from infection. This will be best accomplished by placing the mesh deep to the abdominal wall muscles. If plain polypropylene mesh is being used, however, it is not acceptable to place this mesh in contact with the bowel. Strategies include:

- In a patient with ample omentum, simply place the mesh in an Underlay position and assure that the omentum lies between it and the intestines. Suture the omentum to the peritoneum around the mesh, especially if using a large mesh.
- Dissect the space between the peritoneum and the posterior rectus sheath and place the mesh in this space. Preserving the hernia sac helps provide coverage of the mesh at the midline when this strategy is used. The plane between the posterior rectus sheath is very difficult to develop, the Sublay position is much easier to accomplish.
- Place the mesh in the Sublay position, by dissecting the posterior rectus sheath off of the rectus muscle, as described in the Chapter, “Hernia Repair with Sublay (Retro-Rectus) Mesh Placement.”

All of these solutions require significant dissection and entry into the abdominal cavity, but they do offer the most durable and safest repair. Conversely, the most appropriate use of the Onlay mesh position is in the patient who is not able to tolerate a large operation, or in whom the hernia is small enough to not warrant a large operation. The fascia should be closed and then the mesh laid on top of the repair.

Choice of repair type, from the options in this Section, will be dictated by the size of the hernia.

- Hernia Repair with Onlay Mesh Placement is best reserved for small hernias. Examples include recurrent umbilical or epigastric hernias, hernias involving only a few cm of a midline incision, or laparoscopic port site hernias.
- Larger midline incisional hernias, up to about 5cm wide, can be repaired with the Underlay (Retro-Rectus) Technique; the fascial edges can usually be drawn to the midline without component separation, and the closure will be relatively secure when reinforced by mesh.
- Midline incisional hernias that are wider than about 5cm are unlikely to close, and stay closed, with the Retro-Rectus technique alone. The hernia repair described in the Anterior Components Separation chapter is the best one for these. If no contraindication to mesh placement exists, this should be done as well.

Approach to Abdominal Incisional Hernias

Richard Davis

The surgeon should be prepared for situations where a large hernia exists and a mesh cannot be placed. These might be anticipated, as when an incisional hernia or fascial dehiscence coexists with an enterocutaneous fistula or intra-abdominal abscess. Or they may be unplanned, such as bowel injury and spillage of succus during elective or emergency incisional hernia repair. The surgeon must have a well-rehearsed “Plan B” at the ready. Options include temporary abdominal closure (discussed elsewhere in this Atlas,) closure of the skin only, or components separation repair.

- In some cases the best approach is closure of skin and subcutaneous tissue only, leaving the hernia repair for a later time. This is the best approach when gross infection is present; likely the primary goal of the surgery was to deal with the source of infection or contamination. If this goal has been accomplished, there is no shame in leaving a complex hernia repair operation for a time when it will be safer and more likely to succeed.
- In other cases, “Plan B” will include a complete tissue repair of the hernia using the Anterior Components Separation technique described in this section. This approach is most suitable for elective hernia repair in which there is no infection, but an inadvertent enterotomy has been made and repaired, or a clean-contaminated procedure was done.

If one is faced with a large incisional hernia and gross contamination or infection, in no case should one attempt to pull the fascia together under tension and “hope for the best.” This will invariably lead to wound dehiscence, which puts the patient at risk for evisceration, incarceration of bowel in the defect, or damage to the fascia, which will make future repairs more difficult.

Resource-Rich Settings

These mesh products allow the surgeon to break some of the rules that apply to plain polypropylene mesh. They are much more expensive, however.

- Polytetrafluoroethylene (PTFE, Gore-Tex®) mesh is smooth enough that it can be placed in contact with bowel without consequence. Mesh intended for intra-abdominal use may have one smooth and one rough side; the rough side is meant to be placed against the abdominal wall and allow tissue ingrowth.
- Polypropylene coated in a biologic membrane, such as porcine dermal extracellular matrix, can be placed in direct contact with bowel. Often these will also be side-specific, with one rough side more likely to promote ingrowth into the abdominal wall.
- Absorbable mesh, such as Polyglycolic acid (Vicryl®) can be placed in the presence of contamination, though it will break down quickly in the presence of infection. This material is not useful in repairing any abdominal wall hernias.
- Acellular dermal matrix mesh is an animal collagen matrix that has had all cellular material removed. This mesh can be used in any position; it is often used as an “inlay” material to bridge a defect between two edges of fascia in the presence of infection. This mesh will always break down eventually, so if used to bridge a defect it will lead to recurrence of the hernia. It is most often used to “bail out” of a situation where a hernia coexists with contamination or infection.

Richard Davis, MD FACS FCS(ECSA)
AIC Kijabe Hospital
Kenya

January 2022

