

Peripartum Hysterectomy

Camille Robinson, Lindsey E. Zamora

Editor's Note: Non-Obstetricians in resource-limited settings should be prepared to do this operation with little warning- usually the first time you see a peripartum hysterectomy, you will be the one performing the surgery. If possible, scrub on elective hysterectomies with a specialist. As described here, the cervix is left in place (especially if done by an inexperienced surgeon), unlike elective hysterectomy.

Introduction:

Peripartum hysterectomy is a unique surgery that occurs when a hysterectomy is indicated after a birth has occurred, either via vaginal or Cesarean route. It is often called “Cesarean hysterectomy” if it occurs after a Cesarean birth. In some rare cases, the hysterectomy is planned. More often, it is a surgical emergency that becomes necessary after the delivery has occurred. While Cesarean deliveries are one of the most common major surgeries worldwide, it is estimated that less than 1% of all Cesarean deliveries end in hysterectomy.

The most common *planned* indication for a Cesarean hysterectomy is placenta accreta spectrum. In this scenario, the placenta is abnormally attached to the uterus. Often the safest mode of action is to deliver the baby then remove the uterus and placenta together. The most common *unplanned* reason for a peripartum hysterectomy is uncontrolled hemorrhage, such as with refractory uterine atony, uterine rupture or an extension of the hysterotomy into uterine vessels.

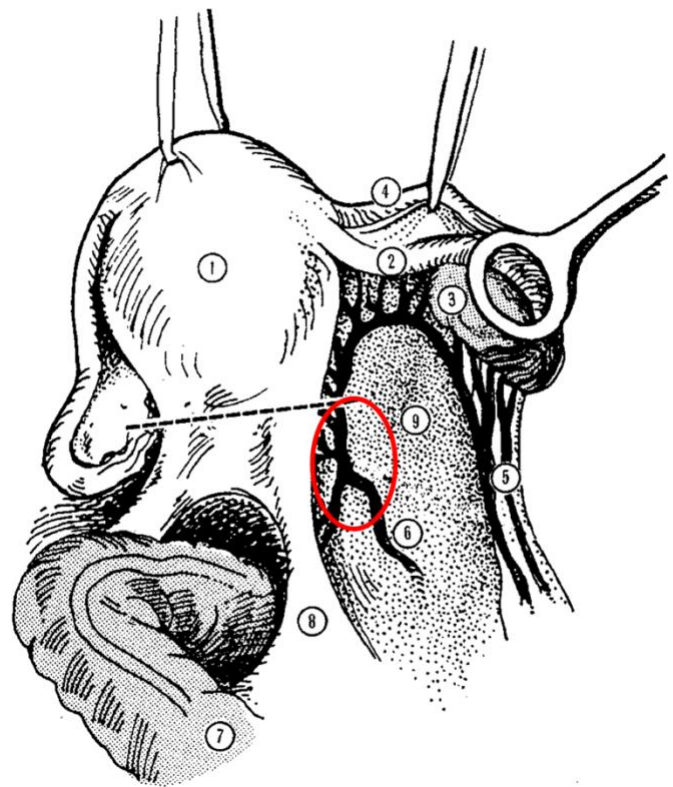
The most common indications for peripartum hysterectomy include:

- Uncontrolled hemorrhage
- Uterine rupture that cannot be repaired
- Placenta accreta spectrum

The steps of a peripartum hysterectomy are slightly different depending on the indication for the surgery. For example, how we approach the procedure for placenta accreta spectrum is different than for an unexpected hemorrhage. Here, we describe the steps for an *unplanned* peripartum supracervical hysterectomy, that would be performed because of postpartum hemorrhage due to

atony, uterine rupture, or unexpected placenta accreta. Again, most peripartum hysterectomies should be supracervical, as this variant can be performed faster and with less risk of damaging the urinary tract.

Any planned Cesarean hysterectomy (due to known placenta accreta spectrum) should ideally be transferred to a facility with Obstetricians or General Surgeons and blood transfusion capabilities in advance of the planned surgery.



Anatomy for peripartum hysterectomy, viewed from cranial to the uterus, looking towards the pelvis. (Note that the photos in this chapter are viewed from caudal to the uterus looking cranially, in effect showing the “opposite side” from this view.) The uterus is lifted towards the left and the adnexa (ovary and fallopian tube) have been lifted upwards. The dotted line represents the level of the cervix, which is palpable as a thickening below the body of the uterus. The ureters are vulnerable to injury if any sutures are placed below the level of the cervix, within the Red circle. Structures: 1.) Body of the uterus 2.) Right Fallopian tube 3.) Ovary 4.) Round ligament 5.) Ovarian vessels running in the infundibulo-pelvic ligament- this is the blood supply to the ovary. 6.) Uterine vessels 7.) Rectum 8.) Sacrouterine ligament 9.) Avascular area of Broad ligament. Source: Primary Surgery Volume 1, <https://global-help.org/products/primary-surgery/>

OPEN MANUAL OF SURGERY IN RESOURCE-LIMITED SETTINGS

www.vumc.org/global-surgical-atlas

This work is licensed under a [Creative Commons Attribution-ShareAlike 3.0 Unported License](https://creativecommons.org/licenses/by-sa/3.0/)



Peripartum Hysterectomy

Camille Robinson, Lindsey E. Zamora

Steps:

If Cesarean is the mode of delivery, for more detail on the steps for a Cesarean birth including variations on delivery technique please see [Cesarean birth](#). We also describe here various techniques to treat hemorrhage and potentially avoid removal of the uterus.

1. After the birth of the baby, via vaginal route or Cesarean, if significant bleeding occurs that cannot be stopped with uterine massage and use of uterotonics, and is deemed to be due to uterine atony, all uterotonics available at the facility should be exhausted as a first line measure. This includes oxytocin (Pitocin), methylergonovine (Methergine), carboprost tromethamine (Hemabate), and misoprostol (Cytotec). Tranexamic Acid is a fibrinolytic which can be used to supplement the use of uterotonics and reduce total blood loss. Also assure that that retained products of conception are not contributing to the bleeding- all products of conception, such as fragments of the placenta, must be evacuated.
2. At this stage, it is important to notify anesthesia of blood loss and consider administration of blood products. In addition, adequate IV access should be re-assessed at this point. If available, a second surgeon should be called to help.
3. If atony is not resolved with medical treatment, an intrauterine balloon catheter can be placed. If successful, placement of a balloon for treatment of uterine atony can negate the need for surgical treatment including a peripartum hysterectomy and salvage the patient's uterus. Commonly used compression balloons are the treatment of uterine atony are Bakari balloons or multiple Foley balloons inflated to their maximum capacity. If intrauterine balloon catheters are utilized, it is important to also place a Foley catheter in the bladder to drain urine as the urethra will often be obstructed by the compression balloon.
4. If it is determined that hemostasis cannot be achieved with conservative management

(medications and/or balloon tamponade), proceed with surgical management.

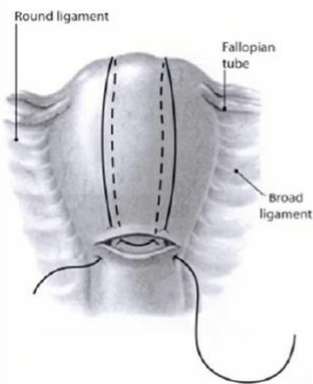
5. If surgical management is chosen after a vaginal delivery, the following steps should be taken to prepare (these would already have been taken if the delivery is a Cesarean):
 - Administer prophylactic antibiotics. Ideal preoperative antibiotics are a first-generation cephalosporin (e.g. cefazolin 1g IV for patients 80 kg, 2-3g IV for patients > 80 kg) administered in the hour prior to surgery.
 - Place a urinary catheter.
 - Consider thromboembolism prophylaxis. If available, pneumatic compression devices should be placed.
 - Prepare and drape the abdomen and pelvis. Abdomen should be prepared with surgical solution typically used in the facility. Vaginal preparation should be performed as well to help reduce the risk of postoperative infection. This should ideally be performed with 4% chlorhexidine gluconate vaginal scrub but povidone-iodine is an acceptable, slightly less effective alternative.
 - Place the patient in supine position; her legs may have been in stirrups previously. This improves your surgical access and decreases the risk of deep venous thrombosis.
 - Perform a laparotomy; if the delivery was a vaginal delivery, performing a midline vertical incision is the best choice to provide excellent exposure for the treatment of hemorrhage. If Cesarean was performed, the incision from the Cesarean delivery can be utilized.
6. **If significant blood loss has already occurred, the surgeon may choose to move directly to a peripartum hysterectomy to avoid ongoing bleeding and delay in treatment. If a hysterectomy is chosen as the next step, please move to Step 8.**
7. If the cause of the ongoing bleeding is uterine atony and there is adequate time to attempt other surgical measures prior to a hysterectomy, placement of a B-lynch compression suture can be attempted to treat the atony and avoid a



Peripartum Hysterectomy

Camille Robinson, Lindsey E. Zamora

peripartum hysterectomy. This is placed using the following steps after a laparotomy:



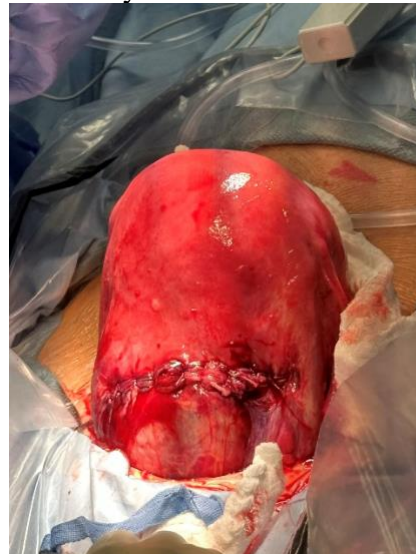The B-Lynch compression suture is placed as above, using one continuous slowly absorbable suture. If there is a hysterotomy, as from previous Cesarean birth, the suture closes it. If there was no hysterotomy, the suture is placed as shown in the place where the hysterotomy would have been. Uterus with completed and tied compression suture is shown on the Right. Source: Garofalo M and Posner GD, DOI 10.7759/cureus.2725

A large needle should be used with delayed absorbable suture:

- The suture is first placed across the hysterotomy (or where a hysterotomy would be if a vaginal delivery was performed) overlapping the hysterotomy by 3cm above and below it, as shown above.
- The suture is then looped around the uterine fundus and placed in a lateral fashion on the contralateral (cranial) side of the uterus at the same level as the hysterotomy, through the entire thickness of the posterior uterine myometrium.
- After exiting, the suture is looped back around the fundus and pulled very tightly on the uterus. If an assistant is available, they should “roll” the uterine fundus which is often floppy and atonic to a tightly rolled position while the surgeon pulls the compression suture tightly to provide compression.
- Finally the suture is placed across the hysterotomy, about 3 cm above and below, and the two ends of the suture tied together.

If the above measures have not resolved bleeding, proceed with a peripartum hysterectomy with the following steps:

8. Assess exposure with the current abdominal incision. Often the initial incision made for the Cesarean is sufficient, but if it is not, do not waste time attempting this lifesaving surgery through an inadequate incision. If the transversely-oriented incision does not give sufficient exposure, make another incision vertically in the midline, meeting the previous incision in the shape of an inverted “T”.
9. Pack away the bowel with moist laparotomy sponges. The uterus should then be placed on cephalad traction in order to obtain adequate exposure either with manual traction, or with strong clamps on the utero-ovarian ligaments bilaterally.

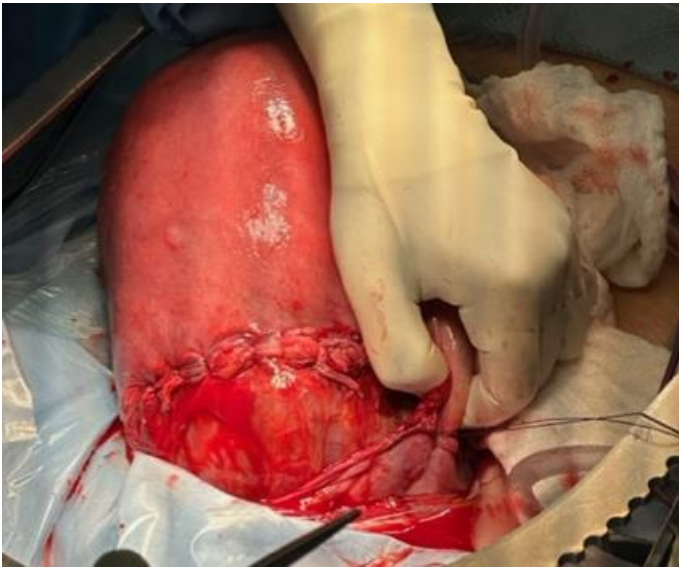


The uterus is exteriorized and the hysterotomy quickly closed if a Cesarean was the mode of delivery.

10. The round ligament should be doubly clamped lateral to the uterus. Each pedicle should be ligated with a slowly absorbable suture (such as Vicryl). It is then transected to provide access to the anterior leaf of the broad ligament. The broad ligament is caudal to the utero-ovarian ligaments, and will be visible as you pull cranially on the the Utero-Ovarian ligaments (or the clamps you applied to them in Step 9). There is an avascular plane beneath the round ligament that is quite distinct from the broad ligament itself, which runs beneath the Fallopian tube.

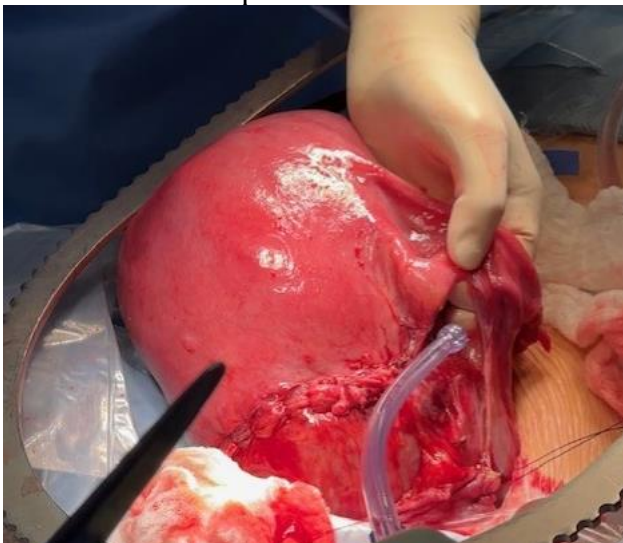
Peripartum Hysterectomy

Camille Robinson, Lindsey E. Zamora

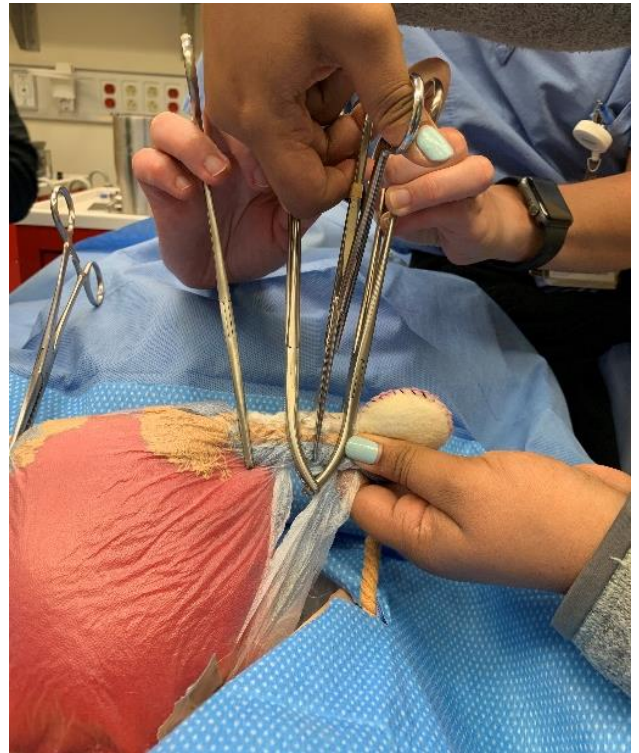


The left round ligament is isolated and suture ligated after creating a window in an avascular space beneath it

11. Create a “window” lateral to the uterus and beneath the utero-ovarian ligament and fallopian tube in an avascular space. The window can be made sharply by cutting with mayo scissors or bluntly after confirming the area is avascular. The window should be large enough to then place two strong clamps as shown below. This area is quite vascular during pregnancy so take care to find an avascular space for the window.



The left utero-ovarian ligament and fallopian tube are isolated and beneath them a finger is placed in the avascular plane to make the window lateral to the uterus.

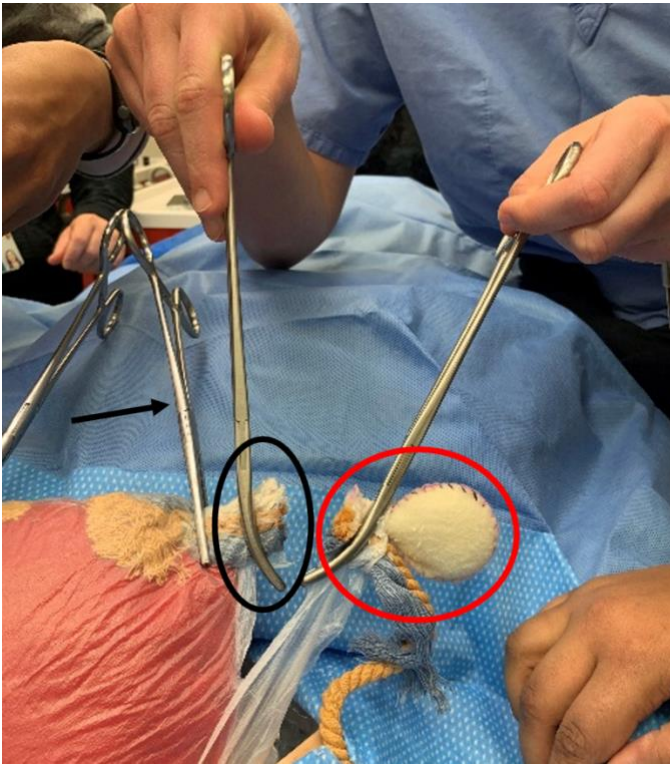

As shown in this hysterectomy model, the left utero-ovarian ligament and fallopian tube are doubly clamped at the site of the window and cut.

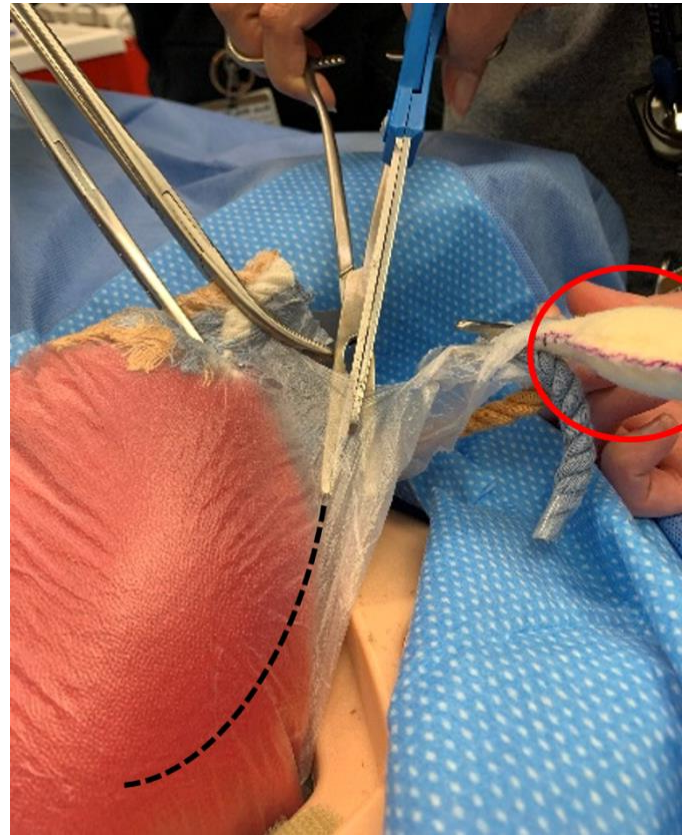
12. The surgeon should then cut between the clamps and leave the clamp on the uterus in place for the remainder of the surgery. The distal clamp holding fallopian tube and utero-ovarian ligament should be doubly suture ligated with delayed absorbable suture. Again, the medial clamp stays to be removed later with the entire specimen.

Peripartum Hysterectomy

Camille Robinson, Lindsey E. Zamora

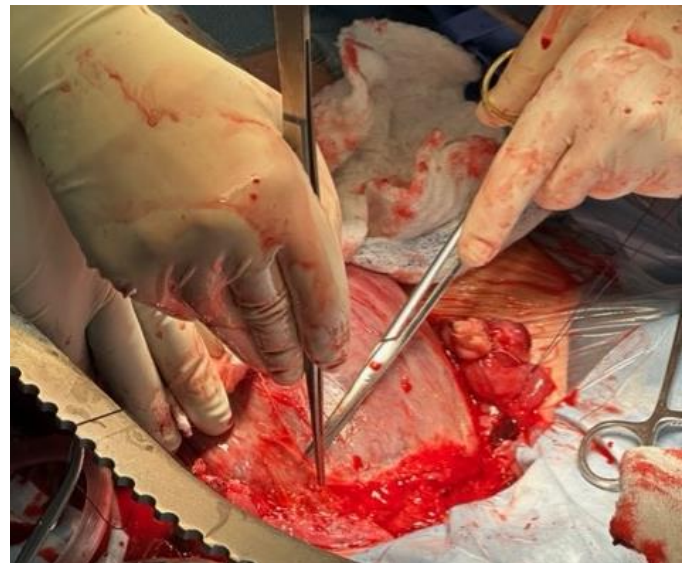

The incised left utero-ovarian ligament and fallopian tube. The clamp in the Black circle should be left in place for the rest of the operation. The tissue inside the clamp in the Red circle should be suture ligated, preserving the blood supply of the ovary (also within the Red circle), which comes in lateral to this area through the infundibulopelvic ligament. The clamp shown by the Black arrow, can still be used for traction throughout the case.



Use a clamp to elevate the anterior leaf of the left broad ligament and incise it with diathermy or with scissors if diathermy is not available. A similar incision from the right side will meet this one at the midline.

13. The anterior leaf of the broad ligament should then be incised to reflect the bladder off of the lower uterine segment. This can be achieved by gently placing the distal portion of the ligated round ligament on traction laterally and dissecting the anterior broad ligament bilaterally, meeting in the center of the uterus to develop the plane between the uterus and the bladder. *This is very important in order to avoid ureteral injury and properly ligate the uterine vessels.* Once the plane has been developed from both sides, the bladder should be dissected inferiorly. This can be done either bluntly or with Metzenbaum scissors, to the level of the internal cervical os in the same avascular plane.

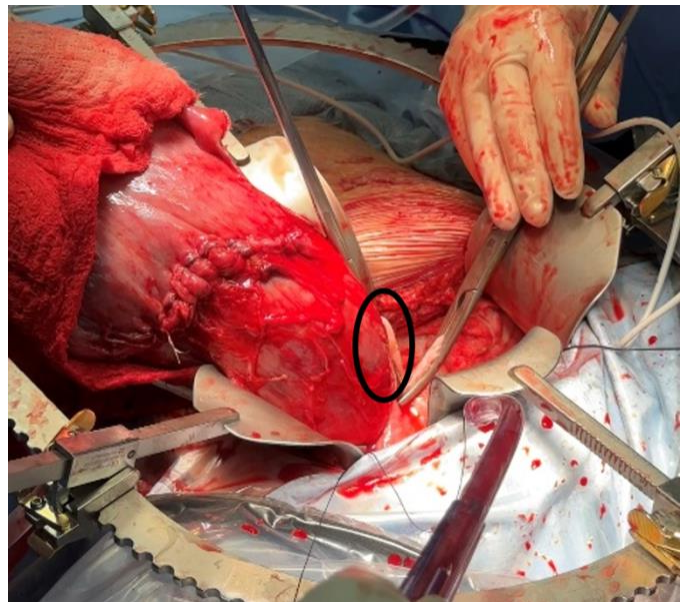
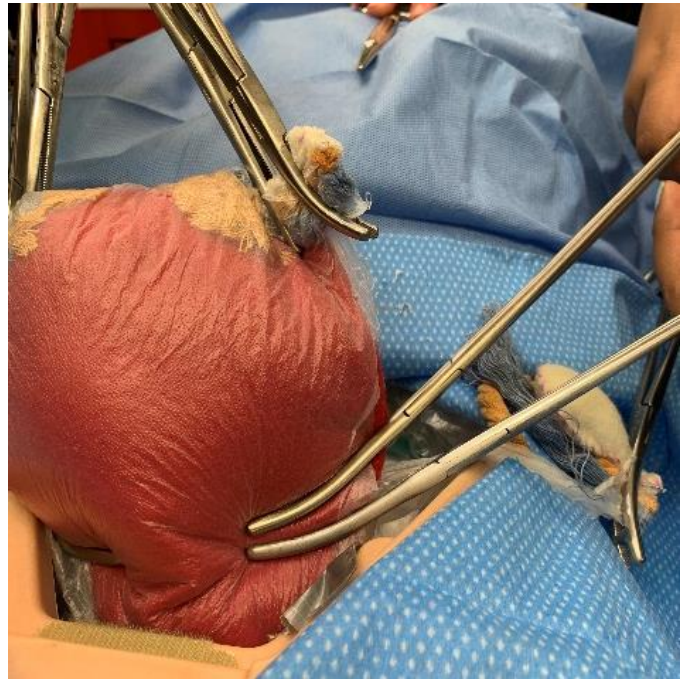


Once the plane has been developed from both sides, the bladder is dissected inferiorly below the level of the interior cervical os using diathermy or sharp dissection.

Peripartum Hysterectomy

Camille Robinson, Lindsey E. Zamora

14. The posterior leaf of the broad ligament should be undermined to ensure it is away from any blood vessels, then incised caudad towards the uterosacral ligaments. This helps to further protect the ureters from injury when ligating the uterine vessels.
15. The bladder flap should be rechecked prior to ligating the uterine vessels to ensure that it has been dissected *at least below the level of the internal cervical os*. Dissection of the bladder flap can be done using smooth forceps and Metzenbaum scissors.
16. Prepare to ligate the uterine vessels by placing the uterus on traction opposite the side of planned ligation. The arterial pulsation should be palpated and identified then doubly clamped, adjacent to the uterus and above the level of the bladder flap—ideally at the level of the upper cervix. Take care not to place clamps deeper than the level of the cervix to avoid injuring the ureter. Use two clamps and apply them to form a “v” and touch at their tips to avoid vessels coming loose. The clamp that is cephalad helps with bleeding and will remain with the specimen. *It is very important not to remove the cephalad clamp; removal will result in significant “back bleeding.”*
17. Mayo scissors are used to cut in between the two clamps, ideally leaving a small pedicle on each side. **The uterine vessels are very large during pregnancy and the utmost care needs to be taken in their ligation.** The cephalad (superficial) clamp again remains with the specimen and should *not* be removed or significant bleeding will occur. The pedicle in the caudal (deep) clamp is suture-ligated with 0-Vicryl suture by placing a suture at the very tip of the clamp to ensure the entire pedicle is ligated. If needed, a second suture can be placed.

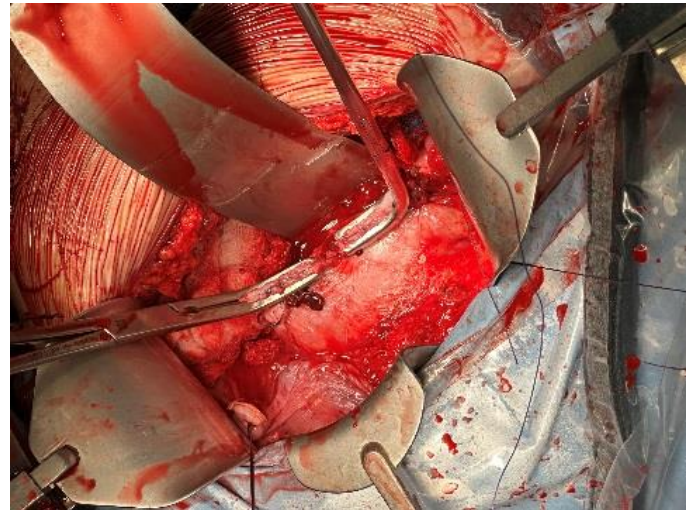
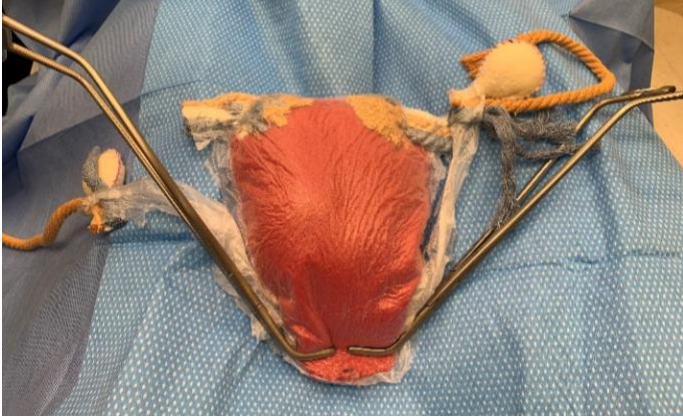


Two clamps placed across the uterine artery forming a “V” and cut in-between with Mayo scissors. The top picture shows a simulation model, and bottom picture shows the same step of uterine artery transection. Note that the tips of the clamps close on the adjacent broad ligament, not the uterus itself. The clamp within the Black circle should not be removed. The tissue within the clamp below that one should be carefully suture-ligated, passing the needle just next to the tip of the clamp and not going deeper than the level of the cervix to avoid injury to the ureter.

Peripartum Hysterectomy

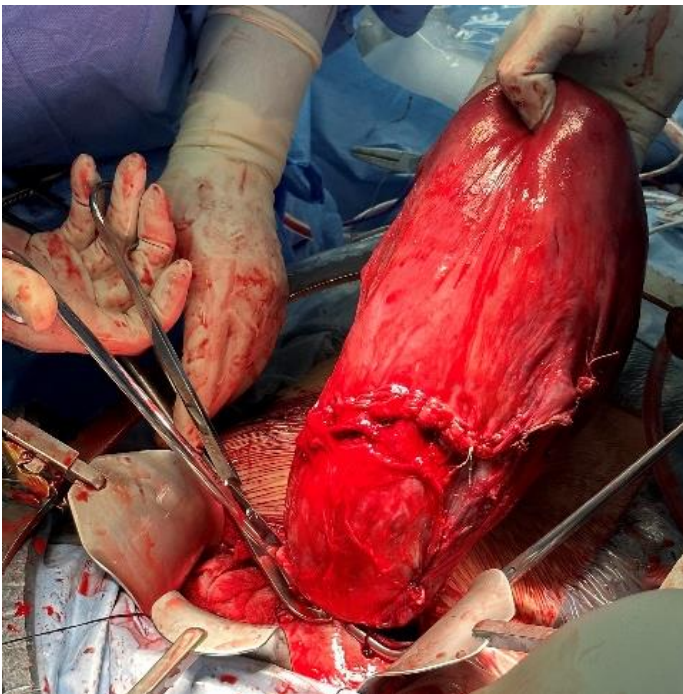Camille Robinson, Lindsey E. Zamora

18. Once these steps have been performed on one side, they should all be repeated on the opposite side of the uterus.
19. After bilateral uterine arteries are ligated, two sturdy curved clamps should be placed across the uterine body/upper cervix at the same level of the uterine artery ligation and using heavy scissors, or diathermy, the uterus amputated at (not below!) the level of the uterine artery ligation.

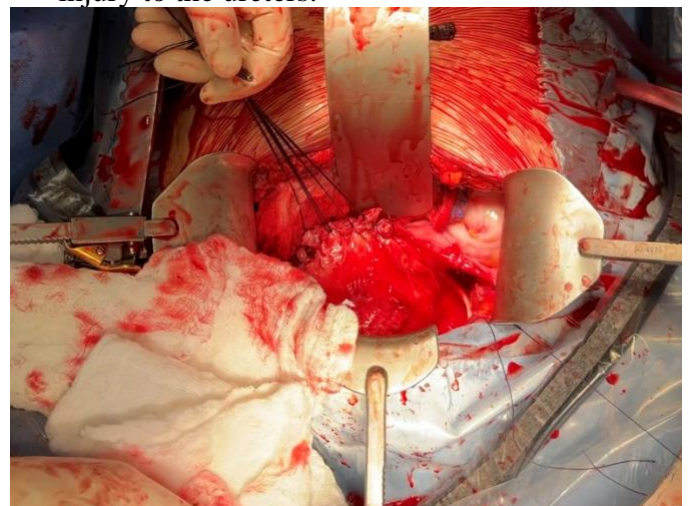


The clamps remain in place after the uterus has been incised and removed.

20. The upper cervix can then be closed by placing a transfixion suture as each clamp is removed. Interrupted figure-eight sutures can then be placed in an anterior to posterior fashion to approximate the middle portion of the remaining tissue. Alternatively, the length of the opening can be closed in a running locked fashion below the clamp with 0-Vicryl. During closure, take care not to suture more laterally than the uterine artery ligation, as this can cause bleeding and/or injury to the ureters.



The above two figures show two curved clamps placed across the uterus, superior to the cervix, after division of the uterine arteries bilaterally..



This figure shows a completely closed uterus after removal of the clamp. The sutures are typically left long until the entire cuff is closed to assist with retraction.

21. A systematic survey should be performed to assess for ongoing bleeding. Irrigate the pelvis

Peripartum Hysterectomy

Camille Robinson, Lindsey E. Zamora

with warm normal saline solution, as underwater bleeding is more visible to the surgeon.

22. Once it has been ensured that there is no ongoing bleeding, the abdomen can be closed in a standard fashion.

Pitfalls

- Ovarian ischemia: As Cesarean hysterectomy is typically being done emergently, if care is not taken to identify the utero-ovarian ligament properly, it is possible to mistakenly ligate the infundibulopelvic ligament, lateral to the ovary. This will lead to loss of the ovaries and subsequent premature menopause. Thus, it is very important to identify the utero-ovarian ligament correctly during steps 11 and 12.
- The most common complications of Cesarean hysterectomy are significant blood loss and urinary tract damage. These complications are higher when the procedure is being performed emergently. The procedure is associated with substantial bleeding, especially when the indication for surgery is uncontrolled hemorrhage. The physiology of pregnancy makes the vessels that supply the uterus larger and more tortuous. Edema makes it more difficult to identify tissue planes. Hematomas, uterine rupture, and long labor can cause distortion of anatomy which make a cesarean hysterectomy more difficult and risky.
- In cases of hemorrhage with high volume blood loss, pay close attention to vital signs and urine output to ensure adequate resuscitation with IV fluids and blood products. Coagulopathies may present prior to the procedure or as the surgery progresses.
- Urinary Tract Damage: The most common location of bladder injury is the dome, especially if the patient has had a previous Cesarean birth. Urinary tract damage is identified by cystoscopy or by retrograde instillation of fluid through a foley catheter into the bladder, either sterile milk or methylene blue. Methylene blue or sodium fluorescein, each as a single 50mg dose, can be given IV as well. Injury to the uterers is a risk during peripartum hysterectomy as well, an if

there is concern for this, cystoscopy should be performed looking for bilateral efflux from both ureters. Briefly, close a bladder injury in 2-3 layers using running technique and a 3-0 absorbable or delayed absorbable suture such as Vicryl. First, the mucosa is closed followed by the muscularis and serosal layers. If an injury to the urinary tract is identified, a Foley catheter should remain in place postoperatively for 14 days to allow for continuous urine drainage and allow for adequate healing and prevent fistula formation. If you are able to perform a cystogram, using this study to confirm no leakage allows you to remove the catheter sooner, sometimes as early as 7 days. See also the chapter [Approach to Ureteral Injuries](#).

- As stated previously, the cervix is typically left in place during a Cesarean hysterectomy. The cause of bleeding is typically addressed by removing the uterine body. Removal of the cervix is associated with significantly higher rates of injury to the urinary tract and should only be attempted if there is significant ongoing bleeding after removal of the uterine body, as in a deep cervical tear extending into the uterus itself. If you must remove the cervix, identify the ureters through visualization in the retroperitoneum. Try to avoid dissection into the retroperitoneum as this can lead to significant bleeding, particularly in a patient who may be coagulopathic. Tissue lateral to the cervix should be suture ligated immediately lateral to the cervix as the ureters can lie very close to the cervix after labor, leading to high risk of damage. Clamps should then be placed directly under the cervix. Then, the vaginal vault is suture ligated after removal of the cervix as described above.

Camille Robinson, MD
Vanderbilt University Medical Center
Tennessee, USA

Lindsey E. Zamora, MD, MPH
Vanderbilt University Medical Center
Tennessee, USA

OPEN MANUAL OF SURGERY IN RESOURCE-LIMITED SETTINGS

www.vumc.org/global-surgical-atlas

This work is licensed under a [Creative Commons Attribution-ShareAlike 3.0 Unported License](#)



Peripartum Hysterectomy

Camille Robinson, Lindsey E. Zamora

July 2023

OPEN MANUAL OF SURGERY IN RESOURCE-LIMITED SETTINGS

www.vumc.org/global-surgical-atlas

This work is licensed under a [Creative Commons Attribution-ShareAlike 3.0 Unported License](https://creativecommons.org/licenses/by-sa/3.0/)

