

# Cesarean Birth

Lindsey E. Zamora, Annelise Long

## Introduction:

Cesarean birth is an operation that will likely be necessary in any setting where childbirth occurs. The clinician must consider the risks versus benefits for the mother and the infant given the resources available for each in the setting of care. Risks to the mother in the short term (infections, thromboembolism, surgical risk, death) and in the long term (risk of uterine rupture in subsequent pregnancies, risk of abnormal placentation in future pregnancies) should be weighed carefully against potential benefits to the mother and infant in making the decision to proceed with Cesarean birth.

Indications for Cesarean birth are the following:

- Maternal hemorrhage
- Fetal-pelvic disproportion with abnormal progression of labor
- Uterine rupture
- Fetal malpresentation that cannot be resolved with rotation
- Nonreassuring fetal status
- Umbilical cord prolapse
- Mechanical obstruction to vaginal birth (e.g. fibroids)
- Previous Cesarean deliveries\*

*\*This is not an absolute indication unless previous Cesarean was a classical uterine incision (see below,) but labor in a patient with a prior Cesarean carries a risk of uterine rupture which may be unacceptable in many settings.*

Perimortem or resuscitative Cesarean is a potentially life-saving surgery in the event of cardiac arrest in a pregnant individual. It is indicated in pregnancies that are 20 weeks or more advanced (uterus at the umbilicus) since the gravid uterus can impede blood flow at this gestational age. Previously ineffective resuscitative efforts may be effective once the uterus is no longer gravid. A perimortem Cesarean needs to be performed quickly after 4 minutes of cardiac arrest with unsuccessful resuscitation. The Cesarean should be performed simultaneously while cardiopulmonary resuscitation is being done.

The following describes the steps for a standard Cesarean birth and what to do when more complicated scenarios present themselves.

## Steps:

1. Administer prophylactic antibiotics. Ideal preoperative antibiotics are a first-generation cephalosporin (e.g. cefazolin 1g IV for patients <80 kg, 2-3g IV for patients > 80 kg) administered in the hour prior to surgery. If membranes have been ruptured, azithromycin 500mg IV should be added if available to reduce the risk of perioperative infection.
2. Place an indwelling catheter. Drain the bladder with an in and out catheter prior to surgery if an indwelling catheter is not available.
3. Consider thromboembolism prophylaxis. If available, pneumatic compression devices should be placed.
4. Prepare and drape the abdomen and pelvis. Abdomen should be prepared with surgical solution typically used in the facility. For patients in labor with ruptured membranes, performing a vaginal preparation as well helps to reduce the risk of postpartum endometritis and should be performed when possible. This should ideally be performed with 4% chlorhexidine gluconate vaginal scrub but povidone-iodine is a slightly less effective acceptable alternative.
5. Choose a skin incision. Typically, a transverse skin incision, either a Pfannenstiel or Joel-Cohen type incision is sufficient for a Cesarean birth. A vertical incision can be performed if the operative physician feels more comfortable with this approach or in instances where a transverse incision will not provide enough exposure (e.g. suspicion for uterine rupture, distorted anatomy from fibroids, maternal obesity.)
6. Ensure that the skin incision is adequate to deliver the fetus. An incision length of 15 cm, or the length of an Allis clamp, will be adequate in most circumstances.
7. Once entry into the abdomen has been achieved, place a bladder blade in to expose the uterus and assess for the need for a bladder flap. Routine creation of a bladder flap has not been shown to



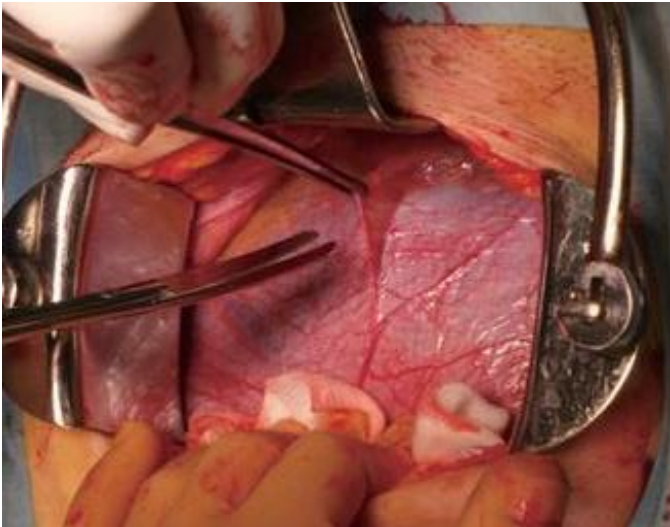
# Cesarean Birth

Lindsey E. Zamora, Annelise Long

provide any benefit to patients, but for certain patients, it may decrease risk of bladder injury. Patients who may benefit are the following:

- Difficult fetal extraction anticipated, with chance for extension of hysterotomy
- Bladder is attached above the lower uterine segment from previous Cesarean or anatomic differences

To create a bladder flap, identify, then elevate the vesicouterine peritoneum, then enter sharply with Metzenbaum scissors. Then extend the incision laterally and digitally open the space between the uterus and the bladder with blunt dissection. Reinsert the retractor's bladder blade between the bladder and the uterus.



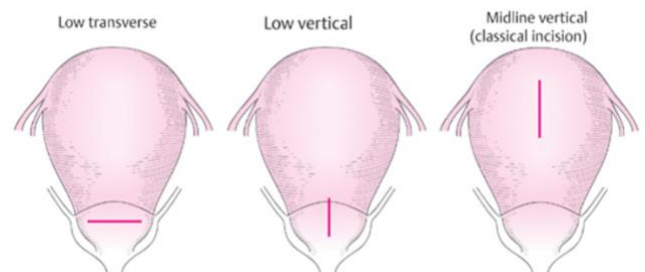
*Bladder flap peritoneal incision: the peritoneum is lifted off of the uterus with a forceps, and the plane between the peritoneum and the uterus is then developed caudally, pushing the bladder away from the uterus. Source: Hiramatsu, Yuji doi: [10.1055/s-0040-1708060](https://doi.org/10.1055/s-0040-1708060)*

8. Decide on what type of hysterotomy will be made. The surgeon should know the fetal lie prior to making this decision. In general, a transverse hysterotomy in the lower uterine segment is the correct uterine incision. Transverse hysterotomy results in less blood loss and decreases risk of uterine rupture in future pregnancies when compared to vertical hysterotomy. The disadvantage of a transverse incision is that it cannot be extended if there is

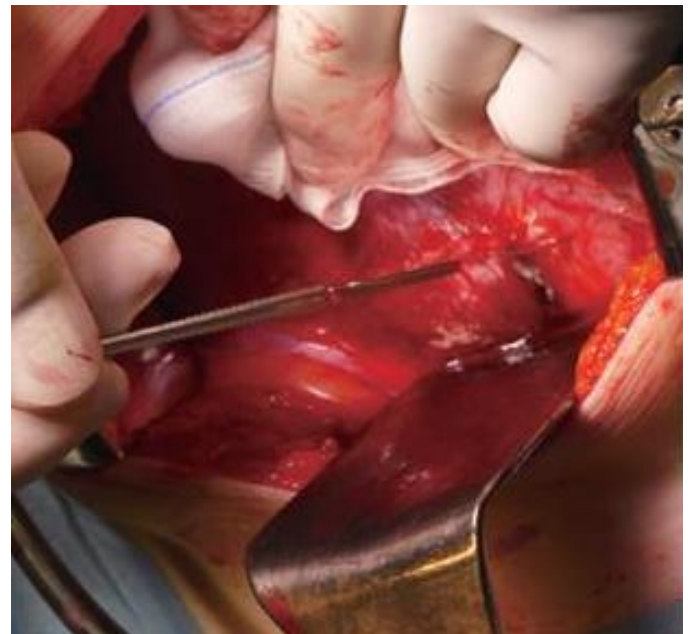
not enough room without damaging major blood vessels. Vertical hysterotomy (low vertical or classical incisions) can be considered in the following circumstances:

- Fetal lie is transverse, with back facing downwards
- Dense bladder adhesions
- Lower uterine segment pathology (e.g. placenta previa, large fibroids)
- Delivery of a very large fetus with risk of extension of a transverse hysterotomy into the uterine vessels laterally

Once the hysterotomy is made, extend it bluntly. If the uterus is too thick to extend bluntly, extend using bandage scissors, taking care to avoid the uterine vessels laterally.



*Hysterotomy options: low transverse, low vertical, and classical incisions. Source: Kan, Amano doi: [10.1055/s-0039-3402072](https://doi.org/10.1055/s-0039-3402072)*



# Cesarean Birth

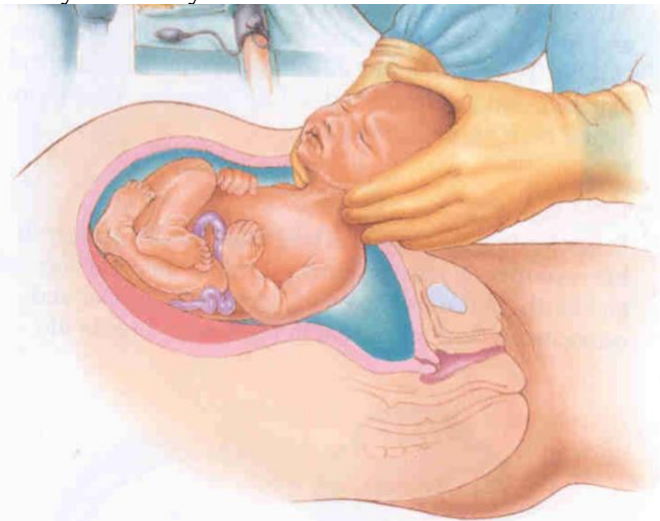Lindsey E. Zamora, Annelise Long

*Hysterotomy performed via low transverse incision. Source: Hiramatsu, Yuji doi: [10.1055/s-0040-1708060](https://doi.org/10.1055/s-0040-1708060)*

9. Delivery: After hysterotomy, perform the delivery. If the fetus is in a standard cephalic or breech presentation, deliver with standard delivery maneuvers:

## Cephalic:

- Perform amniotomy
- The surgeon should use the hand on the caudal side of the patient to gently reach inside the uterus and cup the fetal vertex.
- The vertex should then be elevated vertically from the hysterotomy. Standing on a stool can help to elevate the fetal head vertically (elevating obliquely can lead to extensions in the hysterotomy and excess blood loss.)
- After the fetal head has been delivered, deliver the remainder of the body through the hysterotomy.



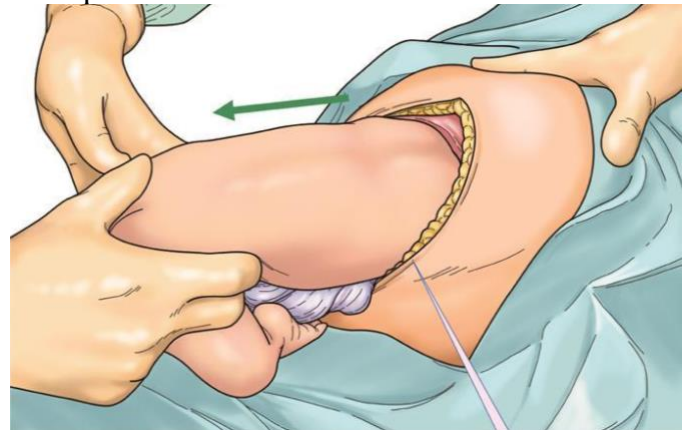
*The fetal head should be lifted from the hysterotomy vertically with the hand on the caudal side of the patient. Source: <http://www.csh.org.tw/dr.tcj/educartion/teaching/CS/index.htm>*

## Breech:

- If amniotomy has not been performed, the surgeon should attempt to feel through the amniotic sac to identify if the presenting fetal part is the breech or fetal feet. If the feet are palpable, grasp the feet through the sac prior to rupturing the membranes. Grasping the feet prior to

membrane rupture allows for an easier delivery. If the membranes are already ruptured and the feet are easily palpable, pull the feet and the remainder of the fetal legs from the hysterotomy using gentle traction. Often wrapping the feet in a moist laparotomy sponge can give additional traction.

- If fetal feet are not easily palpable, the surgeon can elevate the fetal breech from the hysterotomy vertically similar to the delivery of the fetal head in a cephalic delivery. If the breech is elevated, the legs and feet will follow and spontaneously deliver. Gentle traction can then be used on the fetal feet to deliver to the level of the fetal sacrum.
- Once the fetal body has been delivered to the level of the sacrum, rotate the fetal body so that the sacrum is anterior. Using the laparotomy sponge and gentle traction, grasp the fetus with thumbs on the sacrum and index fingers on the hips.



*The fetus is extracted horizontally with thumbs on the sacrum and index fingers on the hips. Source: Takeda, Jun doi: [10.1055/s-0040-1702985](https://doi.org/10.1055/s-0040-1702985)*

- Turn the infant 90 degrees to bring the anterior shoulder into view, then sweep the arm across the fetal chest at the elbow to deliver the arm.

OPEN MANUAL OF SURGERY IN RESOURCE-LIMITED SETTINGS

[www.vumc.org/global-surgical-atlas](http://www.vumc.org/global-surgical-atlas)

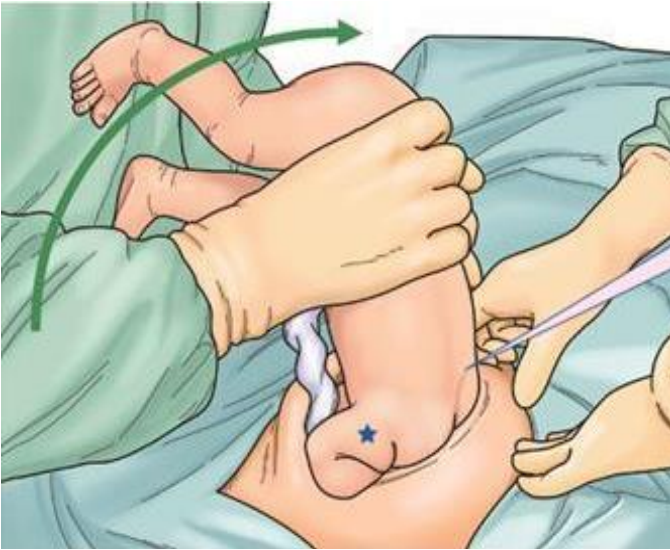
This work is licensed under a [Creative Commons Attribution-ShareAlike 3.0 Unported License](https://creativecommons.org/licenses/by-sa/3.0/)





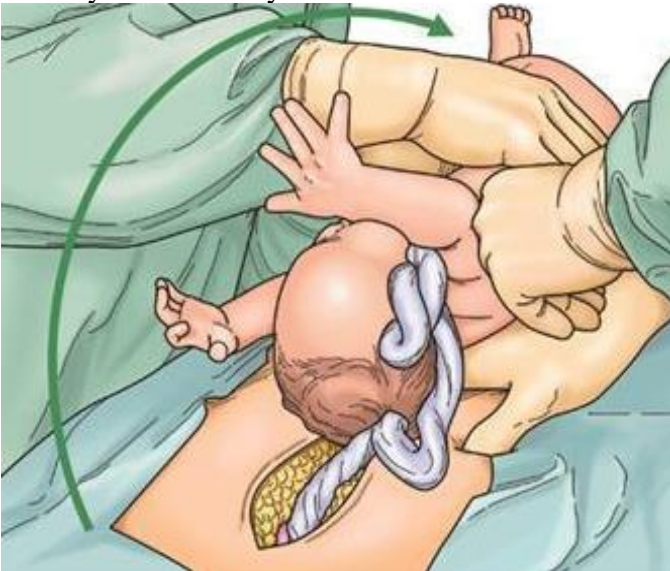## Cesarean Birth

Lindsey E. Zamora, Annelise Long



The fetus is rotated 90 degrees to deliver the first shoulder and arm. Source: Takeda, Jun doi: [10.1055/s-0040-1702985](https://doi.org/10.1055/s-0040-1702985)

- Then rotate the fetus 180 degrees to visualize the opposite shoulder and deliver the opposite arm.
- Once both arms have been delivered, an assistant should gently hold the fetal body while the surgeon delivers the fetal head. The fetal head may deliver easily with minimal traction.



The assistant (left side of picture) holds the fetal body while the surgeon delivers the fetal head. Source: Takeda, Jun doi: [10.1055/s-0040-1702985](https://doi.org/10.1055/s-0040-1702985)

- If the head does not deliver spontaneously, the surgeon should use the index and middle fingers of one hand to gently press the fetal occiput and at the same time, use the same fingers on the

opposite hand to help to flex the maxilla. These movements help to maintain the fetal head in a flexed position for delivery.

(Other fetal presentations are described at the end of this section.)

10. Clamp and cut the umbilical cord. If no neonatal resuscitation is needed and maternal bleeding is not excessive, the cord should be clamped after 30-60 seconds. This delay in umbilical cord clamping helps to minimize neonatal anemia. If there is active maternal hemorrhage, delayed cord clamping should be forgone and the cord should be clamped and cut immediately so that attention can be turned to hemostasis.
11. Administer uterotonics and extract the placenta. If available, Oxytocin should be administered after delivery prior to delivery of the placenta or as soon as possible. Oxytocin 10mg intramuscularly (IM) or slowly intravenously (IV) 5-10 IU as a single dose should be administered. Pitocin can also be infused IV, 10-40 units added to a 500 to 1000mL solution at a rate to sustain uterine contraction. The placenta should be delivered with gentle traction on the clamp on the umbilical cord and fundal uterine massage. Manual removal of the placenta should be avoided unless rapid removal for bleeding control is necessary, since manual removal can increase risk of infection and increased blood loss.
12. Close the hysterotomy. The surgeon can choose to exteriorize the uterus to close the hysterotomy or to repair the uterus in situ. Exteriorizing the uterus gives better exposure to suture it but can lead to more nausea and vomiting. The uterus should be closed in one or two layers, with delayed absorbable synthetic suture. The uterus should be closed with delayed absorbable synthetic suture. The first layer should be placed with a running unlocked suture. Locking can be considered if there is significant bleeding for additional bleeding control. A second imbricating layer of suture can be used in instances where the patient may attempt a vaginal

**OPEN MANUAL OF SURGERY IN RESOURCE-LIMITED SETTINGS**

[www.vumc.org/global-surgical-atlas](http://www.vumc.org/global-surgical-atlas)

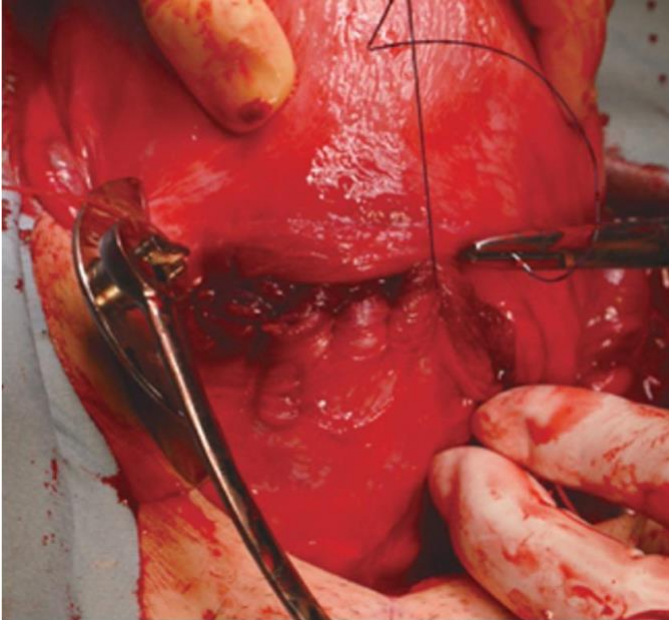
This work is licensed under a [Creative Commons Attribution-ShareAlike 3.0 Unported License](https://creativecommons.org/licenses/by-sa/3.0/)



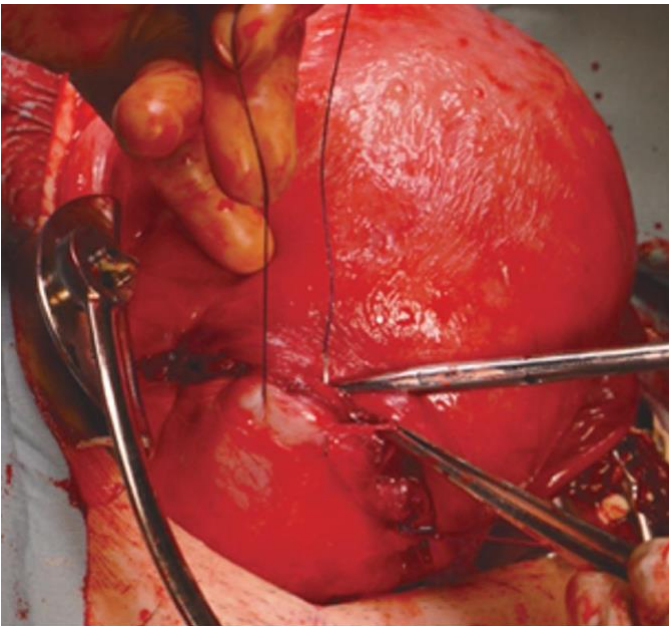
## Cesarean Birth

Lindsey E. Zamora, Annelise Long

delivery in the future to help strengthen the uterine closure. If placed, the second layer should imbricate the exposed myometrial layers and should be a running unlocked stitch. If exteriorized, the uterus can be returned to the abdomen



Closing the first layer of the hysteroscopy. Source: Hiramatsu, Yuji doi: [10.1055/s-0040-1708060](https://doi.org/10.1055/s-0040-1708060)



Closing the second layer of the hysteroscopy. Hiramatsu, Yuji doi: [10.1055/s-0040-1708060](https://doi.org/10.1055/s-0040-1708060)

13. The abdominal wall can then be closed in a standard manner.

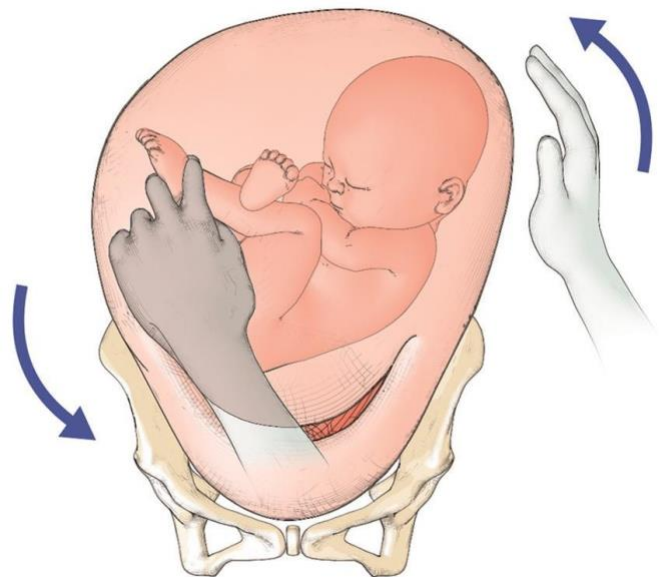
### More Complex Situations

#### Delivery of a Floating Fetal Head:

In this situation, the fetal head is moving freely above the pelvic inlet. This delivery can be difficult because although the head can be accessed, it can be difficult to grasp. The fetus can be delivered in one of three ways in this circumstance:

If membranes are unruptured, the surgeon should cup their hand through the uterus around the fetal head while membranes are ruptured via hysteroscopy, to keep the fetus in cephalic position. Once the amniotic fluid is allowed to fully release, often the uterus will contract around the fetus and delivery can be achieved in a standard fashion.

Internal podalic version can be performed. The surgeon reaches into the uterus and grasps one or both feet while simultaneously using the other hand to guide the fetal head to the uterine fundus. The fetus is then delivered as a footling breech (as described further below) using standard maneuvers. This technique can also be used for a second twin delivery when the second twin is unengaged in the pelvis.



Internal podalic version consists of reaching through the hysteroscopy to grasp one or both feet while using the other hand to guide the head towards the fundus. Source: Takeda, Jun doi: [10.1055/s-0040-1702985](https://doi.org/10.1055/s-0040-1702985)



## Cesarean Birth

Lindsey E. Zamora, Annelise Long

Extraction with vacuum or forceps during Cesarean (see [Operative Vaginal Delivery](#).) After delivery of the fetal head, remove the vacuum or forceps and deliver the remainder of the fetus in a standard fashion.

### Delivery of a Severely Impacted Fetus:

These can be some of the most challenging Cesarean births. When the fetal head is deeply impacted in the maternal pelvis, it creates a suction-like effect. It most often occurs after prolonged second stage of labor or failed operative vaginal delivery. If extreme force is used to try to deliver the baby in these circumstances, this can lead to maternal trauma (damage to the uterus, cervix or vagina) or severe injury to the fetus (skull injury, intracranial hemorrhage, or death.)

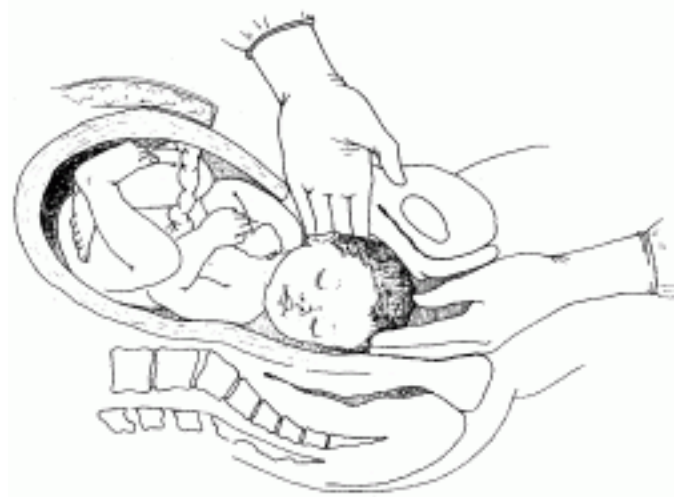If an impacted fetal head is suspected prior to the Cesarean, the patient should be placed in a frog legged position or in stirrups for her Cesarean. This allows a second surgeon or experienced assistant to assist in applying pressure from below on the fetal head to elevate the head if needed. If an assistant is not available, the surgeon performing the Cesarean can attempt to disengage the fetal head manually either prior to starting the Cesarean or after an initial delivery attempt. If a second person is disengaging the fetal head from below, this should not be done until the surgery has started and when help is deemed as needed by the operating surgeon.

The assistant disengaging the fetal head from below should take care to press on the fetal head ideally using their entire palm to distribute pressure uniformly to the fetal head to minimize risk of fetal head injury.

In cases of Cesarean birth with an impacted fetal head, care needs to be taken to make the hysterotomy sufficiently high. If made too low, the “hysterotomy” may actually be made in the vagina and will be very difficult to repair, increasing risk for injury to major vessels and the bladder. After the hysterotomy has been made, the initial delivery strategy should be for the delivering surgeon to attempt to place their hand around the fetal head and deliver it as described above. Often, it is possible to

place a hand slightly laterally rather than directly behind the pubic symphysis. If delivery with this approach is not achieved, one of the two following strategies need to be chosen:

**Push method:** An assistant uses a gloved hand to apply even pressure on the fetal head vaginally to disengage the fetal head while the operating surgeon elevates the fetal head out of the pelvis for delivery once it has been disengaged.



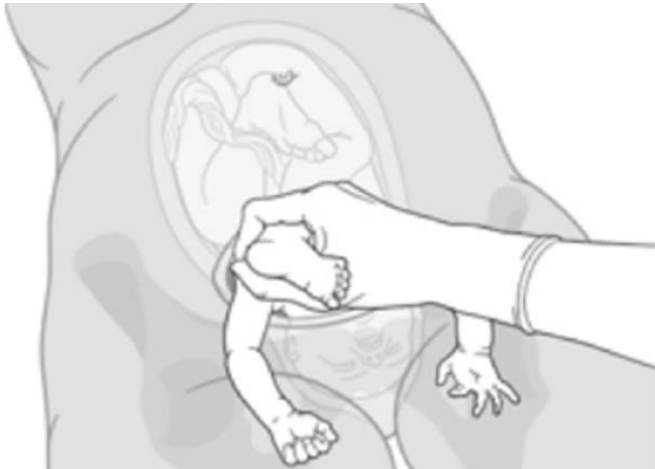*An assistant provides pressure from below to manually disengage an impacted fetal head. Note that in this illustration, the assistant is using fingers. As described in the text, it is better to use the palm of the hand if possible to provide uniform pressure to the head and avoid injury. Source:*

[https://hetv.org/resources/reproductive-health/impac/Procedures/Caesarean\\_section\\_P43\\_P52.html](https://hetv.org/resources/reproductive-health/impac/Procedures/Caesarean_section_P43_P52.html)

**Pull method:** Surgeons attempting this delivery technique should ideally have practiced it in non-emergency situations. Fetal head is disengaged from below as previously described. After the fetal head has been disengaged, the surgeon reaches into the uterine fundus to grasp the fetal feet which are then pulled to perform a footling breech extraction.

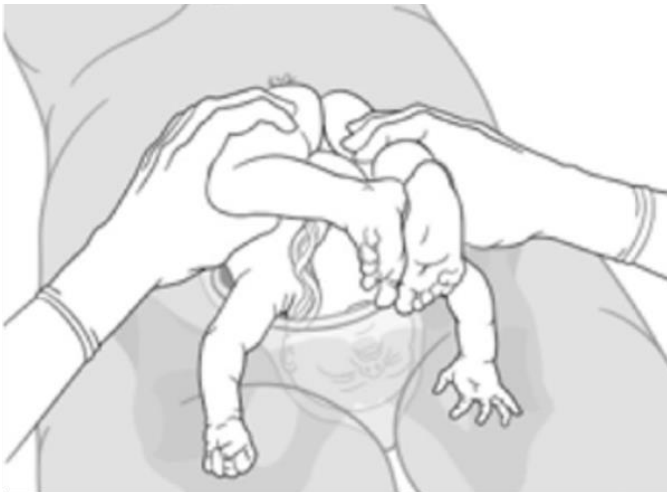## Cesarean Birth

Lindsey E. Zamora, Annelise Long



*First step of a footling breech extraction: the surgeon reaches into the uterus to grasp one or both fetal feet and pull them downwards. In this illustration, the arms have been delivered, making overall delivery of the head and shoulders easier. Source: Lenz F et al.*

<https://doi.org/10.1186/s12884-019-2253-3>



*Second step of a footling breech extraction: with the feet removed, the legs and hips follow. The head will be removed last. Source: Lenz F et al.*

<https://doi.org/10.1186/s12884-019-2253-3>

### Transverse Lie:

If the fetus is transverse with the back facing upwards, delivery can be achieved with a transverse hysterotomy. The surgeon should try to keep the fetal membranes intact and grasp the fetal feet through the membranes to then deliver in a footling breech manner after membranes are ruptured. If the fetus is transverse with the back down, there are no limbs to grasp with a transverse hysterotomy, thus a vertical hysterotomy needs to be made. Once the

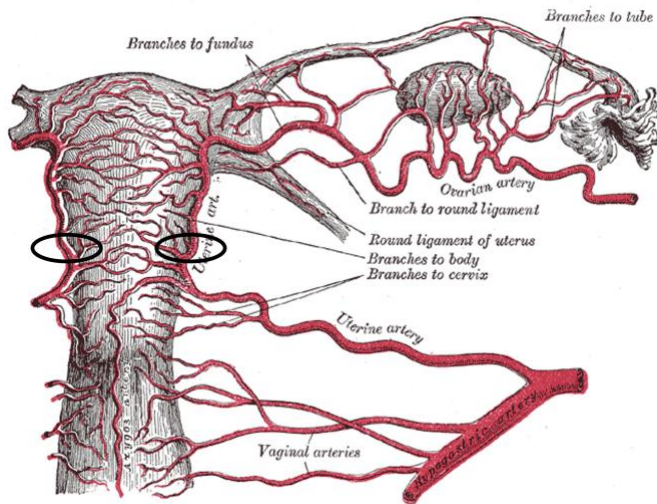
vertical hysterotomy is made, fetal feet can be grasped and the fetus can be delivered in a footling breech manner.

### **Pitfalls:**

- If a low vertical or classical hysterotomy is performed, the patient must be counseled that she should not labor in future pregnancies. This would put her at significant risk for uterine rupture in a subsequent pregnancy. In general, a repeat Cesarean birth planned for 37 weeks is recommended in future pregnancies.
- If bleeding is noted from the placental site after delivery of the placenta, several techniques can be used to manage it:
  - Deep compression sutures in a figure of eight or box pattern
  - Use of a compression balloon (Bakri or several filled foley catheters exiting from the vagina)
  - Intrauterine packing: Tie together sterile gauzes and pack the uterus with the tail of the packing exiting from the vagina. Take care to ensure the packing has not been sewn into the hysterotomy upon uterine closure.
- If the hysterotomy extends into the uterine blood vessels laterally, ligation of the uterine vessels may be necessary. A large curved needle with an absorbable suture is used for this. Ureters and bladder are first identified, then suture is passed through the lateral lower uterine segment as close to the cervix as possible, then back through the broad ligament just lateral to the uterine vessels. This is done both above and below the hysterotomy to control bleeding from the extension of the hysterotomy.

# Cesarean Birth

Lindsey E. Zamora, Annelise Long



*Uterine artery ligation as described in the text: After identification of the ureters, with absorbable suture on a large curved needle, suture is passed through the lower lateral uterus muscle and broad ligament as close to the cervix as possible, in the area shown by the Black circles.*

- Thromboembolism is one of the highest causes of maternal mortality, and a large proportion occur after Cesarean birth. In many settings with limited resources, pneumatic compression devices may not be readily available. In this case, graduated compression socks are the next best alternative. All patients should be encouraged to ambulate as early as possible after surgery to reduce their risk as well. In patients who are at high risk for thromboembolism, it is reasonable to consider both mechanical and pharmacologic prophylaxis once cleared from an anesthesia standpoint.

Lindsey E. Zamora, MD MPH  
Vanderbilt University Medical Center  
USA

Annelise Long, MSPH  
University of Washington  
USA

March 2023